

Role of 1p/19q Codeletion in Diffuse Low-grade Glioma Tumour Prognosis

PIETRO FAMILIARI^{1#}, PIERFRANCESCO LAPOLLA^{2,3#}, VERONICA PICOTTI^{1,4}, MAURO PALMIERI¹, ALESSANDRO PESCE^{5,6}, GIULIA CAROSI¹, MICHELA RELUCENTI³, STEFANIA NOTTOLA³, FRANCESCA GIANNO⁶, SIMONE MINASI⁶, MANILA ANTONELLI⁶, ALESSANDRO FRATI^{1,7}, ANTONIO SANTORO¹, GIANCARLO D'ANDREA⁸, PLACIDO BRUZZANITI^{1,8†} and BIAGIA LA PIRA^{8†}

¹Department of Human Neurosciences, Division of Neurosurgery, Policlinico Umberto I University Hospital, Sapienza University of Rome, Rome, Italy;

²Nuffield Department of Surgical Sciences, University of Oxford, Oxford, U.K.;

³Department of Anatomy, Histology, Forensic Medicine and Orthopedics, Sapienza University of Rome, Rome, Italy;

⁴Division of Neurosurgery, Policlinico Tor Vergata, University Tor Vergata of Rome, Rome, Italy;

⁵Neurosurgery Division, Santa Maria Goretti Hospital, Latina, Italy;

⁶Department of Radiological, Oncological and Anatomico-Pathological Sciences, Sapienza University of Rome, Rome, Italy;

⁷Department of Neurosurgery, IRCCS Neuromed, Pozzilli, Italy;

⁸Fabrizio Spaziani Hospital, Frosinone, Italy

Abstract. *Background/Aim:* In the latest 2021 WHO classification of central nervous system tumours (CNS), gliomas that present isocitrate dehydrogenase (IDH) mutations are defined as diffuse low-grade gliomas (DLGGs). IDH mutations are commonly observed in this tumour type. The Extent of Resection (EOR) positively influence survival; however, it is still debated whether the predictive value of EOR is independent of the 1p/19q co-deletion. We carried out a retrospective analysis on patients operated on for DLGG at the Sant'Andrea University Hospital Sapienza University of Rome, correlating the outcome with the presence of 1p/19q co-deletion and EOR. *Patients and Methods:* The study examined 66 patients with DLGG who had undergone surgery for tumour resection between 2008 and 2018. Patients with DLGG were divided into two groups; diffuse astrocytoma (DA) in which 1p/19q codeletion is absent and

oligodendroglioma (OG) in which 1p/19q codeletion is present. According to EOR, both groups were divided into two subgroups: subtotal resection (STR) and gross total resection (GTR). Three end-point variables were considered: overall survival (OS), progression-free survival (PFS) and time to malignant transformation (TMT). *Results:* In the DA group, the GTR subgroup had an average OS of 81.6 months, an average PFS of 45.9 months and an average TMT of 63.6 months. After surgery, these patients had an average Karnofsky Performance Score (KPS) of 83.4. The STR subgroup had an average OS of 60.4 months, PFS was 38.7 months, and TMT was 46.4 months, post-operative KPS was 83.4. In contrast, in the OG group, the GTR averagely had 101.7 months of OS, 64.9 months of PFS, 80.3 months of TMT and an average post-operative KPS of 84.2, and the STR subgroup had an average of OS of 73.3 months, PFS of 48.2 months, TMT of 57.3 and an average postoperative KPS of 96.2. *Conclusion:* In patients affected by DLGGs, 1p/19q codeletion is significantly associated with prolonged survival and longer time-to-malignant transformation (TMT) compared to the absence of 1p/19q codeletion. Also, the extent of surgical resection (EOR) in DLGG patients has been confirmed as one of the main prognostic factors. However, its predictive value is substantially influenced by the presence of the 1p/19q codeletion.

#,†These Authors contributed equally to this study.

Correspondence to: Pierfrancesco Lapolla, Nuffield Department of Surgical Sciences, University of Oxford, John Radcliffe Oxford University Hospital, Headington, Oxford, OX3 9DU, U.K. Tel: +44 7883083865, e-mail: pierfrancesco.lapolla@nds.ox.ac.uk

Key Words: Diffuse low-grade glioma, extent of resection, overall survival, molecular markers, intraoperative magnetic resonance imaging.



This article is an open access article distributed under the terms and conditions of the Creative Commons Attribution (CC BY-NC-ND) 4.0 international license (<https://creativecommons.org/licenses/by-nc-nd/4.0>).

The incidence of gliomas in the central nervous system (CNS) is estimated at 7.3 per 100,000 people per year, and diffuse low-grade gliomas (DLGG) represents 12.8% of them (1). Surgery is the treatment of choice for these types of tumours; it results in being safe and effective (2, 3);

considering the rarity of such conditions, its role in treating DLGG is fundamental but still lacks efficacy and DLGG management remains controversial (4). Extensive resection improves survival and delays tumour progression. Also, supramarginal resections can delay the time-to-malignant transformation (TMT) and increase overall survival (OS) (5). More than 80% of DLGG cases are associated with isocitrate dehydrogenase (IDH) 1 or IDH2 missense mutations (6). DLGG oligodendroglioma also shows the presence of the codeletion of chromosome arms 1p and 19q (7).

The World Health Organization (WHO) 2021 classification of CNS tumours is genotype-centred; for diagnosis and treatment selection the genetic profile is taken more into consideration than histological features in cases where the histology and molecular features are not comparable. It defines diffuse astrocytoma as a DLG IDH-mutant, and oligodendroglioma as a DLG IDH mutant with the 1p/19q codeletion (8). Three DLGGs have been identified: astrocytoma IDH-mutant, oligodendroglioma IDH-mutant and 1p/19q- co-deleted, and glioblastoma IDH-wildtype.

The “not otherwise specified (NOS) DLGG” category will likely increase in this classification. This designation is used for genotyped tumours that do not fall into the new, more strictly defined categories. For this reason, another essential Classification has been proposed, which includes IDH mutations, 1p/19q codeletions and telomerase reverse transcriptase promoter (TERTp) mutations. Patients affected by DLGG triple-positive defined by 1p/19q codeletion, TERT mutation, and IDH mutation have the most favourable clinical outcomes (9). Other mutations, such as TP53 mutations, are associated with significantly poorer survival among patients with DLGGs and disease progression in the secondary glioblastoma (GBM) (10).

This study aimed to clarify the role of 1p/19q-codeletion as a clinical outcome factor in DLGG patients, as clinical outcome. We performed a long-term follow-up of these patients and were able to evaluate whether this mutation impacts survival regardless of the degree of the surgical resection of the tumour.

Patients and Methods

Study cohort and inclusion criteria. The inclusion criteria for this study were satisfied for 66 patients, including adult patients (≥ 18 years) who underwent DLGG surgery from December 2008 to December 2018 at the Sant’Andrea Hospital University of Rome, with a confirmed diagnosis of DLGG IDH mutated. The presence of 1p/19q codeletion was confirmed, and patients without definitive molecular profiling were excluded. Selected patients received regular clinical and neuroradiological follow-up.

Patients were divided in two groups based on the presence of 1p/19q codeletion: 37 patients presented to DLGG with IDH-mutated without codeletion 1p/19q (DA group) and 29 patients presented to DLGG with IDH-mutated with codeletion 1p/19q (OG group). The DA Group included 37 patients, and the observed histological and molecular characteristics are summarized in Figure 1.

A total of 29 patients showed a DLGG IDH mutation with 1p/19q codeletion and were included in the OG Group. In Figure 2, their histological and molecular features are shown. Both groups underwent surgery using intraoperative magnetic resonance imaging (Io-MRI) and were further divided into subgroups based on extent of resection (EOR), subtotal resection (STR), and gross total resection (GTR).

TP53 mutation and Epidermal growth factor receptor (EGFR) amplification/EGFR variant III mutation and their predictive value was investigated in both groups. The data analysis methodology is consistent with the one used by Salvati *et al.* (11).

Molecular analysis. Formalin-fixed paraffin-embedded (FFPE) 3-mm-thick sections from tissue samples were cut and stained with haematoxylin and eosin (HE) with a pre-step of deparaffination with xylol. An immunohistochemical panel including GFAP, ATRX, P53, IDH1 R132H was used. Immunohistochemistry (IHC) was performed by Leica Bond RXm™ automated staining processor (Leica Biosystems, Buffalo Grove, IL, USA). Tissue sections were cut at 5 μ m, dried at 70°C for 30 min and then dewaxed. Antigen retrieval was performed in the Bond Rx system with Epitope Retrieval Solution 1 (pH 6) for 30 min. Sections were incubated for 30 minutes with GFAP (Novocastra – Leica Biosystems clone GA5, mouse monoclonal, 1:400 dilution), ATRX (NBP1-83077, rabbit polyclonal, 1:1,000 dilution; Novus Biologicals, Centennial, CO, USA), p53 (NCL-L-p53-DO7, mouse polyclonal, 0.875 μ g/ml; Leica Novocastra), IDH1 R132H (DIA H09, mouse monoclonal antibody, Dianova, Hamburg, Germany).

The presence or absence of 1p deletion was detected by the fluorescence in situ hybridisation (FISH) technique, using the Vysis LSI 1p36 orange/1q25 green Dual-Color Probe kit (Abbott, Abbott Park, IL, USA). Moreover, the presence or absence of 19q deletion was found by FISH using the Vysis LSI 19q13 orange/19p13 green Dual-Color Probe kit (Abbott). When 30% of neoplastic nuclei exhibited 10/2G signals for both 1p36/1q25 and 19q13/19p13, they are considered positive for 1p/19q co-deletion.

Neuroradiology protocol. The preoperative study included a neurological examination with evaluation of the KPS score and a radiological study performed with MRI 1.5T after administering gadolinium and fluid-attenuated inversion recovery (FLAIR) with the integration of diffusion-weighted imaging (DWI), Perfusion-weighted imaging (PWI) sequences and spectroscopy. A functional MRI was performed in patients with a lesion in the eloquent area, the brain area controlling the speech. All patients performed one or more Io-MRI with gadolinium and FLAIR after removing the tumour to verify that they had reached the target. Pre and postoperative tumour volumes were assessed in a semiautomatic fashion using the Smart Brush tool in Brainlab Elements (version 2.1.0.15) on the T2w-FLAIR sequence for volumetric multiplanar reconstruction (MPR) whenever possible. The EOR was determined by comparing early contrast-enhanced MRI images (with T2w-FLAIR sequence) acquired within 24hrs after surgical treatment with the preoperative ones and calculated with the ABC/2 method. The residual volume (RV) which is recorded in cm^3 is defined as the post resection residual tumour volume. The radiological criteria used to define EOR and RV are hyperintense regions on T2w-FLAIR MRI axial images, and therefore can only be determined by comparing preoperative and postoperative tumour volumes on MRI (12). We define a GTR as the absence of residual disease in axial

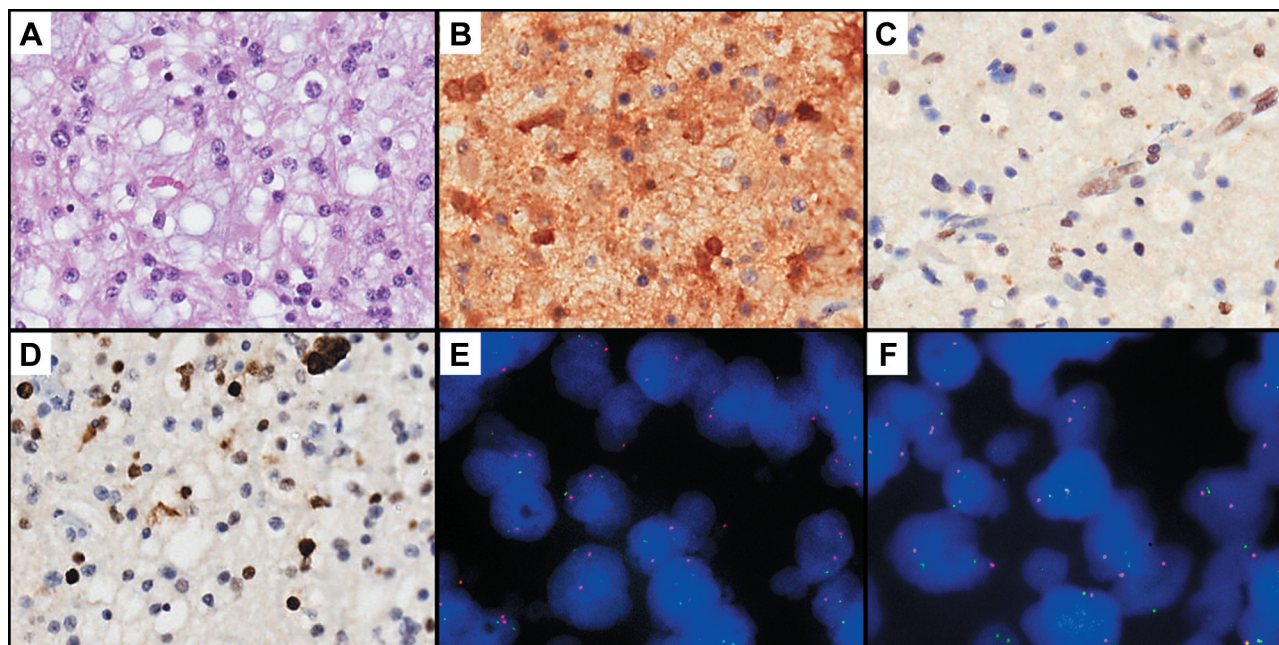


Figure 1. Results of the diffuse astrocytoma (DA) group are illustrated. (A) An infiltrating astrocytic glioma of low cellularity with mild nuclear atypia, fibrillar background with mild oedema haematoxylin and eosin (H&E, 20 \times). (B) Immunohistochemistry for isocitrate dehydrogenase (IDH1 R132H) demonstrating strong cytoplasmic reactivity in neoplastic cells (20 \times). (C) Immunohistochemistry for ATRX Chromatin Remodeler revealing loss of nuclear staining in neoplastic cells (20 \times). (D) Immunohistochemistry for p53, showing strong nuclear staining in neoplastic cells. (E) Absence of 1p deletion in astrocytic glioma detected by fluorescence in situ hybridization (FISH) using the Vysis LSI 1p36 orange/1q25 green Dual-Color Probe kit (100 \times). (F) Absence of 19q deletion detected by FISH using the Vysis LSI 19q13 orange/19p13 green Dual-Color Probe kit (100 \times). Sample is considered negative for 1p/19q co-deletion.

T2w-FLAIR MRI images. At the same time, we consider STR to be an EOR >90%. The study did not include partial resections (resection <90%) and biopsies.

Surgical management. The surgical strategy aimed to maximise the extension of the resection of the T2w-FLAIR MRI signal, preserving the eloquent areas to avoid neurological deficits. Surgical procedures of 93.8% of patients suffering from DLLG involving the eloquent area were performed under cortical and subcortical white matter intraoperative electrical stimulation (IES), intraoperative neuromonitoring (IoN), cortical mapping through direct stimulation. A neuronavigational system (BrainLab, Vector Vision) was used in all cases. A Diffusion tensor imaging (DTI) fibre tracking was carried out to investigate the anatomical relationship between the lesions and the cortico-spinal tract (CST) and arcuate fascicles (AF). Patients with lesions involving eloquent cortical and subcortical structures underwent awake surgery procedures (AS) with the "Asleep-Awake-Asleep" anaesthetic technique. AS was performed on 32 patients (48.4%) presenting lesions involving eloquent areas, and 11 patients had lesions in the somatosensory area and the dominant temporal lobe, premotor lobe, and insula lobe. Similarly, five patients affected by lesions involving non-dominant supplementary and primary motor areas and non-dominant insular lobes were treated in AS, in which cortical and subcortical IES enabled the detection of corticospinal lesions. Electrocardiography and electroencephalography were routinely added to the standard

monitoring setup throughout the procedure to monitor the occurrence of intraoperative seizures. Cortical brain mapping required a maximum of 4 mA of current intensity and subcortical brain mapping required 6 mA of stimulation (Figure 3). Language abilities were evaluated using standard stimuli, such as counting, picture naming, and reading tasks.

Neuro-oncology follow-up. OS was recorded in months and measured from the date of diagnosis to the date of death or date of the last contact, if alive. KPS was globally evaluated at the final follow-up endpoint and was subject to changes during therapeutic and rehabilitative treatment. Clinical and demographic information was obtained from the digital database of our institution, whereas OS data were obtained by telephone interview. A neuroimaging follow-up was performed on all patients. They received their first brain MRI within 24 h of surgery. In addition, they received a brain MRI 30 days after surgery for the radiation treatment planning, three months after surgery, and at the end of the adjuvant treatment. A multidisciplinary team that worked for integrated care discussed and evaluated all the cases. In case of malignant transformation of the tumour, adjuvant treatment and surgical indication followed the European Federation of Neurological Societies (EFNS) international guidelines for high-grade glioma (HGG) management.

MRI scans are used for diagnosis of malignant transformation. The criteria include the following: neo-angiogenesis and microvascular proliferation is a necessary step in the malignant transformation of

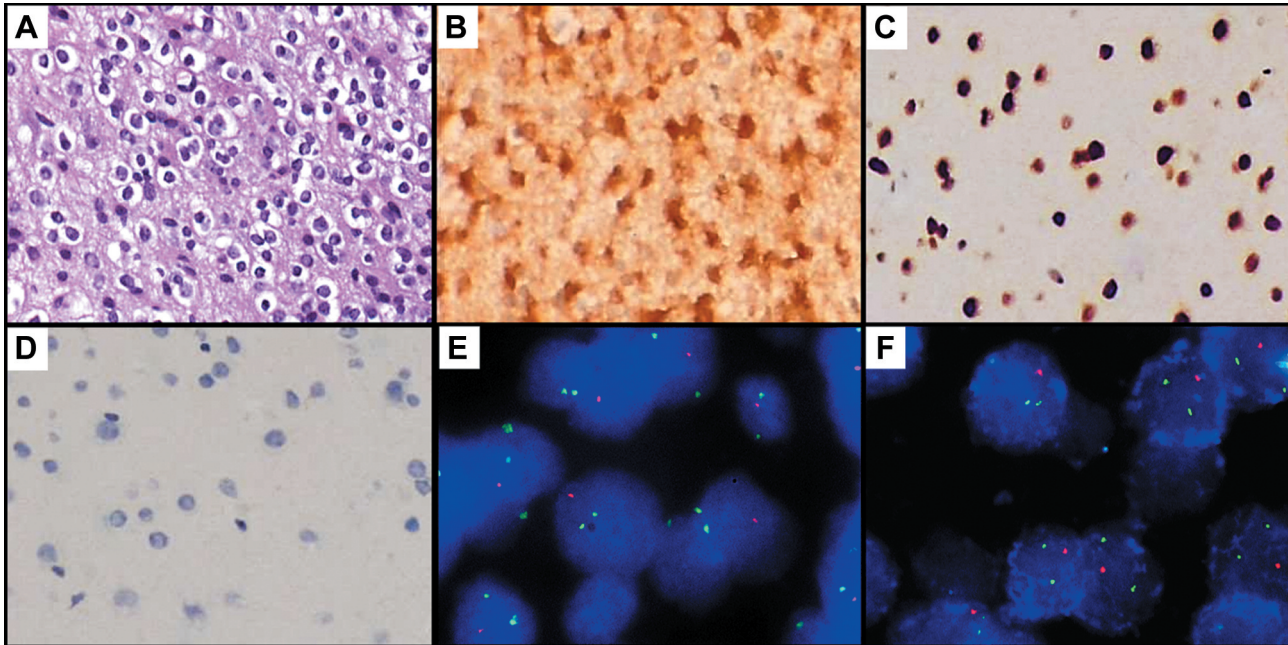


Figure 2. Results of the oligodendroglioma (OG) group are illustrated. (A) A glial tumour with uniformly round nuclei slightly larger than normal oligodendrocytes, with increase in chromatin density and perinuclear halo [haematoxylin and eosin (H&E 20×)]. (B) Immunohistochemistry for isocitrate dehydrogenase (IDH1 R132H) demonstrating strong cytoplasmic reactivity in neoplastic cells (20×). (C) Immunohistochemistry for ATRX Chromatin Remodeler revealing nuclear stain in neoplastic cells (20×). (D) Negative stain for p53 immunostain. (E) 1p deletion detected by fluorescence in situ hybridization (FISH) using the Vysis LSI 1p36 orange/1q25 green Dual-Color Probe kit (100×). (F) 19q deletion detected by FISH using the Vysis LSI 19q13 orange/19p13 green Dual-Color Probe kit (100×). Samples are considered positive for 1p/19q co-deletion.

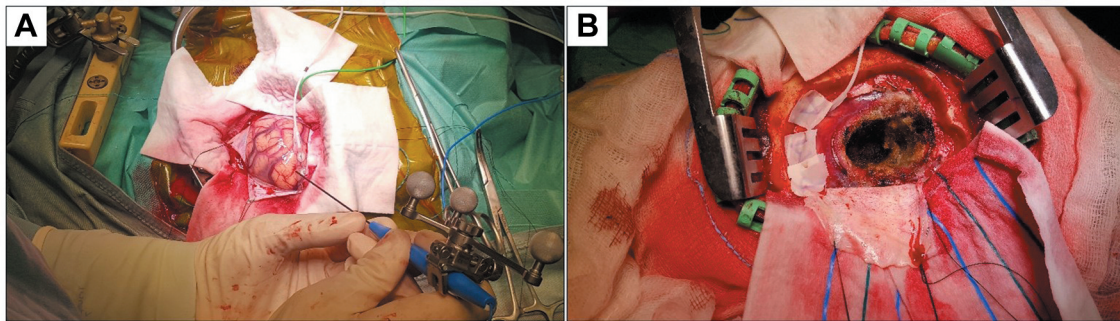


Figure 3. Intraoperative magnetic resonance imaging-guided diffuse low-grade gliomas (DLGGs) surgery with the asleep-awake-asleep anaesthetic technique and intraoperative functional mapping and monitoring: (A) Brain mapping with preoperative functional magnetic resonance imaging (fMRI) and intraoperative diffusion tensor imaging (DTI); (B) Safe gross total resection (GTR) of isocitrate dehydrogenase (IDH)-mutated diffuse astrocytoma in the eloquent area of the brain.

DLGG and may be detectable by perfusion imaging and rCBV >1.75 time to progression (12); to identify malignant transformation, a multivariate model has been used that incorporates choline (Cho)/creatine (Cr), cho/N-acetyl aspartate (NAA), and NAA/Cr ratios (13); the presence of contrast enhancement in previously non-enhancing tumours is thought to be indicative of advance grade progression.

Those patients who did not complete the follow-up at our institution were excluded from this study.

Adjuvant treatment. Adjuvant treatment consisted of low dose conformal radiotherapy immediately postoperatively (45-54 Gy/30 fractions) for up to six weeks. The chemotherapy was administered after progression to malignant transformation and treatment with TMZ (75 mg/m²/day) for up to six weeks followed by maintenance therapy with a standard TMZ (150-200 mg/m² five days, every 28, for 12 cycles) (14). Some patients with high risk, according to RTOG (age <40 years; subtotal resection), were

Table I. Demographic characteristics of the diffuse astrocytoma isocitrate dehydrogenase (IDH)-mutant group vs. the oligodendroglioma IDH-mutant and 1p/19q-codeleted group.

	DA Group Diffuse astrocytoma (DA) IDH-mutant and 1p/19q-codeletion absent	OG Group Oligodendroglioma (OG) IDH-mutant with 1p/19q-codeletion
Sex, N. (%)		
Male	21 (56.7)	18 (62.1)
Female	16 (43.2)	11 (37.9)
Age (SD)	55.2 (19.1)	49.2 (11.1)
Eloquent location, N. (%)		
Not	19 (51.3)	14 (48.2)
Motor	9 (24.3)	7 (24.1)
Language	5 (13.5)	3 (10.3)
Motor and language	4 (10.8)	5 (17.2)
Tumours side, N. (%)		
Frontal	16 (43.2)	11 (37.9)
Parietal	7 (18.9)	5 (17.2)
Temporal	11 (29.7)	7 (24.1)
Occipital	6 (16.2)	5 (17.2)
Insular	3 (8)	1 (3.4)
Laterality, N. (%)		
Left	19 (51.3)	17 (58.6)
Right	18 (48.6)	12 (41.3)
Surgery type, N. (%)		
GTR	18 (48.6)	13 (44.8)
STR	19 (51.3)	16 (55.1)
Awake	9 (24.3)	7 (24.1)
Neurophysiological monitoring	14 (37.8)	10 (34.4)
Intraoperative ultrasound	17 (45.9)	13 (44.8)
Radiation dose		
Total doses Gy (SD)	53.6 (3.2)	52.8 (7.3)
Fractions (SD)	28.9 (1.4)	28.5 (5.7)
Residual tumour, cm ³ (SD)	3.21 (1.9)	2.97 (3.07)
Median follow-up, Months (SD)	51.2 (12.8)	76.6 (14.7)
Recurrent surgery N. (%)		
0-2 Years	4 (10.8)	1 (3.4)
2-5 Years	14 (37.8)	7 (24.1)
>5 Years	19 (51.3)	21 (72.4)

SD: Standard deviation; STR: subtotal resection; GTR: gross total resection.

treated with Procarbazine, Lomustine and Vincristine combination chemotherapy (PCV).

Statistical analysis. Univariate analyses were performed within the single subgroups for sex, age, EOR, radiotherapy dose and fraction, IDH1 mutations status, EGFR amplification/EGFR variant-III mutation and TP53 mutation. The different subgroups were analysed regarding OS and PFS using Kaplan–Meier survival curves with log-rank tests. We conducted a contemporary parametric ANOVA multivariate regression analysis using the F-test. Independent variables used were sex, age, EOR (GTR, STR), radiotherapy dose, radiotherapy fraction, EGFR amplification/EGFR variant-III mutation and TP53 mutation. The dependent variables and endpoint variables were OS, PFS, and postoperative KPS. We performed a simultaneous regression model in which all the independent variables are simultaneously introduced into the regression equation. The analyses were conducted using IBM SPSS 25 statistics software.

Institutional Review Board statement. The study was conducted according to the guidelines of the Declaration of Helsinki and approved by the Institutional Review Board of the Sapienza University of Rome.

Informed consent statement. Informed consent was obtained from all subjects involved in the study, and written informed consent was obtained from the patients to publish this paper.

Results

We retrospectively analysed a cohort of 66 patients and assigned them to the DA and OG Groups, based on their 1p/19q codeletion status, characterised by histological and molecular features summarised in Figure 1 and Figure 2. The two groups were divided into two subgroups, STR and GTR. The main features of enrolled patients are presented in Table I.

DA Group. In the DA group, the average OS was 71.3 months, PFS was 42.8 months, and TMT was 55.2 months, with an average KPS score of 85.5 and cumulative 5-year survival of 88.7%. For this group, the average follow-up period was 51.2 months. In the GTR subgroup, Average OS and TMT were longer (81.6 months and 63.6 months) than in OS and TMT values observed in STR group. Patients presented an average postoperative survival rate of 85.5. In the STR subgroup, the median OS was 60.4 months, with a PFS and a TMT average of 38.7 and 46.4 months, respectively. Patients of this subgroup, the average postoperative KPS was 92.4. We found significant differences between the subgroups for the following dependent variables: OS ($p=0.012$), PFS ($p=0.003$), time to malignant transformation (TMT) ($p=0.001$) and postoperative KPS ($p=0.03$). These data confirm that the GTR has an advantage in terms of OS, PFS, and TMT, as also shown in Figure 4, and that the result is strictly related to RV.

A total of 27 patients in the DA group received an adjuvant radio with irradiation ranging between 40 and 60 Gy (52.1 ± 7.28 Gy) in averagely 27.2 ± 6.4 fractions. The average volume of the right ventricle in the DA group was 3.3 cm^3 ; such parameter was further codified as a three-step ordinal variable, thus obtaining three subgroups of patients: $\text{RV} < 2 \text{ cm}^3$, $3 \text{ cm}^3 > \text{RV} \geq 2 \text{ cm}^3$ and $\text{RV} \geq 3 \text{ cm}^3$. According to Figure 4, patients with $\text{RV} < 2 \text{ cm}^3$ have a significantly higher OS, PFS, and an advantage of TMT. The PFS of patients with $\text{RV} < 2 \text{ cm}^3$ is significantly higher than the other subgroups. Therefore, in the STR subgroup, the presence of a lower RV has a significant advantage in terms of PFS.

TP53 mutation was present in 6.4% of patients in the DA group. This mutation disclosed a statistically significant negative association with OS ($r=-0.513$; $p=0.018$; standard error (SE)=0.159) and with PFS ($r=-0.519$; $p=0.016$; SE=0.161). 9.2% of these patients presented also an EGFR amplification/EGFRvIII mutation, negatively related with OS ($r=-0.544$; $p=0.011$; SE=0.162) and PFS ($r=-0.561$; $p=0.008$; SE=0.162). This analysis of correlation is reported in Table II. The EGFR amplification/EGFRvIII mutation is already an adverse prognostic factor for both OS and PFS in glioma after TMT.

OG Group. The OG group comprised 29 patients presenting an average OS of 87.9 months, a PFS of 56.3 months, a TMT of 69.1 months, and a KPS of 89.8 months. This group was followed by a medium follow-up period of 76.6 months. Overall, the OG group has a greater advantage in terms of OS, PFS, and TMT compared to the DA group (Table III). Thirteen patients in this group received a GTR and 16 received a STR. GTR subgroup reported an averaged 101.7 months OS, 64.9 months PFS, 80.3 months TMT and an average KPS of 84.2. This subgroup did not receive adjuvant chemotherapy or radiotherapy. The GTR subgroup of OG has a more extensive OS, PFS, and TMT than the GTR subgroup

Table II. Correlation between overall survival (OS)/progression free survival (PFS) and mutations; TP53 mutation and epidermal growth factor receptor (EGFR amplification/EGFRvIII) mutation in the diffuse astrocytoma isocitrate dehydrogenase (IDH)-mutant group.

Correlation of Pearson	Overall survival	
	TP53	EGFR
r	-0.513	-0.544
p-Value	0.018	0.011
Bootstrap		
Distortion	0.012	0.002
Standard error	0.159	0.162
Confidence interval 95%		
Inf	-0.780	-0.817
Sup	-0.143	-0.173
Correlation of Pearson	Progression-free survival	
	TP53	EGFR
R	-0.519	-0.561
p-Value	0.016	0.008
Bootstrap		
Distortion	0.008	0.004
Standard error	0.161	0.162
Confidence interval 95%		
Inf	-0.784	-0.830
Sup	-0.151	-0.186

Inf: Infimum; Sup: supremum.

of DA. The difference is also significant in terms of TMT as reported in Table III.

The STR subgroup had an average OS of 73.3 months, PFS of 48.2 months, TMT of 57.3, and the average postoperative KPS was 96.2 (Table III). In this subgroup, the average RV was 3 cm^3 (Figure 5). The following dependent variables showed a statistically significant difference between GTR and STR subgroups: OS ($p=0.0001$), PFS ($p=0.002$), and TMT ($p=0.001$). The results are summarised in Table III and their differences are illustrated in Figure 5. Compared to the DA subgroup, the STR subgroup of OG has a larger OS, PFS, and TMT. Although RV differences are less significant than DA's STR subgroup, as shown in Figure 5.

Table III summarises the results of the two groups of patients with their subgroups in terms of OS, PFS, 5-year survival (months), KPS, and TMT.

Discussion

Low-grade gliomas are classified using molecular markers instead of histological and morphological characteristics. The DLGGs with 1p/19q codeletion show lower immune cell infiltration and lower expression of immune checkpoint genes than the non-codeletion cases (15). The 1p/19q co-deletion

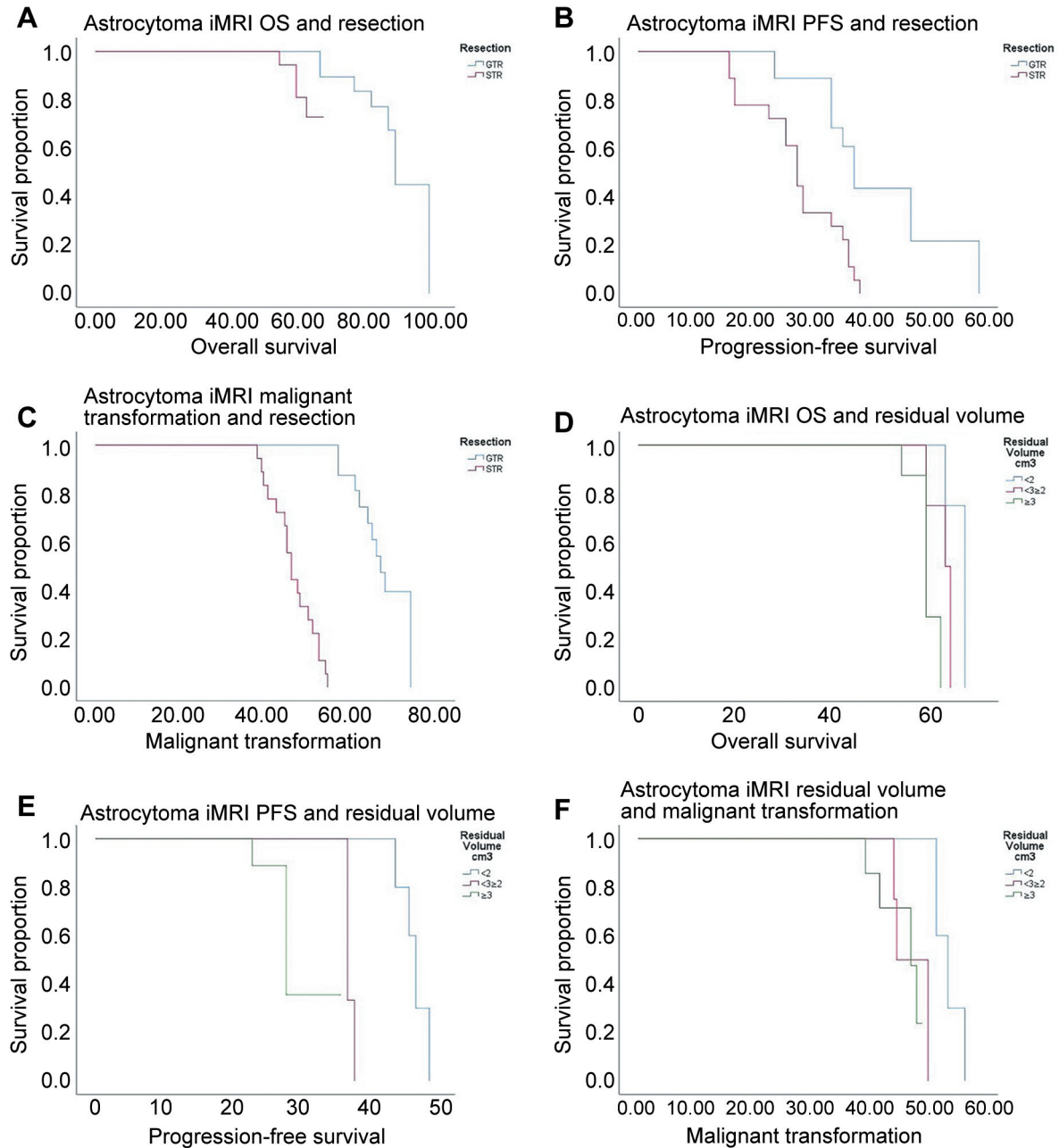


Figure 4. Kaplan–Meier curves for the comparison in the diffuse astrocytoma isocitrate dehydrogenase (IDH)-mutant group. (A) Overall survival (months) comparison between subgroup gross total resection (GTR in blue) and sub-total resection (STR) (in red). (B) Progression-free survival (PFS) (months) between subgroups GTR (blue) and STR (red). (C) Malignant transformation (months) between subgroup GTR (blue) and STR (red). (D) Overall survival (months) comparison between the different subgroups with residual tumour volume (RV) less than 2 cm³ (blue), between 2 and 3 cm³ subgroup (red) and RV above 3 cm³ subgroup (green). (E) PFS (months) and RV (cm³) are compared between subgroups with RV <2 cm³ (blue), subgroup with RV between 2 and 3 cm³ (red) and subgroup with RV ≥3 cm³ (green). (F) Malignant transformation (months) and RV (cm³) between subgroups regarding RV <2 cm³ (blue), subgroup with RV between 2 and 3 cm³ (red) and subgroup with RV ≥3 cm³ (green).

status reflects distinct tumour-associated macrophages (TAM) infiltration in gliomas, which is likely mediated by macrophage colony-stimulating factor (M-CSF) and transforming growth factor beta 1 (TGF1) signalling (16).

The presence of 1p/19q codeletion can be a discriminative feature for the diagnosis of DLGG and these would need to be analysed for 1p/19q codeletion status to meet 2021 WHO Classification of tumours of the CNS diagnostic requirements.

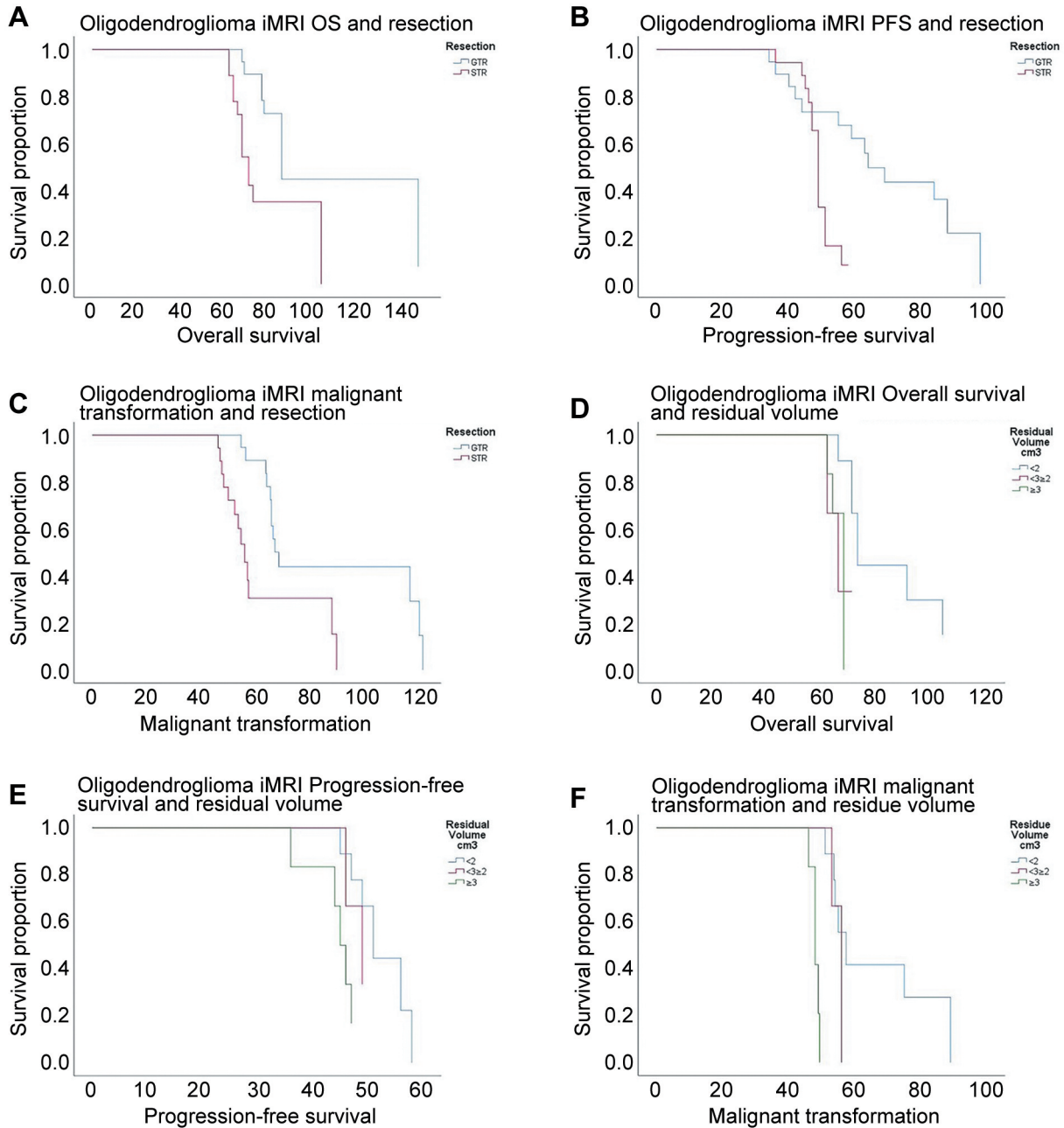


Figure 5. The Kaplan-Meier curves are used to compare the oligodendroglioma isocitrate dehydrogenase (IDH)-mutated and 1p/19q codeleted group. (A) The overall survival (OS months) of the subgroup gross total resection (GTR in blue) and sub-total resection (STR) (in red). (B) Progression-free survival (PFS months) between Subgroup GTR (blue) and STR (red). (C) Malignant transformation (months) between subgroup GTR (blue) and STR (red). (D) OS comparison between different subgroups; with residual volume (RV) <2 cm³ (blue), with RV between 2 and 3 cm³ (red) and with RV ≥3 (green). (E) PFS (months) confront between subgroups with RV <2 cm³ (blue), subgroup with RV between 2 and 3 cm³ (red) and subgroup with RV ≥3 cm³ (green). (F) Malignant transformation (months) and residual volume (cm³) confront the subgroup with RV <2 cm³ (blue), subgroup with 2 ≤ RV <3 (red) and subgroup with RV ≥3 (green).

In fact, a diffuse glioma that is histologically astrocytic, 1p/19q codeleted and IDH mutation need to be diagnosed as an oligodendroglioma (16, 17). The study aimed to investigate the impact of 1p/19q codeletion on prognosis, on long-term

outcomes of patients and verify their independence from EOR. The specific objective of the authors study is to examine survival parameters (OS, PFS and TMT) in a cohort of patients affected by DLGG with accurate and distinct genetic patterns.

Table III. Overall survival (OS), progression-free survival (PFS), Karnofsky Performance Status (KPS), and time to malignant transformation (TMT) in diffuse astrocytoma (DA) isocitrate dehydrogenase (IDH)-mutant and the oligodendroglioma IDH-mutant with 1p/19q codeletion.

Tumour type	N°	OS (STD)	PFS (STD)	5-year survival rate (STD)	KPS (STD)	TMT (STD)
Diffuse astrocytoma IDH-Mutant (DA group)	37	71.3 (12.6)	42.8 (6.8)	88.7%	85.5 (15.5)	55.3 (10.8)
GTR	16	81.6 (8.3)	45.9 (8.3)	93.1%	83.4 (6.8)	63.6 (7.5)
STR	21	60.4 (4.5)	38.7 (7.8)	75.5%	92.4 (4.9)	46.4 (5.2)
<i>p</i> -Value GTR vs. STR		<0.012	<0.003		0.03	<0.001
Oligodendroglioma IDH-Mutant and 1p/19q Codeleted (OG group)	29	87.9 (28.8)	56.3 (15.9)	91.1%	89.8 (10)	69.1 (23.8)
GTR	13	101.7 (32.9)	64.9 (21.4)	98.7%	84.2 (11.8)	80.3 (26.4)
STR	16	73.3 (12.9)	48.2 (4.8)	80.9%	96.2 (5)	57.3 (12.9)
<i>p</i> -Value GTR vs. STR		0.0001	<0.002			0.001

STD: Standard deviation; STR: subtotal resection; GTR: gross total resection.

All patients had undergone surgery between December 2008 and December 2018, using the Io-MRI from Sant'Andrea University Hospital of Rome. In addition, all included patients received a homogeneous schedule of adjuvant treatments and underwent the same neuro-radiological follow-up protocol. The selected patients were divided into two groups based on the presence of 1p/19q codeletion. Within the two groups, two subgroups were identified based on EOR (GTR and STR). We were able to compare the results with the same EOR grades. In our cohort, the maximal safe resection preserved neurological functions. Awake Surgery and Brain Mapping are the gold standards for safely maximising the resection of lesions affecting the eloquent areas. High safety and effectiveness profiles for resection lesions in the eloquent areas are guaranteed through the integrated use of these technologies and techniques (19). Several studies have strongly suggested that Io-MRI extends survival due to a greater EOR (20-22). Since neurological deficits have been associated with a poor oncologic prognosis as independent factors, we performed an appropriate approach to maximise the resection without compromising neurological function therefore reducing the risk of brain shift in neuronavigation after dural opening. (23-25).

Several trials studied the impact of treatment on survival and surgery compared to conservative treatments resulted in improving survival (26). According to our data, the first-line treatment depends on the markers analysed (27). Alternatively, Cordier asserts that the resection positively impacts survival, independent of the molecular markers. He reports a large cohort of DLGGs where higher EOR was not related to a better molecular prognosis (28). Our results demonstrate that the EOR and 1p-19q codeletion are two OS-independent prognostic factors. This molecular marker is mainly related to the TMT, and also related to the PFS. The comparison of the outcome of the subgroups GTR and

STR shows that 1p/19q codeletion predicts an improved OS and a longer TMT.

The results of our study do not support the hypothesis proposed by Cordier *et al.*, which states that longer survival of DLGG patients who benefited from a maximal EOR could be attributable to a favourable genetic profile (28).

Similarly to Scherer *et al.* (29), our data demonstrate that a lower RV <2 cm³ is related to a better prognosis in terms of OS and PFS in both the examined patients. GTR group produced a statistically significant survival advantage compared to those associated with STR in the OG group (101.7 vs. 73.3 months, *p*=0.0001). Similar findings were confirmed in patients affected by DA (81.6 vs. 60.4 *p*=0.012), despite the globally shorter survival. Our data show that GTR is more significant, in terms of survival, in both the patient's group we examined. However, the patients who present this codeletion have an overall greater survival and its prognostic value results independent of EOR. Patients with DLGG IDH-mutated and 1p/19q codeletion have significantly greater survival than the patient without the codeletion. The presence of 1p/19q codeletion is associated with a longer PFS, and the most significant difference is related to a larger TMT. Regarding the EOR in surgery for DLGG, resection size is more strongly connected to PFS than OS (30-34). We found that patients with a GTR had a longer average PFS, independent of their molecular patterns. A significant PFS difference was observed in patients suffering from DA undergoing STR: an R <2 cm³ was associated with a significantly longer PFS. A significantly longer TMT interval was observed in patients with 1p/19q codeletion. However, we found a significantly shorter TMT interval when the RV was greater than 3 cm³ in this group of patients. We report that there is a strong statistical difference in TMT within the OG group between patients with RV less than 2 cm³ versus those with RV greater than

3 cm³. The higher the number of residual oncological cells, the greater the probability of malignant transformation.

The p53 positivity in >10% predicts TP53 mutations and Amplification/EGFRvIII mutation has already been reported as a negative prognostic factor for both OS and PFS in glioma after TMT (32). These mutations are commonly found in inactivating mutations in ATRX in IDH-mutated DLGGs. The suitability of death receptor 6 (DR6) as a prognostic marker was tested since it is up-regulated in gliomas and shows an aberrant signalling network. The effect of DR6 as a prognostic marker, playing an opposing role in primary and relapsed DLGG, is an interesting candidate for further studies (35).

In our study, the presence of a TP53 mutation and an EGFR amplification/EGFRvIII mutation in the DA group was associated with a shorter OS and PFS. These mutations were associated with a higher grade of glioma development.

Conclusion

This study demonstrated that the EOR and 1p-19q codeletion are two independent prognostic factors on overall survival and do not support the hypothesis that longer survival of DLGG patients which benefited from a maximal EOR could be attributable to the presence of the 1p-19 codeletion. Furthermore, we investigated the role of the 1p/19q codeletion in DLGGs and presented the findings of 1p/19q codeletion as an independent prognostic factor associated with a prolonged survival and a longer TMT. We found that EOR maintains its role as a prognostic factor in managing DLGG treatment, especially when the residual volume is less than 2 cm³, and that progression-free survival is longer for patients with DA IDH-mutated DLGG. TMT interval was significantly shorter in OG IDH-mutated and 1p/19q codeleted DLGG patients with RV less than 2 cm³, compared to those with RV greater than 3 cm³.

Patients who present with 1p/19q codeletion have an extended survival, independent of the surgical extent of resection. TP53 mutation and EGFR amplification/EGFRvIII mutation in DLGG are negatively correlated with OS and PFS.

Conflicts of Interest

The Authors declare no conflicts of interest.

Authors' Contributions

Conceptualisation, P.B., P.L., P.F. and G.D.A.; methodology, P.B. and P.F.; software, P.B. and P.F.; validation, G.D.A., A.S., F.A. and M.S.; formal analysis, P.F., A.D. and P.B.; investigation, P.B., G.C., A.P. and V.P.; resources, G.C. and V.P.; data curation, P.B, P.L., and A.D.; writing – original draft preparation, P.F., A.D., A.P. and P.L.; writing – review and editing, P.F., P.L., A.D. and M.R.; visualisation, M.S., A.F. and A.S.; supervision, P.F., P.L., G.D.A.,

A.S., F.A. and M.S.; project administration, P.B. and G.D.A.; funding acquisition, M.R. All Authors have read and agreed to the published version of the manuscript.

Acknowledgements

The authors acknowledge Dr. Pierpaolo Moio for language editing and Dr. Veronica Bruzzaniti for the well-finished graphical part of this paper.

Funding

This research was funded by Sapienza University Funds. Pierfrancesco Lapolla was supported by the Rotary Foundation Global Grant.

References

- Rasmussen BK, Hansen S, Laursen RJ, Kosteljanetz M, Schultz H, Nørgård BM, Guldberg R and Gradel KO: Epidemiology of glioma: clinical characteristics, symptoms, and predictors of glioma patients grade I-IV in the the Danish Neuro-Oncology Registry. *J Neurooncol* 135(3): 571-579, 2017. PMID: 28861666. DOI: 10.1007/s11060-017-2607-5
- Weller M, van den Bent M, Tonn JC, Stupp R, Preusser M, Cohen-Jonathan-Moyal E, Henriksson R, Le Rhun E, Balana C, Chinot O, Bendszus M, Reijneveld JC, Dhermain F, French P, Marosi C, Watts C, Oberg I, Pilkington G, Baumert BG, Taphoorn MJB, Hegi M, Westphal M, Reifenberger G, Soffietti R, Wick W and European Association for Neuro-Oncology (EANO) Task Force on Gliomas: European Association for Neuro-Oncology (EANO) guideline on the diagnosis and treatment of adult astrocytic and oligodendroglial gliomas. *Lancet Oncol* 18(6): e315-e329, 2017. PMID: 28483413. DOI: 10.1016/S1470-2045(17)30194-8
- Fuller CE, Jones DTW and Kieran MW: New classification for central nervous system tumors: implications for diagnosis and therapy. *Am Soc Clin Oncol Educ Book* 37: 753-763, 2017. PMID: 28561665. DOI: 10.1200/EDBK_175088
- Brown TJ, Bota DA, van Den Bent MJ, Brown PD, Maher E, Aregawi D, Liau LM, Buckner JC, Weller M, Berger MS and Glantz M: Management of low-grade glioma: a systematic review and meta-analysis. *Neurooncol Pract* 6(4): 249-258, 2019. PMID: 31386075. DOI: 10.1093/nop/npy034
- Duffau H: Long-term outcomes after supratotal resection of diffuse low-grade gliomas: a consecutive series with 11-year follow-up. *Acta Neurochir (Wien)* 158(1): 51-58, 2016. PMID: 26530708. DOI: 10.1007/s00701-015-2621-3
- Yan H, Parsons DW, Jin G, McLendon R, Rasheed BA, Yuan W, Kos I, Batinic-Haberle I, Jones S, Riggins GJ, Friedman H, Friedman A, Reardon D, Herndon J, Kinzler KW, Velculescu VE, Vogelstein B and Bigner DD: IDH1 and IDH2 mutations in gliomas. *N Engl J Med* 360(8): 765-773, 2009. PMID: 19228619. DOI: 10.1056/NEJMoa0808710
- Kim YH, Nobusawa S, Mittelbronn M, Paulus W, Brokinkel B, Keyvani K, Sure U, Wrede K, Nakazato Y, Tanaka Y, Vital A, Mariani L, Stawski R, Watanabe T, De Girolami U, Kleihues P and Ohgaki H: Molecular classification of low-grade diffuse gliomas. *Am J Pathol* 177(6): 2708-2714, 2010. PMID: 21075857. DOI: 10.2353/ajpath.2010.100680

- 8 Louis DN, Perry A, Wesseling P, Brat DJ, Cree IA, Figarella-Branger D, Hawkins C, Ng HK, Pfister SM, Reifenberger G, Soffietti R, von Deimling A and Ellison DW: The 2021 WHO Classification of Tumors of the Central Nervous System: a summary. *Neuro Oncol* 23(8): 1231-1251, 2021. PMID: 34185076. DOI: 10.1093/neuonc/noab106
- 9 Eckel-Passow JE, Lachance DH, Molinaro AM, Walsh KM, Decker PA, Sicotte H, Pekmezci M, Rice T, Kosel ML, Smirnov IV, Sarkar G, Caron AA, Kollmeier TM, Praska CE, Chada AR, Halder C, Hansen HM, McCoy LS, Bracci PM, Marshall R, Zheng S, Reis GF, Pico AR, O'Neill BP, Buckner JC, Giannini C, Huse JT, Perry A, Tihan T, Berger MS, Chang SM, Prados MD, Wiemels J, Wiencke JK, Wrensch MR and Jenkins RB: Glioma groups based on 1p/19q, IDH, and TERT promoter mutations in tumors. *N Engl J Med* 372(26): 2499-2508, 2015. PMID: 26061753. DOI: 10.1056/NEJMoa1407279
- 10 Okamoto Y, Di Patre PL, Burkhard C, Horstmann S, Jourde B, Fahey M, Schüler D, Probst-Hensch NM, Yasargil MG, Yonekawa Y, Lütolf UM, Kleihues P and Ohgaki H: Population-based study on incidence, survival rates, and genetic alterations of low-grade diffuse astrocytomas and oligodendrogliomas. *Acta Neuropathol* 108(1): 49-56, 2004. PMID: 15118874. DOI: 10.1007/s00401-004-0861-z
- 11 Salvati M, Bruzzaniti P, Relucanti M, Nizzola M, Familiari P, Giugliano M, Scafa A, Galletta S, Li X, Chen R, Barbaranelli C, Frati A and Santoro A: Retrospective and randomized analysis of influence and correlation of clinical and molecular prognostic factors in a mono-operative series of 122 patients with glioblastoma treated with STR or GTR. *Brain Sciences* 10(2): 91, 2020. DOI: 10.3390/brainsci10020091
- 12 Caseiras GB, Chheang S, Babb J, Rees JH, Pecrerelli N, Tozer DJ, Benton C, Zagzag D, Johnson G, Waldman AD, Jäger HR and Law M: Relative cerebral blood volume measurements of low-grade gliomas predict patient outcome in a multi-institution setting. *Eur J Radiol* 73(2): 215-220, 2010. PMID: 19201123. DOI: 10.1016/j.ejrad.2008.11.005
- 13 Barajas RF Jr and Cha S: Benefits of dynamic susceptibility-weighted contrast-enhanced perfusion MRI for glioma diagnosis and therapy. *CNS Oncol* 3(6): 407-419, 2014. PMID: 25438812. DOI: 10.2217/cns.14.44
- 14 Wahl M, Phillips JJ, Molinaro AM, Lin Y, Perry A, Haas-Kogan DA, Costello JF, Dayal M, Butowski N, Clarke JL, Prados M, Nelson S, Berger MS and Chang SM: Chemotherapy for adult low-grade gliomas: clinical outcomes by molecular subtype in a phase II study of adjuvant temozolomide. *Neuro Oncol* 19(2): 242-251, 2017. PMID: 27571885. DOI: 10.1093/neuonc/nou176
- 15 Lv L, Zhang Y, Zhao Y, Wei Q, Zhao Y and Yi Q: Effects of 1p/19q codeletion on immune phenotype in low grade glioma. *Front Cell Neurosci* 15: 704344, 2021. PMID: 34335194. DOI: 10.3389/fncel.2021.704344
- 16 Zhang Y, Xie Y, He L, Tang J, He Q, Cao Q, Cui L, Guo W, Hua K, Dimberg A, Wang L and Zhang L: 1p/19q co-deletion status is associated with distinct tumor-associated macrophage infiltration in IDH mutated lower-grade gliomas. *Cell Oncol (Dordr)* 44(1): 193-204, 2021. PMID: 32915415. DOI: 10.1007/s13402-020-00561-1
- 17 Sbaraglia M, Bellan E and Dei Tos AP: The 2020 WHO Classification of Soft Tissue Tumours: news and perspectives. *Pathologica* 113(2): 70-84, 2021. PMID: 33179614. DOI: 10.32074/1591-951X-213
- 18 Louis DN, Giannini C, Capper D, Paulus W, Figarella-Branger D, Lopes MB, Batchelor TT, Cairncross JG, van den Bent M, Wick W and Wesseling P: cIMPACT-NOW update 2: diagnostic clarifications for diffuse midline glioma, H3 K27M-mutant and diffuse astrocytoma/anaplastic astrocytoma, IDH-mutant. *Acta Neuropathol* 135(4): 639-642, 2018. PMID: 29497819. DOI: 10.1007/s00401-018-1826-y
- 19 Liang D and Schulder M: The role of intraoperative magnetic resonance imaging in glioma surgery. *Surg Neurol Int* 3(Suppl 4): S320-S327, 2012. PMID: 23230537. DOI: 10.4103/2152-7806.103029
- 20 Claus EB, Horlacher A, Hsu L, Schwartz RB, Dello-Iacono D, Talos F, Jolesz FA and Black PM: Survival rates in patients with low-grade glioma after intraoperative magnetic resonance image guidance. *Cancer* 103(6): 1227-1233, 2005. PMID: 15690327. DOI: 10.1002/cncr.20867
- 21 Mariani L, Siegenthaler P, Guzman R, Friedrich D, Fathi AR, Ozdoba C, Weis J, Ballinari P and Seiler RW: The impact of tumour volume and surgery on the outcome of adults with supratentorial WHO grade II astrocytomas and oligoastrocytomas. *Acta Neurochir (Wien)* 146(5): 441-448, 2004. PMID: 15118879. DOI: 10.1007/s00701-004-0222-7
- 22 Hatiboglu MA, Weinberg JS, Suki D, Rao G, Prabhu SS, Shah K, Jackson E and Sawaya R: Impact of intraoperative high-field magnetic resonance imaging guidance on glioma surgery: a prospective volumetric analysis. *Neurosurgery* 64(6): 1073-81; discussion 1081, 2009. PMID: 19487886. DOI: 10.1227/01.NEU.0000345647.58219.07
- 23 Gogos AJ, Young JS, Morshed RA, Hervey-Jumper SL and Berger MS: Awake glioma surgery: technical evolution and nuances. *J Neurooncol* 147(3): 515-524, 2020. PMID: 32270374. DOI: 10.1007/s11060-020-03482-z
- 24 Gorlia T, Wu W, Wang M, Baumert BG, Mehta M, Buckner JC, Shaw E, Brown P, Stupp R, Galanis E, Lacombe D and van den Bent MJ: New validated prognostic models and prognostic calculators in patients with low-grade gliomas diagnosed by central pathology review: a pooled analysis of EORTC/RTOG/NCCTG phase III clinical trials. *Neuro Oncol* 15(11): 1568-1579, 2013. PMID: 24049111. DOI: 10.1093/neuonc/not117
- 25 Duffau H and Taillandier L: New concepts in the management of diffuse low-grade glioma: Proposal of a multistage and individualized therapeutic approach. *Neuro Oncol* 17(3): 332-342, 2015. PMID: 25087230. DOI: 10.1093/neuonc/nou153
- 26 Nabors LB, Portnow J, Ahluwalia M, Baehring J, Brem H, Brem S, Butowski N, Campian JL, Clark SW, Fabiano AJ, Forsyth P, Hattangadi-Gluth J, Holdhoff M, Horbinski C, Junck L, Kaley T, Kumthekar P, Loeffler JS, Mrugala MM, Nagpal S, Pandey M, Parney I, Peters K, Puduvalli VK, Robins I, Rockhill J, Rusthoven C, Shonka N, Shrieve DC, Swinnen LJ, Weiss S, Wen PY, Willmarth NE, Bergman MA and Darlow SD: Central nervous system cancers, version 3.2020, NCCN clinical practice guidelines in oncology. *J Natl Compr Canc Netw* 18(11): 1537-1570, 2020. PMID: 33152694. DOI: 10.6004/jnccn.2020.0052
- 27 Wijnga MMJ, French PJ, Dubbink HJ, Dinjens WNM, Atmodimedjo PN, Kros JM, Smits M, Gahrman R, Rutten GJ, Verheul JB, Fleischeuer R, Dirven CMF, Vincent AJPE and van den Bent MJ: The impact of surgery in molecularly defined low-grade glioma: an integrated clinical, radiological, and molecular analysis. *Neuro Oncol* 20(1): 103-112, 2018. PMID: 29016833. DOI: 10.1093/neuonc/nox176

- 28 Cordier D, Gozé C, Schädelin S, Rigau V, Mariani L and Duffau H: A better surgical resectability of WHO grade II gliomas is independent of favorable molecular markers. *J Neurooncol* 121(1): 185-193, 2015. PMID: 25261925. DOI: 10.1007/s11060-014-1623-y
- 29 Scherer M, Ahmeti H, Roder C, Gessler F, Jungk C, Pala A, Mayer B, Senft C, Tatagiba M, Synowitz M, Wirtz CR, Unterberg AW and Coburger J: Surgery for diffuse WHO grade II gliomas: Volumetric analysis of a multicenter retrospective cohort from the German study group for intraoperative magnetic resonance imaging. *Neurosurgery* 86(1): E64-E74, 2020. PMID: 31574147. DOI: 10.1093/neuros/nyz397
- 30 Smith JS, Chang EF, Lamborn KR, Chang SM, Prados MD, Cha S, Tihan T, Vandenberg S, McDermott MW and Berger MS: Role of extent of resection in the long-term outcome of low-grade hemispheric gliomas. *J Clin Oncol* 26(8): 1338-1345, 2008. PMID: 18323558. DOI: 10.1200/JCO.2007.13.9337
- 31 Nakamura M, Konishi N, Tsunoda S, Nakase H, Tsuzuki T, Aoki H, Sakitani H, Inui T and Sakaki T: Analysis of prognostic and survival factors related to treatment of low-grade astrocytomas in adults. *Oncology* 58(2): 108-116, 2000. PMID: 10705237. DOI: 10.1159/000012087
- 32 Yeh SA, Ho JT, Lui CC, Huang YJ, Hsiung CY and Huang EY: Treatment outcomes and prognostic factors in patients with supratentorial low-grade gliomas. *Br J Radiol* 78(927): 230-235, 2005. PMID: 15730987. DOI: 10.1259/bjr/28534346
- 33 Ius T, Isola M, Budai R, Pauletto G, Tomasino B, Fadiga L and Skrap M: Low-grade glioma surgery in eloquent areas: volumetric analysis of extent of resection and its impact on overall survival. A single-institution experience in 190 patients: clinical article. *J Neurosurg* 117(6): 1039-1052, 2012. PMID: 23039150. DOI: 10.3171/2012.8.JNS12393
- 34 Eseonu CI, Eguia F, ReFaey K, Garcia O, Rodriguez FJ, Chaichana K and Quinones-Hinojosa A: Comparative volumetric analysis of the extent of resection of molecularly and histologically distinct low grade gliomas and its role on survival. *J Neurooncol* 134(1): 65-74, 2017. PMID: 28527004. DOI: 10.1007/s11060-017-2486-9
- 35 Stegmann SK, Kuhl S, Im NG, Diem-Dinh DT, Goertz L, Goldbrunner R and Timmer M: Death receptor 6 as a prognostic marker in low-grade glioma. *Anticancer Res* 42(3): 1237-1245, 2022. PMID: 35220214. DOI: 10.21873/anticancer.15591

Received December 5, 2022

Revised March 18, 2023

Accepted April 24, 2023