

EXPERT  
REVIEWS

# Advancement in the clinical management of intestinal pseudo-obstruction

Expert Rev. Gastroenterol. Hepatol. Early online, 1–12 (2014)

Augusto Lauro\*<sup>1</sup>,  
Roberto De Giorgio<sup>2</sup>  
and Antonio Daniele  
Pinna<sup>1</sup>

<sup>1</sup>General Surgery and Transplant Unit,  
St. Orsola-Malpighi University Hospital,  
University of Bologna, Bologna, Italy

<sup>2</sup>Department of Digestive Diseases and  
Internal Medicine, St. Orsola-Malpighi  
University Hospital, University of  
Bologna, Bologna, Italy

\*Author for correspondence:

Tel.: +39 051 636 3721

Fax: +39 051 304 902

augustola@yahoo.com

Intestinal pseudo-obstruction is more commonly known in its chronic form (CIPO), a cluster of rare diseases characterized by gastrointestinal muscle and nerve impairment, so severe to result in a markedly compromised peristalsis mimicking an intestinal occlusion. The management of CIPO requires the cooperation of a group of specialists: the disease has to be confirmed by a number of tests to avoid mistakes in the differential diagnosis. The treatment should be aimed at relieving symptoms arising from gut dysmotility (ideally using prokinetic agents), controlling abdominal pain (possibly with non-opioid antinociceptive drugs) and optimizing nutritional support. Furthermore, a thorough diagnostic work-up is mandatory to avoid unnecessary (potentially harmful) surgery and to select patients with clear indication to intestinal or multivisceral transplantation.

**KEYWORDS:** chronic intestinal pseudo-obstruction • enteral nutrition • intestinal diseases • intestinal motility • jejunostomy • manometry • parenteral nutrition • prokinetics • transplantation

Intestinal pseudo-obstruction syndromes represent a challenge, often remaining poorly understood or frequently misdiagnosed by clinicians and surgeons. Nonetheless, the evidence of an intestinal 'pseudo'-obstruction as cause of chronic gastrointestinal symptoms dates back to Dudley *et al.* who reported in the late 50s their experience on 13 cases of exploratory surgery in patients with intestinal sub-occlusion without evidence of mechanical obstruction [1]. The present review will focus on chronic intestinal pseudo-obstruction (CIPO), which involves any segment of the whole gut, although the small bowel is the main target. In a broad view, CIPO can be considered an end-stage syndrome (either idiopathic or secondary to a wide array of conditions) resulting in an 'intestinal pump' insufficiency due to a defective muscular function, unable to generate coordinated motor patterns propelling the gut luminal contents. From a histopathological standpoint, CIPO can be characterized by abnormalities of the enteric smooth muscles, nerves (either intrinsic, the enteric nervous system [ENS] or extrinsic) and interstitial cells of Cajal (ICC, the gut pacemaker system) either alone or in combination. The present review is aimed to report an update on the currently available knowledge

about CIPO in an attempt to provide clinicians and surgeons with a better understanding of the clinical management related to the syndrome.

## Incidence & prevalence

Overall, CIPO is quite a rare condition in clinical practice and currently there is no definitive knowledge about its prevalence or incidence in most countries. Nonetheless, two recent surveys by Ohkubo *et al.* [2] and Iida *et al.* [3] reported on 138 cases of CIPO (mainly affecting adult population) from 378 institutions in Japan with an incidence and a prevalence of 0.21 and 0.24 and 1.00 and 0.80 cases/100,000 males and females, respectively. In those studies, patient's mean age was 63.1 years for males and 59.2 for females, which is above the average reported in other western countries (mean age 39.0 ± 14.2 years) [4]; probably the enrollment of patients with colonic pseudo-obstruction, occurring mainly in elderly people, has contributed to increase the mean age of the Japanese studies.

The limited awareness of this disorder by many physicians and surgeons along with the difficulty in establishing a firm diagnosis contribute significantly to downsize the

**Table 1. Classification and causes of chronic intestinal pseudo-obstruction.**

Idiopathic	Secondary
Neuropathy	Collagen vascular diseases
– Inflammatory	– Primary systemic sclerosis
– Degenerative	– Systemic lupus erythematosus
Myopathy	– Dermatomyositis/polymyositis
Mesenchymopathy	– Periarteritis nodosa
	– Rheumatoid arthritis
	– Mixed connective tissue disorders
	Endocrine disorders
	– Diabetes
	– Hypothyroidism
	– Parathyroidism
	Neurologic disorders
	– Parkinson's disease
	– Alzheimer's disease
	– Shy-Drager syndrome
	– Chagas disease
	– Intestinal hypoganglionosis
	– Dysautonomia (familial or sporadic)
	Medication associated
	– Tricyclic antidepressants
	– Anticholinergic agents
	– Ganglionic blockers
	– Anti-parkinsonian agents
	– Clonidine
	– Phenothiazines
	Miscellaneous
	– Celiac disease
	– Paraneoplastic syndromes (small cell lung carcinoma, carcinoid, thymoma)
	– Infiltrative disorders (amyloidosis, lymphoma)
	– Alcohol abuse
	– Post-infectious processes (viral – herpes virus and John Cunningham virus – bacterial, parasitic)
	– Radiation
	– Vascular insufficiency
	– Metabolic (hypokalemia, hypomagnesemia)
	– Post-surgical
	– Post-organ transplant
	– Mitochondrial disorders
	– Eosinophilic myenteric ganglionitis
	– Paragangliomas
	– Sick sinus syndrome

epidemiology of CIPO. Finally, most CIPO cases are sporadic, although familial forms with either dominant or recessive autosomal inheritance have been described [5,6].

### Etiopathogenesis

Abnormalities of control systems active in regulating gastrointestinal function (i.e., smooth muscle cells, intrinsic and extrinsic neurons and ICCs) can determine severe dysmotility patterns observed in patients with CIPO [7]. Neuro-ICC-muscular abnormalities in CIPO may be the consequence of a variety of well-defined diseases (e.g., diabetes mellitus, amyloidosis, paraneoplastic syndromes, etc.), or idiopathic in origin [7,8].

Furthermore, few peculiar cases of CIPO have a syndromic manifestation with multisystem involvement typically associated with a familial cluster, indicative of a genetic origin. A detailed analysis on neuropathies/myopathies/ICCpathies (mesenchymopathies) is beyond the purpose of the present review and the reader is referred to in-depth reviews [8–10]. In 2009, the London Classification of Gastrointestinal Neuromuscular Pathologies [10] provided consensus among a group of experts on the identification of three major forms of CIPO, that is, neuropathies/myopathies and/or mesenchymopathies (or ICCpathies), occurring alone or in combination (e.g., neuromyopathy, neuro-ICCpathy and neuro-ICCmyopathy). Briefly, neuropathic abnormalities are most commonly reported/identified in full-thickness gut biopsies of CIPO patients and often involve the ENS, although the autonomic nervous system (either the sympathetic or parasympathetic components) may be also affected. A variety of inflammatory, degenerative and infectious processes are now known to damage intrinsic and extrinsic nerves in CIPO [11–16]. Early evidence showed that neurotropic viruses could infect and alter the ENS in CIPO patients [17], and these results have been recently confirmed. Specifically, Selgrad *et al.* [11] showed that the John Cunningham virus (JCV), a polyomavirus known to cause the progressive multifocal leukoencephalopathy (a fatal demyelinating disease of the CNS in immunocompromised patients), can be detected in the myenteric ganglia of adult patients with CIPO. Very notably, the JCV antigens and capsidic proteins are predominantly (if not exclusively) detected in glial ('astrocyte-like') cells of the ENS, a feature reminiscent of glial cells targeted by JCV in the brain. Clearly, further research will be necessary to substantiate how JCV infects glial cells of the ENS and the mechanisms leading to neuropathy in CIPO patients. Similar to neuropathies, myopathies as well as mesenchymopathies (or ICCpathies) can be idiopathic or secondary to many different types of conditions in pediatric and adult CIPO and a summary list is shown in TABLE 1.

### Diagnosis

CIPO is a clinical challenge, being an example of a difficult condition rarely encountered in daily practice. The first difficulty for physicians dealing with these patients is to establish a firm diagnosis. The diagnosis of CIPO is essentially clinical and based on the exclusion of mechanical causes of gastrointestinal sub-occlusion. A thorough diagnostic work-up is aimed at: demonstrating the lack of mechanical causes of gut obstruction; identifying associated diseases responsible for secondary forms of CIPO and determining the pathophysiological features of idiopathic CIPO and related complications. The next sections will highlight clinical, radiological, endoscopic, laboratory, scintigraphic, non-invasive approaches, manometric and full-thickness histopathological tests relevant for reaching an appropriate diagnosis of CIPO.

### Symptoms & signs

Symptoms and signs of CIPO are progressive [18–23], apparently normal phases of life alternating with periods dominated by

frequent hospitalizations. The typical history of pediatric and adult patients with CIPO is repeated admissions to the hospital because of symptoms and signs (including radiological features) indicative of intestinal sub-occlusion with no evidence of mechanical obstruction [4]. As a result, CIPO patients may undergo many futile surgical operations before a diagnosis is established [4]. Although the small intestine is the worst affected part of the alimentary tract, any gut segment can be involved in CIPO and this has an impact on clinical manifestations and management. Both adults and children with CIPO usually complain of chronic symptoms such as abdominal pain, bloating and distension (80%), nausea and vomiting (75%) and constipation (40%). Weight loss can be the result of intestinal dysmotility, although in some cases it precedes overt symptoms and signs of CIPO. Pain represents a major concern for CIPO patients and is commonly referred to as crisis of crampy pain (especially at the beginning of the clinical history), then becoming almost continuous and unavoidably associated with bloating and abdominal distension. Sometimes, patients with CIPO are given opioids and end up with a much worse condition than if they had not received those analgesic drugs. A short-term use of opioids can be indicated when patients are admitted with a sub-occlusive episode, but these drugs should be tapered over the coming days and treatment should be directed towards complications (usually bacterial overgrowth) that may have triggered the sub-occlusive event. Other symptoms reported by CIPO patients include: regurgitation, heartburn, dysphagia and chest pain, upper abdominal fullness and early satiety. Chronic constipation often reflects a retarded pan-enteric (including colon) transit. However, the severe impairment of gut motility and transit may also result in diarrhea due to small intestine bacterial overgrowth (SIBO), which further contributes to malnutrition and vitamin deficit. Notably, antibiotic treatment for SIBO may stop diarrhea, but re-exacerbate constipation (see Treatment section 'Medical management' below). One of the most common extra-digestive manifestations includes the genitourinary tract (bladder dysfunction with or without megacystis and megaureter) that can be frequently associated with either neuropathic or (more frequently) myopathic forms of CIPO [18].

### Radiology

Plain x-ray film of the abdomen is essential for the diagnosis of CIPO. This test shows typical signs of intestinal obstruction (i.e., air-fluid levels are best detected with patients in upright position, although unlikely to maintain during sub-occlusive crisis) or rule out mechanical causes. Other tests useful to demonstrate the degree of bowel dilatation are CT scan or magnetic resonance (MR) enterography. These tests may unravel a marked (gastro-duodenal) intestinal dilatation and small bowel diverticuli (often visible in some genetic cases of CIPO such as those related to mitochondrial neurogastrointestinal encephalomyopathy [MNGIE]) and pneumatosis intestinalis. Other ancillary features detectable by radiology (follow-through with water-soluble contrast media/CT scan/MR scan) are the lack of peristalsis (mainly in myopathic forms), or a chaotic peristalsis

(predominantly in neuropathic forms). Recently, the use of cine-MRI has been reported by a Japanese team [24] to assess the whole small bowel caliber and dynamic. Compared with adult healthy volunteers and irritable bowel syndrome cases, the intestinal luminal diameters of CIPO patients showed significantly higher values while the contraction ratio was significantly lower in CIPO patients versus controls and irritable bowel syndrome. These quite interesting results suggest that cine-MRI can become a promising diagnostic tool in CIPO patients.

### Endoscopy

This is useful to identify mechanical occlusions in the upper (gastro-jejunal) and/or lower (ileo-colonic) gastrointestinal tract. Mucosal biopsies should be collected in the duodenum to exclude celiac disease. Natural orifice transluminal endoscopic surgery is one of the new approaches which is expected to increase the diagnostic role of endoscopy in CIPO by providing full-thickness biopsies for histopathological evaluation [25].

### Laboratory

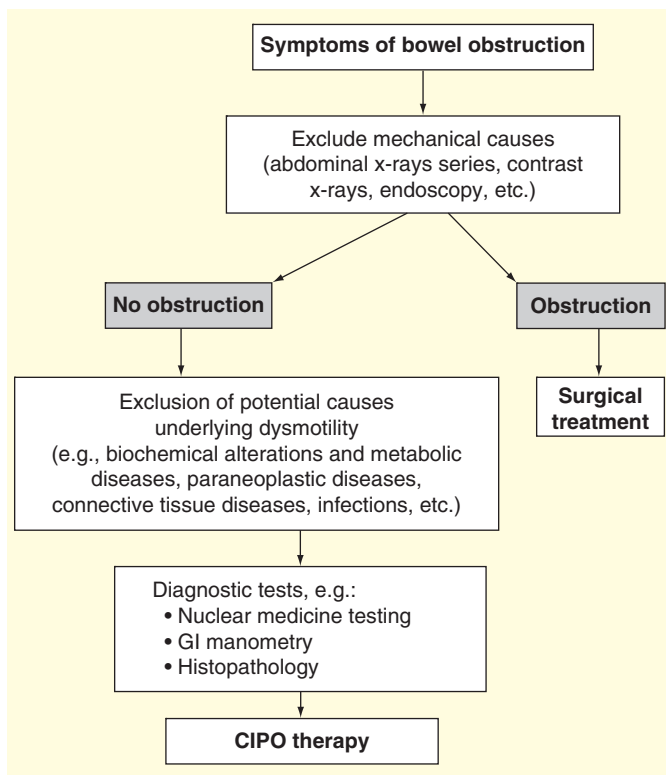
Exams including serum glucose, thyroid-stimulating hormone, complete blood count, albumin, liver enzymes, vitamin B12, inflammatory indexes (e.g., C-reactive protein and sedimentation rate) and autoantibody profile can be useful in identifying secondary forms of CIPO. Circulating antineuronal antibodies, such as anti-neuronal nuclear antibody 1/anti-Hu, should be determined if a paraneoplastic form of CIPO is suspected [26]. Hydro-electrolyte balance and circulating levels of essential elements should be monitored in CIPO patients, particularly those on total parenteral nutrition (TPN).

### Nuclear medicine

Nuclear medicine can support traditional radiology in evaluating the transit time of the gastrointestinal tract. Gastric involvement in CIPO is typically associated with markedly delayed gastric emptying (a condition referred as gastroparesis) and this is most commonly revealed by using a 4-h solid-phase nuclear gastric emptying scan. On the other hand, an indirect measurement of gastric emptying, which correlates with scintigraphy, is the [<sup>13</sup>C]-labeled octanoic acid breath test using the ingestion of stable isotopes and the detection of exhaled carbon-13 carbon dioxide. Scintigraphy can be used to investigate both small bowel and colonic transit in more detail and with greater sensitivity than radio-opaque markers [19,20].

### Manometry

A test that is not commonly available in most centers is the intestinal manometry. Nonetheless, the definition of the enteric manometric profile (i.e., amplitude and coordination of phasic contractions during fasting and after ingestion of a meal) represents an important diagnostic adjunct in patients with CIPO [27,28]. In a recent study, Amiot *et al.* [27] reported the manometric findings of 116 adult CIPO patients (70 females, median age 28 years) with median follow-up time of 6 years:



**Figure 1. Diagnostic algorithm for chronic intestinal pseudo-obstruction.**

CIPO: Chronic intestinal pseudo-obstruction.

90% of patients exhibited at least one abnormal pattern. Esophageal manometry was abnormal in 73% of the patients, including 51% with severe ineffective esophageal motility (ranging from disordered peristalsis up to achalasia). In the study by Amiot *et al.*, gastric emptying was abnormal in 61% of the cases (erythromycin was used to stimulate gastric contractions) and, finally, anorectal manometry was altered in 59% of the patients, including 17% with severe abnormalities (i.e., absence of a recto-anal inhibitory reflex and a decrease in resting tone and squeeze pressure). Notably, the authors showed that esophageal motor disorders have significant predicting value in terms of survival, home parenteral nutrition requirement and an inability to maintain sufficient oral feeding. Furthermore, small bowel manometry can help distinguish a neuropathic versus a myopathic CIPO, as well as mechanical from functional forms of sub-occlusion, especially when the mechanical obstruction is at the beginning of its clinical manifestation. In the study by Lindberg *et al.* [28], small-bowel manometry showed similar abnormalities in the two groups of patients affected by CIPO and enteric dysmotility, but absence of a fed motor response to meals was seen in 16/43 patients with CIPO compared to none with enteric dysmotility. Sustained periods of uncoordinated phasic activity were more common in CIPO patients (23/45) than in enteric dysmotility patients (19/70) and severe hypomotility was only seen in seven patients with CIPO.

### Full-thickness biopsy

Finally, histopathology can be useful in CIPO patients based on the concept that tissue examination is the diagnostic gold standard in most (if not all) pathological conditions [29,30]. Gut full-thickness biopsies (taken from stomach, small bowel, colon) gained a renowned clinical interest thanks to the improvement of minimally invasive (laparoscopic) surgical approaches, even though this approach is not always possible in the abdomen of CIPO patients due to many previous abdominal surgical procedures. Biopsy samples should be processed for routine histology and immunohistochemistry because standard histology alone fails in almost a third of cases. Amiot *et al.* [29] described the immunohistochemical findings of 21 adult CIPO patients compared to 10 patients with mechanical obstruction and 27 controls. The study was carried out using standard histochemical staining and immunohistochemistry for muscular, nervous and mesenchymal (ICC) markers. Routine histology showed neuromuscular abnormalities in 62% of the patients, that is, myopathy in 43%, neuropathy in 9.5% and neuromyopathy in 9.5%. The results displayed hypoganglionosis in 29% of cases – four of them undiagnosed at standard histology – and a defect of ICCs in 48% – two of them with no histologic structural abnormality. Thus, immunohistochemistry (combined with the standard histology) detected abnormalities in 75% of patients with CIPO, while the remaining 25% showed an apparently normal histology, although in the absence of immunohistochemical tests for immune/inflammatory neuropathies/myopathies (with antibody targeting CD3, a pan-T-lymphocyte marker) [10,30]. A diagnostic algorithm for CIPO is shown in FIGURE 1.

### Münchhausen syndrome by proxy

A condition that should be considered in the differential diagnosis of pediatric CIPO is Münchhausen syndrome by proxy (MBP). This describes a behavior in which a caregiver deliberately induces physical, psychological, behavioral and/or mental health problems in those who are in their care [31–34]. Basically, MBP is a form of child abuse (very difficult to detect) with a reported mortality rate of nearly 10%. If MBP is suspected, prompt action should be taken with the help of psychiatrists and psychologists to separate the mother and child, in order to determine if the symptoms are legitimate or fabricated. It is important that MBP is ruled out in cases of CIPO when these children are evaluated for transplant, to prevent needless morbidity. Few cases have been reported since the first historical report by Todo and collaborators [31], but this differential diagnosis should be considered whenever a child with suspected CIPO is approached by a medical/surgical team.

### Medical management

The medical approach in CIPO is addressed to improve nutritional status, relieve symptoms due to dysmotility (e.g., nausea and vomiting), control abdominal pain, fight infections (with antibiotics) and treat secondary causes of the disease.

## Nutrition: enteral or parenteral & antibiotics for SIBO

### Enteral & parenteral nutrition

Patients with CIPO commonly have nutritional problems related to limited oral feeding because of severe digestive symptoms and/or impaired absorptive capacity. Thus, the nutritional support can be provided with either enteral nutrition or TPN [35–40]. The evaluation should be performed by a team of nutritional experts using laboratory tests to evaluate the intestinal absorptive function, paying attention to dietary history, anthropometric measures, weight and body mass index. Up to two-thirds of patients with CIPO develop nutritional problems or specific nutrient deficiency [19]. The nutritional integration strategy is aimed to improve the regular oral intake (by modifying the diet and related caloric intake); add dietary supplements; if patients continue to lose weight, then enteral nutrition, if tolerated, should be attempted as it reduces the risk of infectious processes due to SIBO and bacterial translocation. Finally, patients with frank whole intestinal insufficiency should be placed in TPN to maintain nutritional support and hydration. The infusion velocity should be set to give patients some time free of TPN (e.g., using overnight infusion) in the 24 h. Recent data indicate that the overall survival at 10 years of patients with CIPO is as high as 75% [35], thus attesting in favor of a careful TPN program in specialized referral centers. The need of TPN increases significantly between the preoperative and postoperative course, especially if more than one surgical procedure is needed [41], confirming the need to avoid unnecessary surgery. Complications of TPN include liver insufficiency, acute pancreatitis, glomerulonephritis and, in particular, catheter-related thrombosis and septicemia, all life-threatening conditions in any form of CIPO [42].

### Antibiotics

The rationale for the use of antibiotics is the treatment (and/or prevention) of SIBO resulting from intestinal stasis in CIPO patients. When SIBO occurs, patients develop diarrhea, which worsens malabsorption and weight loss. The most commonly used antibiotics include amoxicillin-clavulanate, metronidazole, ciprofloxacin and doxycycline administered in a rotating schedule (1 week each month in a long-term strategy, e.g., a 6-month period followed by 6 months without antibiotics). This therapeutic approach has been shown to improve the nutritional status and sometimes bloating [19]. Rifaximin, an unabsorbable antibiotic with no clinically relevant bacterial resistance, is becoming the treatment of choice for SIBO as shown in recent studies [43]. Notably, antibiotic treatment for SIBO may stop diarrhea but can evoke a reappearance of constipation leading to a worsening of CIPO symptoms.

### Motility agents: antiemetics & prokinetics

#### Antiemetics & prokinetics

Prokinetic drugs are directed to promote gastrointestinal propulsive activity, thereby improving oral feeding and reducing SIBO in patients with CIPO. Although not of proven efficacy, CIPO patients are often treated with erythromycin,

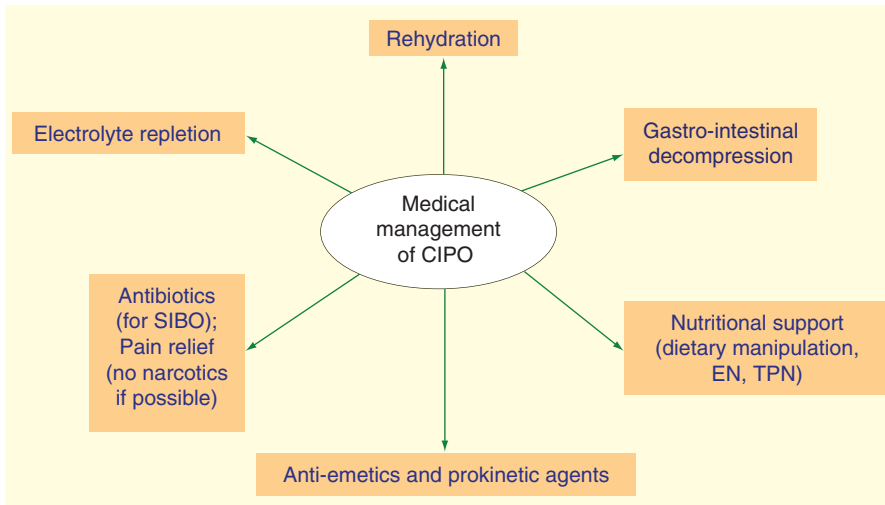
metoclopramide and domperidone (mainly useful as anti-emetic drugs), anticholinesterase drugs (e.g., neostigmine) and serotonergic agents: pyridostigmine, a cholinesterase inhibitor, was used on seven CIPO adult patients, initiated at 10 mg b.i.d. and increased if required; all treated patients had some improvement of symptoms with few side effects, and five of them reported a permanent effect [19,44–48]. Concerning serotonergic agents (cisapride being the most effective one, but withdrawn from the market since 1999 for major cardiac side effects), prucalopride, a full 5HT<sub>4</sub> receptor agonist, has been recently tested by Emmanuel *et al.* [46] in CIPO adult patients. Despite the limited sample size (only four patients completed the study, n = 3 with enteric myopathy and one with neuropathy), prucalopride significantly improved bloating in four, pain in three, nausea in two and vomiting in one patient. The positive effects resulted in a reduced analgesic intake, even though bowel function did not change substantially. Whether prucalopride might exert an analgesic effect remains an exciting possibility awaiting confirmatory evidence in CIPO. Other compounds, which have shown positive or negative results in isolated cases or small series, include prostaglandins, gonadotropin-releasing hormone analogs (leuprolide), somatostatin analogs (octreotide) and macrolides [8,9]. Octreotide (a long-acting somatostatin analog) has been used in patients with CIPO and scleroderma based on its prokinetic effect which occurs at 50–100 µg/day subcutaneously (i.e., a much lower dose than that inhibiting peptide secretion in neuroendocrine tumors). Octreotide significantly reduced nausea, vomiting, bloating and abdominal pain. Finally, erythromycin and its derivatives possess potent motilin receptor agonist activity and result in accelerating gastric emptying and probably enhancing fasting upper gut motility. Published experience showed efficacy of erythromycin in small case series. However, the role of erythromycin in CIPO is hampered by the occurrence of a rapid tachyphylaxis limiting its efficacy in the long-term treatment of CIPO patients [49]. It is advisable to use erythromycin in a rotating schedule, for example, 3 weeks followed by 1 week without the drug, then resuming the treatment again.

- Other therapeutic measures, such as gastric pacemaker, the use of Botox and alternative therapies (acupuncture) have been only empirically used in some cases of CIPO and therefore are beyond the objectives of this review.

### Pain relief: analgesics, nerve blockade & gastrointestinal decompression

#### Analgesic drugs

One of the main concerns reported by CIPO patients is given by chronic abdominal pain. The origin of this symptom in severe gut dysmotility remains largely obscure, although gut distension, spastic contraction, visceral hypersensitivity and CNS activation may all play an important role. Abdominal pain is managed empirically starting with paracetamol, going up with non-steroidal anti-inflammatory drugs/tricyclic antidepressants (at low doses in order to avoid the anticholinergic



**Figure 2. Medical management of chronic intestinal pseudo-obstruction.**

CIPO: Chronic intestinal pseudo-obstruction; EN: Enteral nutrition; SIBO: Small intestine bacterial overgrowth; TPN: Total parenteral nutrition.

effects) and ending with opiate-like/classic opiates in the most severe cases. Clearly, opioids should be very carefully used in CIPO patients. These drugs are dangerous as they can further impair neuromuscular activity, worsen gut propulsion and therefore perpetuate symptoms (including pain). They can induce dependence and even pain worsening (the now known opioid-induced enteroglial cell-mediated visceral hyperalgesia) over time [50]. Thus, pain control should be achieved using other drugs, for example, those for neuropathic pain. Nonetheless, transdermal buprenorphine, a partial  $\mu$ -opioid receptor agonist and a  $\kappa$ - and  $\delta$ -opioid receptor antagonist, at a dose of 5  $\mu\text{g}/\text{h}$  resulted in pain relief in four children with idiopathic CIPO [51]. Finally, more recent non-narcotic pain drugs, such as GABA analogs, serotonin-norepinephrine reuptake inhibitors have been employed with success.

### Nerve blockade

Celiac plexus blockade has been reported as an effective measure for longstanding pain control (up to 6 weeks) in neurosurgical adult patients in intensive care and may be useful in some selected patients with severe, opioid-resistant abdominal pain. Reported complications include hypotension, intravascular injection and retroperitoneal hematoma. Another approach to splanchnectomy has been successfully performed by thoracoscopy in two children affected by pain related to CIPO [20].

### Gastrointestinal decompression

Decompression of distended gastrointestinal segments by nasogastric or rectal tubes is helpful for many patients with CIPO and this may improve abdominal pain. The endoscopic approach may include a percutaneous endoscopic venting ostomy, very often placed in the stomach (gastrostomy), or via endoscopic percutaneous colostomy [52,53] successful in improving distension in adult patients with CIPO. FIGURE 2 summarizes medical management of CIPO.

### Surgical treatment

CIPO patients should not be referred to surgery, unless an emergency occurs or for carefully selected situations. There are few reports on adults and children and we will examine them separately in order to better understand the appropriate surgical management for each group of age. Transplantation will be evaluated in a separate paragraph.

### Surgery in adults

Surgery has a limited role in the management of CIPO, although few, extremely well-characterized cases may be eligible for a surgical bypass or resection of the dysfunctional gastrointestinal segment. A recent survey from Japan showed that most adult patients undergoing surgery for CIPO ( $n = 103$  cases) had a primary

form of disease (83%) and were significantly younger than those with a secondary form of disease [54]. The most affected gut segment was the large bowel in the majority of the cases (58%) and the predominant symptoms were characterized by abdominal distension, pain and constipation. Notably, those patients with a predominant large bowel involvement were those with a better outcome as compared with patients with a more diffuse gastrointestinal (i.e., small and large bowel) involvement. The prognosis of primary CIPO was significantly better than that of the secondary CIPO ( $p = 0.033$ ). The type of surgery to be applied on CIPO patients is questionable [55–61]: Lapointe [55] described eight cases of subtotal enterectomy (median remnant small bowel length of 28 cm), restoring in all cases intestinal continuity with large bowel. Two patients needed a second operation because of recurrent symptoms, but overall they increased oral intake and decreased TPN dependence. A larger surgical series, mainly about partial bowel resection, has been reported by Sabbagh *et al.* [41] on 63 patients (median age 37.1 years) operated for CIPO. In 45% of these cases, surgery was performed before the diagnosis was established, most patients had a primary form of CIPO (78%) and an underlying myopathy was detected in 41% of cases. Surgery (a total of 184 procedures) consisted of intestinal resection in 37% of cases, explorative laparotomy/scopy in 35%, terminal or venting ostomy in 13% and miscellaneous in 15% with a median number of procedures of 2.9 per patient. After a median follow-up of 6 years, the overall postoperative mortality rate was 7.9% while postoperative morbidity was 58.2%. Patients who underwent intestinal resection had a higher mortality rate, intraoperative small bowel injury rate and longer hospital stay than those subjected to conservative procedures. In a multivariate analysis, postoperative morbidity was significantly associated with intraoperative bowel injury, idiopathic CIPO and emergency procedure. Reoperation was a major issue in CIPO patients: the authors

reported re-operation one to nine times in approximately 68% of cases after the first procedure, with a median delay before re-operation of 1 year (and the probability increased with years). In a multivariate analysis, re-operation for CIPO was significantly increased when there was a major postoperative morbidity and intraoperative bowel injury after the first procedure. Nutritional autonomy in their surgical series was achieved by 52% of the patients with a median follow-up of 3.3 years: almost half of the cases did not have a regular oral intake, 68% of them were still depending on TPN with their median BMI significantly lower. The authors concluded that only few patients can benefit from a limited intestinal resection, being associated with higher postoperative morbidity and mortality rates. Finally, 'ostomies' (gastro- or entero-stomies) may be necessary in order to effectively relieve retching, vomiting and abdominal distension in CIPO patients.

### **Surgery in children**

The goal of surgical treatment in children affected by CIPO is different from adults: mortality rates of 10–32% before reaching adulthood have been reported with overall TPN-dependency of 62–74%, and consequently all the attempts should be performed in order to avoid a TPN-related liver disease by increasing the use of enteral feedings (if possible) through feeding jejunostomies. Since medical therapy often fails, the venting gastrostomies/jejunostomies or decompressing intestinal ostomies frequently used in children with CIPO represent major therapeutic options for symptom relief. Small intestinal resections are rigorously avoided in order to prevent development of intestinal failure-/TPN-associated liver disease and to maintain abdominal domain if intestinal transplantation become necessary. A report by Henyke *et al.* [62] described surgery on 44 patients treated for CIPO, the majority of them presenting the myopathic type congenitally. Thirty-two patients needed TPN for less than 6 months in 19 cases; 14 went then on enteral feeding. In 16 cases CIPO was associated with malrotation, in 10 with short bowel syndrome and in 16 with urinary tract involvement. The surgical procedures were mainly represented by intestinal decompression stomas (36 cases), but both venting colostomies and ileostomies relieved symptoms in the minority of the patients (colostomy 5 out of 11, ileostomy 16 out of 31). Death or TPN dependence affected most of the patients (14 and 10 cases, respectively) and myopathic histology associated with malrotation, short small bowel and urinary tract involvement had the worst prognosis. Another report by Pakarinen *et al.* [63] described a series of eight patients operated for CIPO, with a median follow-up of 19 years: six out of eight were TPN-dependent since birth. Overall, CIPO patients had 239 cm of median small bowel remaining length and six had most of the colon preserved with ileocecal valve. The surgical procedures were represented by an endoscopically placed gastrostomy (six patients), which was combined with a jejunostomy in one case. A permanent end-ostomy was performed in four after prolonged intolerance to enteral feedings despite optimized medical therapy. Two patients underwent colectomy but

without a clear-cut response. The median overall duration of TPN was 3.8 years: five CIPO cases weaned off TPN including one patient after intestinal transplantation (two were on the waiting list at the time of study), and all patients survived in their report. In conclusion, surgery for CIPO in children is devoted to relieve symptoms and minimize complications related to TPN.

### **Transplantation**

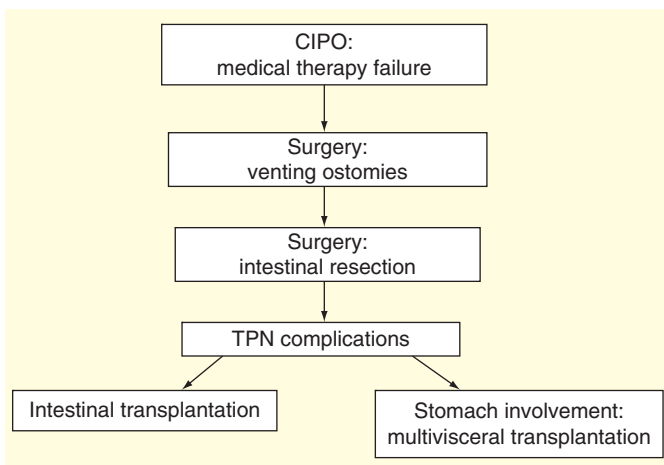
Over the last 20 years, intestinal transplantation has emerged as a therapeutic option for patients affected by TPN-related complications: under this point of view, a complicated course of CIPO (i.e., failure of medical and/or surgical treatment in a CIPO patient with TPN-related complications) should be considered an indication for intestinal or multivisceral (stomach-duodenum-pancreas plus small bowel) transplantation depending on the extension of gut dysfunction. An alternative is given by intestinal transplantation with surgical manipulation of the stomach. The results of isolated intestinal or modified multivisceral transplantation are different based on the age of the recipients and even in this case we will discuss separately the two types of transplantations [64–80].

### **Candidacy to transplant**

The first step is to evaluate whether a patient affected by CIPO is candidable to transplantation. Concerning children with severe dysmotility, a national survey of 302 institutions has been recently performed in Japan by Ueno *et al.* [64]. This study identified 147 patients (mean patient age 12.1 years, mean age of onset 3 years) treated in 46 institutions from 2006 to 2011. Most of the cases were represented by CIPO (96 patients including those with Hirschsprung's disease and megacystis microcolon intestinal hypoperistalsis syndrome). In this series, the mortality rate was 14.3% (21 patients), while among 126 survivors, 85% had irreversible intestinal failure, eventually developing hepatic failure with jaundice (9.4%) and two or more central vein thromboses (31.8%). Specifically, those patients developing irreversible intestinal failure – due to severe intestinal dysmotility – and considered candidates for transplantation were 41%, a higher percentage than the previously reported ones ranging 20–25% [65,66]. Recently, Pironi *et al.* [67], analyzing the data of adult and pediatric TPN patients, reported that only desmoids and TPN-related liver failure represent indications for life-saving intestinal transplantation, while catheter-related complications and ultra-short bowel might be indications for pre-emptive/rehabilitative transplant.

### **Transplant in adults-isolated bowel**

Recently, Lauro *et al.* [18,68,69] reported 11 intestinal/multivisceral transplantations for CIPO on 10 recipients (mean age at transplant: 33 years; mean TPN duration: 4.7 years). Nine patients underwent isolated intestinal transplantation. At the time of the study, six patients (60%) were alive and with nutritional autonomy, apart from one case on TPN plus oral



**Figure 3. Surgical therapeutic algorithm for chronic intestinal pseudo-obstruction.**

CIPO: Chronic intestinal pseudo-obstruction; TPN: Total parenteral nutrition.

feeding. Mortality was due to infections occurred in the four remaining cases. Considering the nine isolated intestinal transplants, the native gastro-duodenal block affected by CIPO was surgically treated by performing a gastric-jejunostomy in seven recipients (combined with a duodenojejunostomy and/or a subtotal gastrectomy), whereas two cases had duodenojejunostomy. Apart from one case, the distal graft was anastomosed to the native bowel in all CIPO patients. In two cases with persistent episodes of intestinal sub-occlusion, an ileostomy was performed after transplantation in order to improve intestinal function and decompression. Survival after transplant for CIPO in the Lauro *et al.* series was similar to that published for short bowel syndrome, thus the presence of native stomach (involved in CIPO) did not represent a contraindication to isolated intestinal transplantation and to the achievement of nutritional autonomy.

#### **Transplant in adults-multivisceral graft**

Cruz *et al.* from Pittsburgh group [70] reported 36 modified multivisceral grafts mainly given to an adult population (30 adults). Leading causes of intestinal failure were CIPO together with Gardner's syndrome: the graft used by the authors included stomach, duodenum, pancreas and intestine. Patient survival was 75% at 5 years with mean follow-up of 51 months, full nutritional autonomy was achieved in 89% of recipients at the time of study. Multivisceral transplant in adults is a complex surgical procedure performed in few centers worldwide and it has different results depending upon the experience of the referral center [71].

#### **Transplant in children-isolated or liver-bowel graft**

TPN-related liver failure is very frequent in children and often there is the need for combined bowel (for CIPO) and liver (for failure) transplant. It is remarkable to report the historical series, for example, by Iyer *et al.* or other authors [72,73],

regarding intestinal transplant without stomach or colon in pediatric patients affected by CIPO. Iyer *et al.* reported [72] six small bowel and three liver-small bowel transplants in eight recipients (median age at transplantation 2.7 years) between 1993 and 1999. After a median follow-up of 40 months, they described five survivors with functioning grafts receiving full home enteral feedings. Notably, four out of five had ileostomies closed and three had normal bowel movements. The median graft survival in this series was 15 months, where two children died and two graft losses occurred in one patient. Their conclusion was that intestinal transplantation without stomach or colon provides children with CIPO with a good quality of life. More recently, the United Network for Organ Sharing data in children, reported by Lao *et al.* [74] demonstrated a 5-year survival rate of 57% for patients transplanted for various disorders (e.g., Hirschsprung's disease, microvillus inclusion disease, neuronal intestinal dysplasia, protein-losing enteropathy, myopathic pseudo-obstruction, neuropathic pseudo-obstruction). These rates are comparable to the overall survival rates for intestinal transplant. Infectious and opportunistic complications were seen at similar rates between patients with CIPO and those with other indications for transplant.

#### **Transplant in children-multivisceral graft**

As in adults, multivisceral transplantation in children is a difficult surgical task. Loinaz *et al.* [76] reported 17 multivisceral transplants (one re-transplantation) on 16 children (median age: 4 years) with CIPO. The graft included stomach, pancreatic-duodenal complex and small intestine, adding liver or kidney when there was liver disease or renal failure. Patient survival at 2 years for periods I (1996–2000) and II (2001 study) – different immunosuppressive strategies were used in the considered periods – was 42.9 and 77.8%, respectively: none of the long-term survivors was on TPN and all tolerated enteral feedings. Remarkably, bladder function did not improve among CIPO patients with large dilated bladders before transplant (continuing to require bladder catheterization, see section 'Urological disorders & transplant in CIPO recipients'). FIGURE 3 summarizes the surgical/transplantation algorithm reported in this review.

#### **Urological disorders & transplant in CIPO recipients**

An internal review of medical records reported by Akhavan *et al.* [81] analyzed 175 consecutive adult intestinal recipients transplanted for different diseases including CIPO: a 25% overall incidence of urinary complications was reported including 53 urogenital disorders in 43 recipients, 56% had the disorder before referral and 44% who developed urological disorders after transplant. In addition to general pre-transplant screening, patients with CIPO should be evaluated for urological abnormalities such as megacystis and vesicoureteral reflux, which may occur in more than 33% of patients, requiring antibiotic prophylaxis to prevent infections [82]. The transplant procedure does not solve the neuromuscular involvement affecting organs other than the gastrointestinal tract and the



possibility of intermittent bladder catheterization after the transplant must be clearly explained to CIPO patients, candidate to transplantation.

### Recent therapeutic advancements in selected types of CIPO

#### **Mitochondrial neurogastrointestinal encephalomyopathy**

MNGIE is a rare autosomal recessive mitochondrial disease associated with mutations in the nuclear *TYMP* gene. As a result, the thymidine phosphorylase (TP) enzyme activity is markedly reduced leading to toxic accumulation of thymidine and therefore altered mitochondrial DNA. MNGIE is characterized by severe gastrointestinal dysmotility, neurological impairment, reduced life expectancy and poor quality of life. There are limited therapeutic options for MNGIE. In the attempt to restore TP activity, allogenic hematopoietic stem cell transplantation has been used as cellular source of TP [83]. The results of this approach on 20 MNGIE patients showed gastrointestinal and neurological improvement, although the 5-year mortality rate is about 70%. Boschetti *et al.* [84] investigated normal liver tissue obtained from 11 adult patients (who underwent hepatic resection for focal disorders), in order to identify, quantify and localize the TP protein and to evaluate *TYMP* mRNA expression in the liver. TP was identified in both nuclei and cytoplasm of hepatocytes and sinusoidal lining cells and *TYMP* mRNA was expressed in the liver as well, demonstrating that the liver is an important source of TP and suggesting orthotopic liver transplantation as a therapeutic alternative for MNGIE patients.

#### **Paraneoplastic neurologic syndromes**

Paraneoplastic neurologic syndromes are uncommon, affecting fewer than 1 in 10,000 patients with cancer and sometimes associated with autoimmune diseases. There is significant evidence that paraneoplastic neurologic syndromes are associated with antibodies generated by antigens co-expressed by tumor cells and neurons (e.g., anti-neuronal nuclear antibody 1 or anti-Hu antibodies). Badari *et al.* successfully treated [85] a patient with CIPO in the setting of small cell lung cancer with a combination of rituximab and cyclophosphamide: the patient, who failed to respond to prokinetic agents, anti-secretory therapy and multiple resections, responded to the immunomodulatory therapy with good outcome in terms of gastrointestinal manifestations (e.g., minimal residuals in gastrostomy tube feeding).

### Prognosis

A benign course of CIPO depends upon the possibility to maintain the oral (enteral) feeding often supported by TPN and, if irreversible complications occur, intestinal/multivisceral transplantation should be considered. Studying 51 adult CIPO patients on TPN, Amiot *et al.* showed [35] an actuarial survival probability of 94, 78, 75 and 68% at 1, 5, 10 and 15 years, respectively. The authors showed a decreased mortality rate in the case of ability to restore oral feeding at baseline and in the

case with symptom occurrence before the age of 20 years. In contrast, an increased mortality rate was observed in the case of systemic sclerosis. Actuarial TPN dependence was 94, 75 and 72% at 1, 2 and 5 years, respectively. These findings should be taken into account when considering long-term results of intestinal/multivisceral transplantation [71]. Thus, it is important to point out that the transplant procedure should be reserved only for CIPO patients with a complicated TPN course.

### Expert commentary

CIPO is a rare, disabling syndrome frequently misdiagnosed and often associated with a poor outcome. CIPO diagnosis should be based on clinical features, radiologic findings as well as on other approaches, that is, the non-invasive cine-MR but also with minimally invasive techniques to obtain full-thickness biopsies (nowadays possible even with natural orifice transluminal endoscopic surgery and other modern endoscopic tools). Histopathological analysis of gut biopsies may disclose underlying neuro-ICC-muscular abnormalities. Despite important achievements obtained in CIPO knowledge and management, therapeutic options for CIPO are still quite disappointing, being based on few truly effective pharmacologic remedies. Thus, nutritional support is still of paramount importance in the management of CIPO patients. Other important strategies pertain to minimizing SIBO, a common complication due to the stasis of intestinal contents, and abdominal pain control. Underlying causes of secondary CIPO should be thoroughly investigated and, if detected, treated accordingly. As addressed in this review, surgery should be indicated only in a well-characterized subgroup of patients. Although showing a trend toward improvement in terms of survival rate, isolated intestinal or multivisceral transplantation should be indicated in patients with intestinal failure with clear complication due to TPN.

### Five-year view

CIPO is a rare and severe condition that occurs as a result of a marked impairment of gut propulsive motility mimicking a mechanical obstruction, without any demonstrable mechanical cause through the gastrointestinal tract. Although still a challenge for most clinicians and surgeons, the future of CIPO may be more positive than one would expect thanks to a number of important achievements. First, less invasive diagnostic tests, such as cine-MRI and novel endoscopic approaches for full-thickness biopsy sampling shed light on better identification and characterization of CIPO patients. Second, a consensus has been reached for a classification of enteric neuro-ICC-myopathies as well as guidelines for tissue processing and analysis for tissues obtained from patients with severe dysmotility disorders. Third, genetic tests and biomolecular analysis are going to unravel abnormalities in important pathways leading to nerve, muscle and ICC degeneration and/or dysfunction. This will be of strategic relevance to better understand the heterogeneity of CIPO cases and, on the other hand, address targeted, more personalized and effective therapies. Also, a wide

array of prokinetic agents is in the pharma pipeline ready to be tested in clinical trials. Fourth, surgery and especially intestinal transplantation are improving a lot as witnessed by the numerous data so far published and indicating a progressive increase of post-transplant survival rate. In conclusion, the advancements achieved so far and those expected in the next years will shed light on patients with CIPO and related management.

#### Financial & competing interests disclosure

*The authors have no relevant affiliations or financial involvement with any organization or entity with a financial interest in or financial conflict with the subject matter or materials discussed in the manuscript. This includes employment, consultancies, honoraria, stock ownership or options, expert testimony, grants or patents received or pending or royalties.*

*No writing assistance was utilized in the production of this manuscript.*

#### Key issues

- Chronic intestinal pseudo-obstruction (CIPO) is the tip of the iceberg of severe gut functional disorders.
- Based on its rarity in the clinical arena, CIPO is usually a challenge, often misdiagnosed.
- CIPO can be either idiopathic in origin or secondary to a wide array of diseases; the distinction between idiopathic and secondary cases is of crucial importance for treatment purposes.
- Gastrointestinal neuro-interstitial cells of Cajal-myopathies can represent a histopathological correlate of patients with CIPO.
- Diagnosis is essentially clinical (i.e., recurrent episodes of sub-occlusion) and confirmed by tests ruling out mechanical causes. Radiological techniques and now modern endoscopic approaches (providing full-thickness tissue biopsies) are crucial steps in the diagnostic work-up.
- Other emerging, non-invasive techniques are extremely interesting and provide optimism on future management of this rare condition.
- Nutritional support is the mainstay of CIPO clinical management.
- Medical treatment is still limited to few 'ready-on-the market' prokinetics agents, but the future is promising with many different types of molecules in the pipeline for clinical trials.
- Antinociceptive treatment as well as antibiotics to control abdominal pain and SIBO, respectively, is also mandatory in most cases.
- Futile, harmful laparotomies should be avoided, while elective surgery should be indicated in well-characterized cases; recurrent complications of total parenteral nutrition represent an indication to intestinal/multivisceral transplantation in pediatric and adult CIPO.

#### References

Papers of special note have been highlighted as:

- of interest
  - of considerable interest
1. Dudley HA, Sinclair IS, McLaren IF, et al. Intestinal pseudo-obstruction. *J R Coll Surg Edinb* 1958;3:206-17
  2. Ohkubo H, Iida H, Takahashi H, et al. An epidemiologic survey of chronic intestinal pseudo-obstruction and evaluation of the newly proposed diagnostic criteria. *Digestion* 2012;86:12-19
  3. Iida H, Ohkubo H, Inamori M, et al. Epidemiology and clinical experience of chronic intestinal pseudo-obstruction in Japan: a nationwide epidemiologic survey. *J Epidemiol* 2013;23:288-94
  4. Stanghellini V, Cogliandro RF, De Giorgio R, et al. Natural history of chronic idiopathic intestinal pseudo-obstruction in adults: a single center study. *Clin Gastroenterol Hepatol* 2005;3:449-58
  5. Ahlfors F, Linander H, Lindström M, et al. Familial intestinal degenerative neuropathy associated with chronic intestinal pseudo-obstruction. *Neurogastroenterol Motil* 2011;23:347-56
  6. Rubenstein PA, Mayer EA. Familial visceral myopathies: from symptom-based syndromes to actin-related diseases. *Gastroenterology* 2012;143:1420-3
  7. De Giorgio R, Sarnelli G, Corinaldesi R, Stanghellini V. Advances in our understanding of the pathology of chronic intestinal pseudo-obstruction. *Gut* 2004;53:1549-52
  8. Stanghellini V, Cogliandro RF, De Giorgio R, et al. Chronic intestinal pseudo-obstruction: manifestations, natural history and management. *Neurogastroenterol Motil* 2007;19:440-52
  9. De Giorgio R, Cogliandro RF, Barbara G, et al. Chronic intestinal pseudo-obstruction: clinical features, diagnosis, and therapy. *Gastroenterol Clin North Am* 2011;40:787-807
  10. Knowles CH, De Giorgio R, Kapur RP, et al. The London classification of gastrointestinal neuromuscular pathology: report on behalf of the Gastro 2009 International Working Group. *Gut* 2010;59:882-7
  11. Selgrad M, De Giorgio R, Fini L, et al. JC virus infects the enteric glia of patients with chronic idiopathic intestinal pseudo-obstruction. *Gut* 2009;58:25-32
  12. Ooms AH, Verheij J, Hulst JM, et al. Eosinophilic myenteric ganglionitis as a cause of chronic intestinal pseudo-obstruction. *Virchows Arch* 2012;460:123-7
  13. Osinga TE, Kerstens MN, van der Klauw MM, et al. Intestinal pseudo-obstruction as a complication of paragangliomas: case report and literature review. *Neth J Med* 2013;71:512-17
  14. Zapatier JA, Ukleja A. Intestinal obstruction and pseudo-obstruction in patients with systemic sclerosis. *Acta Gastroenterol Latinoam* 2013;43:227-30
  15. Caio G, Volta U, Cerrato E, et al. Detection of anticonductive tissue autoantibodies in a patient with chronic intestinal pseudo-obstruction and sick sinus syndrome. *Eur J Gastroenterol Hepatol* 2013;25:1358-63
  16. Khairullah S, Jasmin R, Yahya F, et al. Chronic intestinal pseudo-obstruction: a rare first manifestation of systemic lupus erythematosus. *Lupus* 2013;22:957-60
  17. Debinski HS, Kamm MA, Talbot IC, et al. DNA viruses in the pathogenesis of sporadic
- **Defines the classification of gastrointestinal neuromuscular pathologies based on histopathological criteria.**

- chronic idiopathic intestinal pseudo-obstruction. *Gut* 1997;41:100-6
18. Lauro A, Zanfi C, Pellegrini S, et al. Isolated intestinal transplant for chronic intestinal pseudo-obstruction in adults: long-term outcome. *Transplant Proc* 2013;45:3351-5
  19. Gabbard SL, Lacy BE. Chronic intestinal pseudo-obstruction. *Nutr Clin Pract* 2013;28:307-17
  20. Di Lorenzo C, Youssef NN. Diagnosis and management of intestinal motility disorders. *Semin Pediatr Surg* 2010;19:50-8
  21. Muñoz-Yagüe MT, Solís-Muñoz P, Salces I, et al. Chronic intestinal pseudo-obstruction: a diagnosis to be considered. *Rev Esp Enferm Dig* 2009;101:336-42
  22. Knowles CH, Lindberg G, Panza E, De Giorgio R. New perspectives in the diagnosis and management of enteric neuropathies. *Nat Rev Gastroenterol Hepatol* 2013;10:206-18
  23. Cogliandro RF, Antonucci A, De Giorgio R, et al. Patient-reported outcomes and gut dysmotility in functional gastrointestinal disorders. *Neurogastroenterol Motil* 2011;23:1084-94
  24. Ohkubo H, Kessoku T, Fuyuki A, et al. Assessment of small bowel motility in patients with chronic intestinal pseudo-obstruction using cine-MRI. *Am J Gastroenterol* 2013;108:1130-9
  25. Sumiyama K, Gostout CJ. Clinical applications of submucosal endoscopy. *Curr Opin Gastroenterol* 2011;27:412-17
  26. De Giorgio R, Guerrini S, Barbara G, et al. Inflammatory neuropathies of the enteric nervous system. *Gastroenterology* 2004;126:1872-83
  27. Amiot A, Joly F, Cazals-Hatem D, et al. Prognostic yield of esophageal manometry in chronic intestinal pseudo-obstruction: a retrospective cohort of 116 adult patients. *Neurogastroenterol Motil* 2012;24:1008-16
  28. Lindberg G, Iwarzon M, Tornblom H. Clinical features and long-term survival in chronic intestinal pseudo-obstruction and enteric dysmotility. *Scand J Gastroenterol* 2009;44:692-9
  29. Amiot A, Cazals-Hatem D, Joly F, et al. The role of immunohistochemistry in idiopathic chronic intestinal pseudo-obstruction (CIPO) - a case-control study. *Am J Surg Pathol* 2009;33:749-58
  - **Defines the role of immunohistochemistry in chronic intestinal pseudo-obstruction (CIPO) reporting the study performed in a single center.**
  30. Lindberg G, Törnblom H, Iwarzon M, et al. Full-thickness biopsy findings in chronic intestinal pseudo-obstruction and enteric dysmotility. *Gut* 2009;58:1084-90
  31. Kosmach B, Tarbell S, Reyes J, Todo S. Munchausen by proxy syndrome in a small bowel transplant recipient. *Transplant Proc* 1996;28:2790-1
  32. Jacobi G, Dettmeyer R, Banaschak S, et al. Child Abuse and Neglect: diagnosis and Management. *Dtsch Arztebl Int* 2010;107:231-40
  33. Meadow R. What is, and what is not, 'Munchausen syndrome by proxy'? *Arch Dis Child* 1995;72:534-8
  34. Stirling J Jr; the Committee on Child Abuse and Neglect. Beyond Munchausen syndrome by proxy: identification and treatment of child abuse in a medical setting. *Pediatrics* 2007;119:1026-30
  35. Amiot A, Joly F, Alves A, et al. Long-term outcome of chronic intestinal pseudo-obstruction adult patients requiring home parenteral nutrition. *Am J Gastroenterol* 2009;104:1262-70
  - **Excellent report on outcome of CIPO patients on total parenteral nutrition from a single institution.**
  36. Lacy BE, Loew BJ. Diagnosis, treatment and nutritional management of chronic intestinal pseudo-obstruction. *Pract Gastroenterol* 2009;8:9-24
  37. Stanghellini V, Cogliandro RF, De Giorgio R, et al. Natural history of intestinal failure induced by chronic idiopathic intestinal pseudo-obstruction. *Transplant Proc* 2010;42:15-18
  38. Cucchiara S, Borrelli O. Nutritional challenge in pseudo-obstruction: the bridge between motility and nutrition. *J Pediatr Gastroenterol Nutr* 2009;48:S83-5
  39. Benjamin J, Singh N, Makharia GK. Enteral nutrition for severe malnutrition in chronic intestinal pseudo-obstruction. *Nutrition* 2010;26:502-5
  40. Mueller C, Compher C, Druyan ME; the American Society for Parenteral and Enteral Nutrition (A.S.P.E.N.) Board of Directors. A.S.P.E.N. clinical guidelines nutrition screening, assessment, and intervention in adults. *J PEN J Parenter Enteral Nutr* 2011;35:16-24
  41. Sabbagh C, Amiot A, Maggiori L, et al. Non-transplantation surgical approach for chronic intestinal pseudo-obstruction: analysis of 63 adult consecutive cases. *Neurogastroenterol Motil* 2013;25:680-6
  - **Defines the surgical options in complicated CIPO cases.**
  42. Pironi L, Spinucci G, Paganelli F, et al. Italian guidelines for intestinal transplantation: potential candidates among the adult patients managed by a medical referral center for chronic intestinal failure. *Transplant Proc* 2004;36:659-61
  43. Pimentel M. Review of rifaximin as treatment for SIBO and IBS. *Expert Opin Investig Drugs* 2009;18:349-58
  44. O'Dea CJ, Brookes SJ, Warrchow DA. The efficacy of treatment of patients with severe constipation or recurrent pseudo-obstruction with pyridostigmine. *Colorectal Dis* 2010;12:540-8
  45. Rao AS, Camilleri M. Review article: metoclopramide and tardive dyskinesia. *Aliment Pharmacol Ther* 2010;31:11-19
  46. Emmanuel AV, Kamm MA, Roy AJ, et al. Randomised clinical trial: the efficacy of prucalopride in patients with chronic intestinal pseudo-obstruction - a double-blind, placebo-controlled, cross-over, multiple n = 1 study. *Aliment Pharmacol Ther* 2012;35:48-55
  47. Lacy BE, Chey WD. Lubiprostone: chronic constipation and irritable bowel syndrome with constipation. *Expert Opin Pharmacother* 2009;10:143-52
  48. Lacy BE, Levenick JM, Crowell MD. Linacotide in the management of gastrointestinal tract disorders. *Drugs Today (Barc)* 2012;48:197-206
  49. Emmanuel AV, Shand AG, Kamm MA. Erythromycin for the treatment of chronic intestinal pseudo-obstruction: description of six cases with a positive response. *Aliment Pharmacol Ther* 2004;19:687-94
  50. Brush DE. Complications of long-term opioid therapy for management of chronic pain: the paradox of opioid-induced hyperalgesia. *J Med Toxicol* 2012;8:387-92
  51. Prapaitrakool S, Hollmann MW, Wartenberg HC, et al. Use of buprenorphine in children with chronic pseudoobstruction syndrome: case series and review of literature. *Clin J Pain* 2012;28:722-5
  52. Thompson AR, Pearson T, Ellul J, Simson JN. Percutaneous endoscopic colostomy in patients with chronic intestinal pseudo-obstruction. *Gastrointest Endosc* 2004;59:113-15
  53. Kim JS, Lee BI, Kim BW, et al. Repetitive colonoscopic decompression as a bridge

- therapy before surgery in a pregnant patient with chronic intestinal pseudo-obstruction. *Clin Endosc* 2013;46:591-4
54. Masaki T, Sugihara K, Nakajima A, Muto T. Nationwide survey on adult type chronic intestinal pseudo-obstruction in surgical institutions in Japan. *Surg Today* 2012;42:264-71
  55. Lapointe R. Chronic idiopathic intestinal pseudo-obstruction treated by near total small bowel resection: a 20-year experience. *Gastrointest Surg* 2010;14:1937-42
  56. Mughal MM, Irving MH. Treatment of end stage chronic intestinal pseudo-obstruction by subtotal enterectomy and home parenteral nutrition. *Gut* 1988;29:1613-17
  57. Noel RF Jr, Schuffler MD, Helton WS. Small bowel resection for relief of chronic intestinal pseudo-obstruction. *Am J Gastroenterol* 1995;90:1142-5
  58. Murr MM, Sarr MG, Camilleri M. The surgeon's role in the treatment of chronic intestinal pseudo-obstruction. *Am J Gastroenterol* 1995;90:2147-51
  59. Shibata C, Naito H, Funayama Y, et al. Surgical treatment of chronic intestinal pseudo-obstruction: report of three cases. *Surg Today* 2003;33:58-61
  60. Granero Castro P, Fernández Arias S, Moreno Gijón M, et al. Emergency surgery in chronic intestinal pseudo-obstruction due to mitochondrial neurogastrointestinal encephalomyopathy: case reports. *Int Arch Med* 2010;3:35-9
  61. Lee BH, Kim N, Kang SB, et al. Two cases of chronic idiopathic intestinal pseudo-obstruction with different clinical features. *J Neurogastroenterol Motil* 2010;16:83-9
  62. Heneyke S, Smith VV, Spitz L, Milla PJ. Chronic intestinal pseudo-obstruction: treatment and long term follow up of 44 patients. *Arch Dis Child* 1999;81:21-7
  63. Pakarinen MP, Kurvinen A, Koivusalo AI, et al. Surgical treatment and outcomes of severe pediatric intestinal motility disorders requiring parenteral nutrition. *J Pediatr Surg* 2013;48:333-8
  64. Ueno T, Wada M, Hoshino K, et al. A national survey of patients with intestinal motility disorders who are potential candidates for intestinal transplantation in Japan. *Transplant Proc* 2013;45:2029-31
  65. Gambarara M, Knafelz D, Diamanti A, et al. Indication for small bowel transplant in patients affected by chronic intestinal pseudo-obstruction. *Transplant Proc* 2002;34:866-7
  66. Goulet O, Jobert-Giraud A, Michel JL, et al. Chronic intestinal pseudo-obstruction syndrome in pediatric patients. *Eur J Pediatr Surg* 1999;9:83-9
  67. Pironi L, Joly F, Forbes A, et al. Long-term follow-up of patients on home parenteral nutrition in Europe: implications for intestinal transplantation. *Gut* 2011;60:17-25
  - **Defines the indication for intestinal transplantation through a European survey.**
  68. Lauro A, Zanfi C, Dazzi A, et al. Disease-related intestinal transplant in adults: results from a single center. *Transplant Proc* 2014;46:245-8
  69. Masetti M, Di Benedetto F, Cautero N, et al. Intestinal transplantation for chronic intestinal pseudo-obstruction in adult patients. *Am J Transplant* 2004;4:826-9
  70. Cruz RJ Jr, Costa G, Bond G, et al. Modified liver-sparing multivisceral transplant with preserved native spleen, pancreas, and duodenum: technique and long-term outcome. *J Gastrointest Surg* 2010;14:1709-21
  71. Grant D, Abu-Elmagd K, Reyes J, et al. 2003 report of the intestine transplant registry: a new era has dawned. *Ann Surg* 2005;241:607-13
  72. Iyer K, Kaufman S, Sudan D, et al. Long-term results of intestinal transplantation for pseudo-obstruction in children. *J Pediatr Surg* 2001;36:174-7
  73. Sigurdsson L, Reyes J, Kocoshis SA, et al. Intestinal transplantation in children with chronic intestinal pseudo-obstruction. *Gut* 1999;45:570-4
  74. Lao OB, Healey PJ, Perkins JD, et al. Outcomes in children after intestinal transplant. *Pediatrics* 2010;125:550-8
  75. Millar AJ, Gupte G, Sharif K. Intestinal transplantation for motility disorders. *Semin Pediatr Surg* 2009;18:258-62
  76. Loinaz C, Mittal N, Kato T, et al. Multivisceral transplantation for pediatric intestinal pseudo-obstruction: single center's experience of 16 cases. *Transplant Proc* 2004;36:312-13
  77. Vianna RM, Mangus RS, Fridell JA, et al. Initiation of an intestinal transplant program: the Indiana experience. *Transplantation* 2008;85:1784-9
  78. Abu-Elmagd KM, Costa G, Bond GJ, et al. Five hundred intestinal and multivisceral transplantations at a single center: major advances with new challenges. *Ann Surg* 2009;250:567-81
  79. Pironi L, Baxter JP, Lauro A, et al. Assessment of quality of life on home parenteral nutrition and after intestinal transplantation using treatment-specific questionnaires. *Am J Transplant* 2012;12:60-6
  80. Abu-Elmagd KM, Kosmach-Park B, Costa G, et al. Long-term survival, nutritional autonomy, and quality of life after intestinal and multivisceral transplantation. *Ann Surg* 2012;256:494-508
  - **Excellent report from a single center on intestinal and multivisceral transplantation by the first group worldwide.**
  81. Akhavan A, Jackman SV, Costa G, et al. Urogenital disorders associated with gut failure and intestinal transplantation. *J Urol* 2007;178:2067-72
  82. Bond GJ, Reyes JD. Intestinal transplantation for total/near-total aganglionosis and intestinal pseudo-obstruction. *Semin Pediatr Surg* 2004;13:286-92
  83. Halter J, Schüpbach WM, Casali C, et al. Allogeneic hematopoietic SCT as treatment option for patients with mitochondrial neurogastrointestinal encephalomyopathy (MNGIE): a consensus conference proposal for a standardized approach. *Bone Marrow Transplant* 2011;46:330-7
  84. Boschetti E, D'Alessandro R, Bianco F, et al. Liver as a source for thymidine phosphorylase replacement in mitochondrial neurogastrointestinal encephalomyopathy. *PLoS One* 2014;9(5):e96692
  85. Badari A, Farolino D, Nasser E, et al. A novel approach to paraneoplastic intestinal pseudo-obstruction. *Support Care Cancer* 2012;20:425-8