



Metastatic Renal Cell Carcinoma Invading Liver, Duodenum and IVC, Surgical Treatment and Literature Review: A Case Report

Bellato V^{1*}, Caronna R¹, Mazzesi G², Tritapepe L³, Serrao G¹, Lancellotti F¹, Cicconi S¹, Saullo P¹, Muttillio EM¹, Valle G¹ and Chirletti P¹

¹Department of Surgical Sciences, Umberto I Hospital, Italy

²Department of General and Specialist Surgery, Sapienza University of Rome, Italy

³Department of Anesthesiology and Intensive Care Medicine, Sapienza University of Rome, Italy

Abstract

Renal Cell Carcinoma has a biologic predisposition for direct vascular invasion: intravascular tumor thrombus is found in 5% to 20% of the cases inside the renal vein or the inferior vena cava. Despite new and effective conservative therapy such as targeted therapy and immunotherapy, cytoreductive nephrectomy and palliative nephrectomy continues to have an important role in T4 patient. The patient selection for cytoreductive nephrectomy should be done carefully.

This report present an unique case of metastatic RCC with invasion of the duodenum, liver and retrohepatic IVC, the adopted surgical approach and a review of the literature.

Complete surgical extirpation is possible in cases of RCC invading other organs such as pancreas, duodenum, liver, retroperitoneum and IVC. In this scenario, to narrow the possible intraoperative complication, a multidisciplinary approach and equipe is recommended.

Introduction

Renal Cell Carcinoma represents 2% to 3% of all cancers, with the highest incidences occurring in western countries. In the last two decades there has been an annual increase of approximately 2% in incidence both worldwide and in Europe with approximately 84.400 new RCC cases and 34.700 kidney cancer related deaths within the European Union in 2012 [1].

RCC has a biologic predisposition for direct vascular invasion: Intravascular tumor thrombus was found in 5% to 20% of the cases inside the renal vein or the inferior vena cava [2].

Although uncommon, metastatic renal cell carcinoma to the duodenum has been described; however, direct invasion from the kidney into the duodenum has been reported only in two studies [3,4]. Furthermore, there has been only one case report of renal cell carcinoma invading both the duodenum and Inferior Vena Cava (IVC) [5].

This report presents a unique case of RCC with invasion of the duodenum, liver and retro hepatic IVC and the adopted surgical approach.

Case Presentation

A 61 year-old Caucasian male with past medical history of hypertension, hypercholesterolemia and acute ischemic heart disease treated with double Aorto-coronary bypass in 2004, presented with right flank pain of 3 months duration. His physical exam showed a clearly palpable abdominal mass noted from the right subcostal region to 10 cm above the iliac crest. The laboratory works were significant for hemoglobin of 8 g/dL, for which he received a transfusion of 2 units of packed red blood and creatinine of 1, 2 mg/dL. A EUS shows a renal mass of 8 cm × 9 cm. The suprarenal IVC was occupied by a thrombus that protruded above the margin of the IV hepatic segment. A CT scan shows: Voluminous mass of the right kidney (12 cm × 9 cm × 8 cm), this formation infiltrated the parenchyma with focal alteration of about 35 mm at the level of the VI segment, (Figure 1) it also makes anterior contact with the head of the pancreas and with the second duodenal portion compared to which it does not show a secure cleavage plan (Figure 2). The right renal vein was thrombosed and infiltrated by the neoformated process, with extrinsecation also involving the

OPEN ACCESS

*Correspondence:

Bellato Vittoria, Department of Surgical Sciences, Umberto I Hospital, Viale del Policlinico 155, 00161 Rome, Italy, E-mail: vittoria.bellato@gmail.com

Received Date: 24 Dec 2018

Accepted Date: 12 Feb 2019

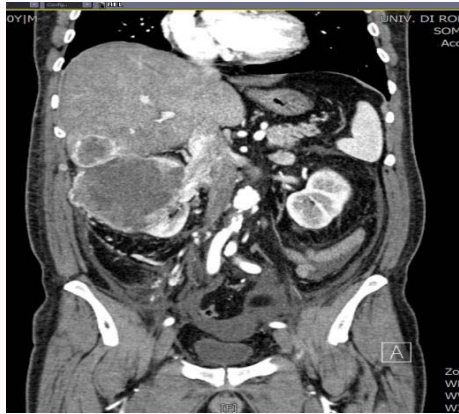Published Date: 15 Feb 2019

Citation:

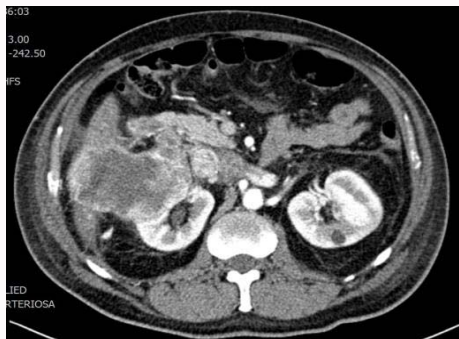Bellato V, Caronna R, Mazzesi G, Tritapepe L, Serrao G, Lancellotti F, et al. Metastatic Renal Cell Carcinoma Invading Liver, Duodenum and IVC, Surgical Treatment and Literature Review: A Case Report. *Ann Clin Case Rep.* 2019; 4: 1600.

ISSN: 2474-1655

Copyright © 2019 Bellato V. This is an open access article distributed under the Creative Commons Attribution License, which permits unrestricted use, distribution, and reproduction in any medium, provided the original work is properly cited.



Figures 1: Preoperative CT scan: Coronal reconstruction showing the renal mass, VI segment liver invasion and IVC thrombus.



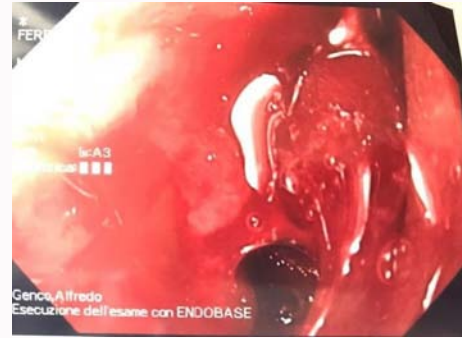
Figures 2: Preoperative CT Scan: Axial reconstruction showing the renal mass, head of the pancreas and duodenal invasion and IVC thrombus.

inferior vena cava for a length of about 6 cm. Chest: a solid formation of about 9 mm is observed at the apical segment of the LSD, strongly suspected by secondary location of the disease, not further solid lesion on both lungs. An esophagogastroduodenoscopy was performed and revealed the following: at the level of the second portion of the duodenum is hardly noticed a protruding tumefaction in the lumen, ulcerated at the top; the tumefaction reduced dramatically the lumen of the bowel (Figure 3). A transesophageal echocardiography revealed no evidence of thrombotic formation in the right atrium and in the explorable tract of the caval veins. EF 40/45% (slightly reduced), VS of normal volumes and dimensions. Lee's Index Score =2 (low <2, intermediate =2, high >2).

The patient was evaluated in a multidisciplinary tumor board and, based on the current literature and considering the intractable anemization, it was the consensus that surgical resection was attempted and followed by postoperative adjuvant immunotherapy.

Surgical technique

In supine position under general anesthesia, firstly the general surgeon proceeded to VI segment liver resection of the mass and exposure of the intrahepatic IVC until the thrombus free level. Hepatoduodenal ligament was encircled with a vessel tape to permit the Pringle maneuver. Diseased kidney was dissected and its renal artery divided and ligated. The suprahepatic IVC was dissected and surrounded by a vascular loop for potential posterior clamping. Venovenous bypass was placed between the jugular vein and IVC bifurcation to restore hemodynamic stability and prevent massive



Figures 3: EGDS showing duodenal ulcerated RCC invasion.

reduction venous return causing profound hypotension during liver maneuver. Also a recup of blood machine was placed. With the patient in Trendelenburg position we proceed to clamp the infrarenal IVC below the thrombus, the renal veins and the IVC above the thrombus of the cava (At suprahepatic level supplemented with a Pringle maneuver). Longitudinal incision of the IVC started from the tumor adhesion-free point at the level of the renal vein keeping 5 mm tumor-free margin. The thrombus showed strong adhesion to the IVC walls in the first extrahepatic part, while it was possible to mobilize from the IVC in the intrahepatic fraction. Oval shaped xeno-pericardial patch was used to repair the incised IVC by running suture using polypropylene 5-0. Transesophageal echocardiography was performed intraoperatively to monitor cardiac function and possible pulmonary artery thrombus by manipulation of the tumor thrombus in the IVC. After accurately evaluating the invasion of the duodenum and the surgical risk of a partial pancreatic resection, the dissection along with a complete duodenopancreatectomy followed by splenectomy was completed.

At 9 months follow up the patient is in good condition and is completing the third cycle of chemotherapy with sunitinib.

Discussion

Venous invasion is associated with Stage T3 of the TNM classification. Patients with untreated stage T3 RCC with intravascular IVC thrombus have a median life expectancy of 5 months and 1 year disease-specific survival of 29% [6]. Successful resections of a RCC with removal of associated intravascular thrombus have been associated with a good long term control of the tumor in nearly 50% of cases that present with T3 disease. Most of the studies that analyzed retrospectively the outcomes between RCC patient with IVC thrombus who received surgical management and the patients who underwent straight to systemic therapy found that patient who underwent surgery have longer survival rate; however the significance of those retrospective studies are limited by selection bias. In fact, most of the patients who did not receive surgical management had higher ECOG-PS and greater tumor burden, including unresectable disease and metastasis [7].

The presence of distant metastasis has been reported to be a very powerful prognostic factor in RCC patients with venous tumor thrombus [8]; another study showed that RCC patients with distant metastasis venous tumors had a cancer-specific survival rate of 10% and 60% in those without distant metastasis [9].

Furthermore, patients with metastatic RCC itself have historically poor prognosis, with an average survival term of 8 months. Patients

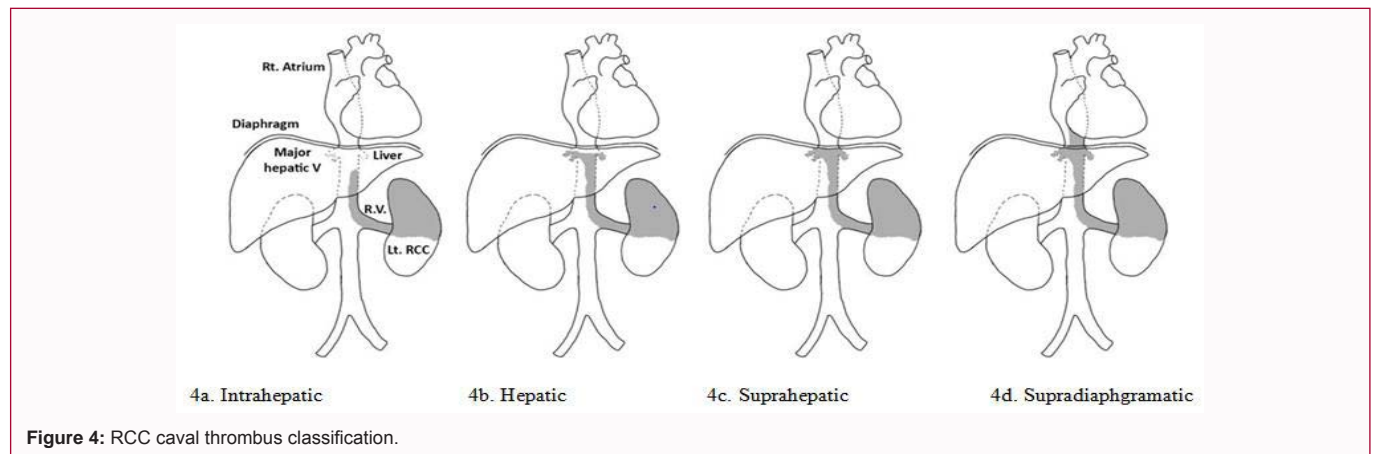


Figure 4: RCC caval thrombus classification.

with survival term of two years only account for 10% to 20% of patients. Another study confirms that the mean survival of T4 patients who are not treated surgically is 5 months.

Comparing with T3 patient management, patients who are diagnosed with metastatic renal cell carcinoma (T4) or patient who develops metastasis or recurrent disease following prior treatment are generally treated with systemic therapy, primarily using immunotherapy or agents targeting the vascular endothelial growth factor pathways.

There are currently eight US FDA approved agents available for the treatment of mRCC. Five of these agents target VEGF of its receptors, two inhibit activity of mTOR, and one is a recombinant form of endogenous cytokine IL-2 [10].

Despite new and effective conservative therapy, nephrectomy continues to have an important role in T4 patient when is performed prior to systemic therapy in attempts to decrease the bulk of the tumor (Cytoreductive surgery) and when is performed to control severe symptoms caused by the primary tumor (Palliative surgery).

Regression of metastatic disease following nephrectomy are described, but very rarely [11,12].

Two randomized controlled trials have been completed in the era of Interferon (IFN) immunotherapy (SWOG demonstrates that nephrectomy before treatment resulted in a statistically significant improvement in overall survival and EORTC demonstrates that both times to progression and overall survival duration significantly favored cytoreductive nephrectomy prior to immunotherapy) [13,14]. The available data derived from the EORTC and SWOG study shows that approximately 20% of the patients will not benefit from the additional nephrectomy and deteriorate rapidly, despite the combined approach, and ultimately meaning that they have undergone an unnecessary and morbid treatment [15].

Therefore patient selection for cytoreductive nephrectomy should be done carefully so that patient can proceed with immune-based therapy following surgery, considering the following criteria: possibility to debulk > than 74% of the tumor, ECOG PS performance status of 0 or 1 (Figure 1) and adequate organ function with no evidence of extensive liver or bone metastasis or central nervous system involvement [16].

The results of nephrectomy prior to therapy with molecularly targeted agents as opposed to molecularly targeted agent alone are

still debated. While two retrospective studies (with patient from IMDC and National Cancer Database) suggest that cytoreductive nephrectomy prior to targeted therapy provides significantly longer overall survival [17,18]; in CARMENA Trial results with Sunitinib alone met the criteria for no inferiority compared with those with nephrectomy followed by Sunitinib.

Surgical therapy for stage IV RCC with massive neoplastic venous thrombosis is still debated and it should only be performed on carefully selected patient with the intent of oncologic debulking and prophylaxis of massive embolisms which requires a multidisciplinary approach.

Large renal masses frequently induce a significant amount of reactive desmoplasia, obliterating surgical tissue planes and mimicking pT4 disease [19]. The majority of patients in whom involvement of adjacent organ is suspected clinically are over staged (60%) [20]. Colon, pancreas and diaphragm are the most frequently involved structures, followed by liver, spleen and bowel mesentery.

For patient who has radical nephrectomy with adjacent organ resection, surgical margin status is the most important variable in determining overall survival. These patients' survival outcomes are often similar to patient with metastatic disease and should be considered for neoadjuvant or adjuvant clinical trials [21].

Surgical strategies discussion

The traditional classification of RCC caval thrombus is as follows:

- I. Venous thrombus in the renal vein not reaching IVC
- II. Infra-hepatic IVC thrombus.
- III. a: Intrahepatic: A thrombus extending into the retrohepatic IVC but below the Ostia of major hepatic veins (Figure 4).
 - b: Hepatic: a thrombus extending into the retrohepatic IVC reaching the Ostia of the major hepatic veins and may extend into them causing Budd-Chiari syndrome
 - c: Suprahepatic, infradiaphragmatic: A thrombus extending into the retrohepatic IVC above the major hepatic veins but below the diaphragm.
 - d: Suprahepatic, supradiaphragmatic and infra-atrial: A thrombus extending into the supradiaphragmatic, intrapericardial IVC but not into the right atrium
- IV. Right atrial thrombus.

Depending on the extent of the IVC thrombus many different surgical techniques can be used: veno-venous bypass (for stage I and II), pump-driven Veno-Venous Bypass (VVB) in which the IVC and the IMV are connected to the right atrium (stage IIIa to IIIc) and Cardio Pulmonary Bypass with or without Deep Hypothermic Circulatory Arrest (DHCA) (stage IIIId to IV).

Level I or II IVC thrombi are treated by dissection of the IVC, without the need for a complete piggy-back, with clamping of the contralateral renal vein and the IVC above and below the thrombus, followed by cavotomy and thrombectomy. It is not necessary to perform a complete piggy-back if Pringle maneuver with hepatic clamp is performed in association with clamping of the suprahepatic IVC for less than 20 min.

In group III a hepatic mobilization using liver transplantation (piggyback) technique is usually done to allow adequate exposure of the retrohepatic IVC. If the ligation and division of all retrohepatic veins (complete piggy-back) is completed then it is not necessary to clamp the hepatic hilum in level III thrombosis [22].

Ciancio et al. [23] described a successful technique in removing stage IIIId thrombi without intraoperative bypass maneuvers while avoiding median sternotomy depending on milking of the tumor thrombus below the level of the major hepatic veins. This is facilitated by IVC dissection from the posterior abdominal wall, thus allowing the surgeon fingers to wrap circumferential around the IVC and avoiding letting loose a thrombus fragment [23].

If the lumen of the IVC is reduced by >50% after vascular resection, patch angioplasty of the IVC with biologic, autologous or synthetic material can be used to reconstruct the IVC and to maintain satisfactory luminal domain and latency [24]. In those cases in which a segmental resection of the IVC wall is necessary to ensure negative margins, the IVC can be replaced with a tube graft. However, in cases in which the IVC is totally occluded by either tumor or no tumor thrombus, segmental resection of the IVC can be performed to ensure negative margins, but there is no need to perform IVC reconstruction and it can be ligated and left in discontinuity [25]. If resection with reconstruction or replacement of an occluded IVC is planned, preservation of uninvolved venous collaterals and lumbar veins during IVC mobilization is important to ensure pathways for venous return and avoidance of postoperative lower extremity swelling [26].

Concomitant partial or total cross-clamping of the abdominal aorta will maintain systemic blood pressure above 100mmHg. The clamping should not be continued for more than 30 minutes to avoid renal dysfunction [27].

Conclusion

For those patients showing a good PS and presenting with locally advanced metastatic RCC invasion to neighboring viscera, surgical resection is a viable option that should be comprehensively discussed. Further studies to evaluate the survival benefit in combination with targeted therapies are anticipated.

Complete surgical extirpation is possible in cases of RCC is invading other organs such as pancreas, duodenum, liver and retroperitoneum. In this scenario, to narrow the possible intraoperative and post-operative complication, a multidisciplinary approach and equipe is recommended.

A contemporary, multi institutional cohort is needed to

determine which patients may benefit from such aggressive surgical interventions. Moreover, the role of systemic therapies continues to evolve in the management of locally invasive tumors.

References

1. Ferlay J, Steliarova-Foucher E, Lortet-Tieulent J, Rosso S, Coebergh JW, Comber H, et al. Cancer incidence and mortality patterns in Europe: Estimates for 40 countries in 2012. *Eur J Cancer*. 2013;49(6):1374-403.
2. Slaton JW, Balbay MD, Levy DA, Pisters LL, Nesbitt JC, Swanson DA, et al. Nephrectomy and vena caval thrombectomy in patients with metastatic renal cell carcinoma. *Urology*. 1997;50(5):673-7.
3. Adamo R, Greaney PJ, Witkiewicz A, Kennedy EP, Yeo CJ. Renal cell carcinoma metastatic to the duodenum: Treatment by classic pancreaticoduodenectomy and review of the literature. *J Gastrointest Surg*. 2008;12(8):1465-8.
4. Nikfarjam M, Gusani NJ, Kimchi ET, Mahraj RP, Staveley-O'Carroll KF. Combined right nephrectomy and pancreaticoduodenectomy. Indications and outcomes. *J Pancreas*. 2008;9(4):449-455.
5. Schlüssel AT, Fowler AB, Chinn HK, Wong LL. Management of locally advanced renal cell carcinoma with invasion of the duodenum. *Case Rep Surg*. 2013;2013:596362.
6. Reese AC, Whitson JM, Meng MV. Natural history of untreated renal cell carcinoma with venous tumor thrombus. *Urol Oncol*. 2013; 31(7):1305-9.
7. Hatakeyama S, Yoneyama T, Hamano I, Murasawa H, Narita T, Oikawa M, et al. Prognostic benefit of surgical management in renal cell carcinoma patients with thrombus extending to the renal vein and inferior vena cava: 17-year experience at a single center. *BMC Urol*. 2013;13:47.
8. Miyake H, Terakawa T, Furukawa J, Muramaki M, Fujisawa M. Prognostic significance of tumor extension into venous system in patients undergoing surgical treatment for renal cell carcinoma with venous tumor thrombus. *Eur J Surg Oncol*. 2012;38(7):630-6.
9. Lambert EH, Pierorazio PM, Shabsigh A, Olsson CA, Benson MC, McKiernan JM. Prognostic risk stratification and clinical outcomes in patients undergoing surgical treatment for renal cell carcinoma with vascular tumor thrombus. *Urology*. 2007;69(6):1054-8.
10. Bex A, Gore M, Mulders P, Sternberg CN. Recent advances in the treatment of advanced renal cell carcinoma: Towards multidisciplinary personalized care. *BJU Int*. 2012;110(9):1289-300.
11. Elhilali MM, Gleave M, Fradet Y, Davis I, Venner P, Saad F, et al. Placebo-associated remissions in a multicentre, randomized, double-blind trial of interferon γ -1b for the treatment of metastatic renal cell carcinoma. *BJU Int*. 2000;86(6):613-8.
12. Silber SJAY, Chang CY, Gould F. Regression of metastases after nephrectomy for renal cell carcinoma. *Br J Urol*. 1975;47:259-61.
13. Flanigan RC, Salmon SE, Blumenstein BA, Bearman SI, Roy V, McGrath PC, et al. Nephrectomy followed by interferon alfa-2b compared with interferon alfa-2b alone for metastatic renal-cell cancer. *N Engl J Med*. 2001;345(23):1655-9.
14. Mickisch GH, Garin A, van Poppel H, de Prijck L, Sylvester R. Radical nephrectomy plus interferon- α -based immunotherapy compared with interferon α alone in metastatic renal-cell carcinoma: A randomised trial. *Lancet*. 2001;358(9286):966-70.
15. Bex A, Horenblas S, De Gast GC. The timing of immunotherapy and nephrectomy in multimodality treatment of metastatic renal cell carcinoma. *Technol Cancer Res Treat*. 2003;2:3.
16. Fallick ML, McDermott DF, LaRock D, Long JP, Atkins MB. Nephrectomy before interleukin-2 therapy for patients with metastatic renal cell carcinoma. *J Urol*. 1997;158(5):1691-5.
17. Heng DY, Wells JC, Rini BI, Beuselinck B, Lee JL, Knox JJ, et al.

- Cytoreductive nephrectomy in patients with synchronous metastases from renal cell carcinoma: Results from the international metastatic renal cell carcinoma database consortium. *Eur Urol.* 2014;66(4):704-10.
18. Hanna N, Sun M, Meyer CP, Nguyen PL, Pal SK, Chang SL, et al. Survival analyses of patients with metastatic renal cancer treated with targeted therapy with or without cytoreductive nephrectomy: A national cancer data base study. *J Clin Oncol.* 2016;34(27):3267-75.
 19. Connolly J, Eisner D, Goldman S, Stutzman R, Steiner M. Benign retroperitoneal fibrosis and renal cell carcinoma. *J Urol.* 1993;149(6):1535-7.
 20. Margulis V, Sánchez-Ortiz RF, Tamboli P, Cohen DD, Swanson DA, Wood CG. Renal cell carcinoma clinically involving adjacent organs: Experience with aggressive surgical management. *Cancer.* 2007;109(10):2025-30.
 21. Karellas ME, Jang TL, Kagjwada MA, Kinnaman MD, Jarnagin WR, Russo P. Advanced-stage renal cell carcinoma treated by radical nephrectomy and adjacent organ or structure resection. *BJU Int.* 2009;103(2):160-4.
 22. Jimenez-Romero C, Conde M, de la Rosa F, Manrique A, Calvo J, Caso Ó, et al. Treatment of caval vein thrombosis associated with renal tumors. *Cir Esp.* 2017;95(3):152-9.
 23. Ciancio G, Vaidya A, Savoie M, Soloway M. Management of renal cell carcinoma with level III thrombus in the inferior vena cava. *J Urol.* 2002;168:1374-7.
 24. Hyams ES, Pierorazio PM, Shah A, Lum YW, Black J, Allaf ME. Graft reconstruction of inferior vena cava for renal cell carcinoma stage pT3b or greater. *Urology.* 2011;78(4):838-43.
 25. Blute ML, Boorjian SA, Leibovich BC, Lohse CM, Frank I, Karnes RJ. Results of inferior vena caval interruption by greenfield filter, ligation or resection during radical nephrectomy and tumor thrombectomy. *J Urol.* 2007;178(2):440-5.
 26. Haidar GM, Hicks TD, El-Sayed HF, Davies MG. Treatment options and outcomes for caval thrombectomy and resection for renal cell carcinoma. *J Vasc Surg Venous Lymphat Disord.* 2017;5(3):430-6.
 27. Jibiki M, Iwai T, Inoue Y, Sugano N, Kihara K, Hyochi N, et al. Surgical strategy for treating renal cell carcinoma with thrombus extending into the inferior vena cava. *J Vasc Surg.* 2004;39(4):829-35.