

See discussions, stats, and author profiles for this publication at: <https://www.researchgate.net/publication/325270262>

A brief anatomo–surgical dissection guide to human neck: results of the collaboration between the University of Palermo and the University of Malta

Article in *EuroMediterranean Biomedical Journal* · May 2018

DOI: 10.3269/1970-5492.2018.13.14

CITATIONS

3

READS

843

16 authors, including:



Francesco Carini

Università degli Studi di Palermo

96 PUBLICATIONS 707 CITATIONS

[SEE PROFILE](#)



Margherita Mazzola

Università degli Studi di Palermo

26 PUBLICATIONS 136 CITATIONS

[SEE PROFILE](#)



Alessia La Mantia

Università degli Studi di Palermo

1 PUBLICATION 3 CITATIONS

[SEE PROFILE](#)



Benedetta Baldari

Sapienza University of Rome

8 PUBLICATIONS 5 CITATIONS

[SEE PROFILE](#)

Some of the authors of this publication are also working on these related projects:



personal identification [View project](#)



surgical anatomy [View project](#)

Technical report

A BRIEF ANATOMO-SURGICAL DISSECTION GUIDE TO HUMAN NECK: RESULTS OF THE COLLABORATION BETWEEN THE UNIVERSITY OF PALERMO AND THE UNIVERSITY OF MALTA.

Francesco Carini^{1^}, Monica Salerno², Margherita Mazzola³, Chiara Lo Piccolo⁴, Giorgia Cavallo^{3*}, Sofia Musso^{3*}, Stefania Gentile^{3*}, Stefania D'Accardo^{3*}, Alessia La Mantia^{3*}, Agostino Accardo³, Benedetta Baldari⁵, Livia Besi⁵, Matteo Scopetti⁵, Matteo Faleo⁶, Christian Zammit^{2°}, Giovanni Tomasello^{1^}.

1. Department of Experimental Biomedicine and Clinical Neuroscience, University of Palermo, Italy.
2. Department of Anatomy, School of Medicine, University of Malta, Msida, Malta.
3. School of Medicine and Surgery, University of Palermo, Italy.
4. European Oncologic Institute, Division of Head and Neck Surgery, Milano, Italy.
5. Department of Anatomical, Histological, Forensic and Orthopedic Sciences, Sapienza University of Rome.
6. Kingston University of London.

*These authors are the medical students at the University of Palermo that performed the experience at the University of Malta, and they contributed equally to this work.

°The authors are Faculty at the University of Malta and guided the students to dissect the neck

^ These authors are Faculty at the University of Palermo and guided the students to write the text of this paper.

ARTICLE INFO

Article history:

Received 23 March 2018

Revised 25 April 2018

Accepted 29 April 2018

Keywords:

cadaveric study, surgical dissection course, topographical anatomy.

ABSTRACT

The aim of this article is to show methods for dissection of the neck. In the summer of 2017 a group of students of the University of Palermo that have already passed the exam of Human Anatomy took a 4 weeks dissection course at the University of Malta. The students were provided with a dissection kit, video recording equipment and cameras for taking pictures. They dissected the skin, the subcutaneous tissue, the muscular bundles, the muscles, the vascular and nervous bundles, the nerves, the larynx, the trachea and the esophagus. This paper presents the results of the dissection course and a small and simple guide to young students and medical doctors who want to learn the bases of neck dissection.

© EuroMediterranean Biomedical Journal 2018

1. Introduction

Medicine is a science that requires both a practical and a theoretical approach, and the last one, unfortunately, is not often valued in our University. The study of anatomy, which is the basis for a doctor's education, exclusively through books and atlases, is indeed partially lacking (1-3). That is why a group of students from the University of Palermo have been selected, by virtue of the university career and the knowledge of English, to take part in an anatomic dissection course at the University of Malta (4,5).

The course took place in the university's dissection hall. The student spent their time dissecting, analyzing and separating the various anatomical structures under the supervision of tutors from both universities.

This article will focus on the anatomy of the neck. The neck provides for the passage of many structures that connect the head with the thorax and the abdomen, it also allows a good range of head movements. Most of surgical conditions that occur in this region and their variety make the neck an anatomical part of great interest and importance; for this reason we decided to carry out the dissection of the neck (6-8).

* Corresponding author: Francesco Carini, francesco.carini@unipa.it

DOI: 10.3269/1970-5492.2018.13.14

All rights reserved. ISSN: 2279-7165 - Available on-line at www.embj.org

The dissections were preceded by reviewing the anatomy of the neck, using books and atlases for a recognition of the anatomical planes. The anatomical limits of the neck allow it to be distinguished from the regions of the head and thorax. Superiorly, in an anterior-posterior direction, the limits are the mandibular profile, the auricular back line and the superior nuchal line.

Inferiorly, in an anterior-posterior direction, the limits are the jugular notch, to the superior border of the clavicle and to the spinous process of C7.

The aim of this work was to offer to offer a guide to young students and medical doctors that want to learn the bases of neck dissection.

2. Material and methods

Two thiel embalmed cadavers, who died of natural causes were analyzed. The first one, a male cadaver, was 80 years old and the second one, a female cadaver, was 75 years old. The materials used during the course include both anatomical books and atlases, used to compare the theoretical knowledge learned beforehand at the University of Palermo with the body structures studied on the cadaver, and surgical instruments, such as: surgical anatomical forceps, scalpel handle size 4 and blade size 22, scissors and vascular clamps (supplied by the University of Malta).

Photos were made with a canon EOS 1300D.

3. Results

The cadavers were placed, on the dissecting anatomic table with the head in hyperextension to aid in the dissection process. When working on the lateral regions, the head was slightly tilted to the side.

A scalpel (blade size 22, scalpel handle size 4) was used to make the first transverse incision with upward concavity and bisacromial extension. Along the midpoint of this line, a sagittal was made, for a possible dissection of the thoracic-abdominal cavity.

The skin layer was held with the anatomical forceps and a slight pressure was applied moving the scalpel downward and keeping it parallel to the lower surface of the tissue.

The vessels and nerves were isolated recognized the viscera that cross the neck or are contained in it. The dissection was carried out trying to maintain the anatomical planes and not to damage its contents.

The platysma muscle has been isolated and overturned and, after removing the adipose residues, the superficial cervical fascia was observed, perforated, medially, from the anterior jugular vein and its roots.

The superficial cervical fascia extends from the inferior margin of the mandible to the jugular notch of the sternum, anterior border of the clavicle, lateral margin of the acromion and the posterior margin of the spine of the scapula. (Figure 1).

The sternocleidomastoid muscle inserts on the mastoid process of the temporal bone and originates from two heads: clavicular and sternal heads. These two heads have been isolated using the scissors and, then, sectioned transversely and reflected in order to observe the deep cervical fascia and the hyoid bone.

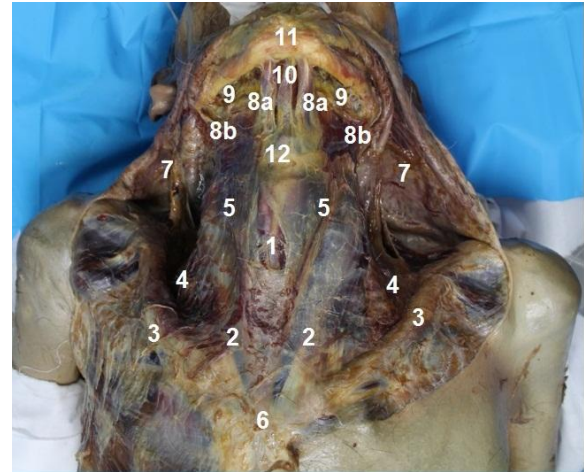


Figure 1 - This figure shows the anterior region of the neck. 1. Thyroid cartilage; 2. Sternocleidomastoid muscle; 3. Clavicle; 4. Major supraclavicular pit; 5. Carotid triangle; 6. Suprasternal notch.7. Platysma muscle; 8a. Digastric muscle, anterior belly; 8b. Digastric muscle, posterior belly; 9. Mylohyoid muscle; 10. Mylohyoid raphe; 11. Mandible; 12. Hyoid bone.

The latter is located at the C4 level and provides attachment for both supra and infra-hyoid muscles (Figure 2).

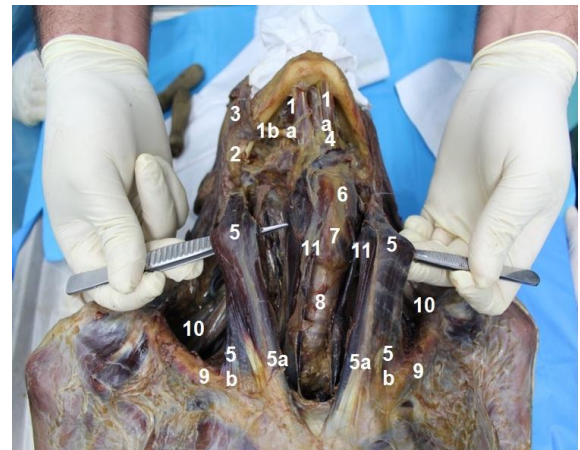


Figure 2 - This figure shows the sternocleidomastoid muscle and the anterior region of the neck. 1. a. anterior belly of the digastric muscle; 1b. posterior belly of the digastric muscle; 2. Mastoid process; 3. Masseter muscle; 4. hyoid bone; 5. Sternocleidomastoid muscle; 5a. sternal head of sternocleidomastoid muscle; 5b. clavicular head of sternocleidomastoid muscle; 6. Thyroid cartilage; 7. Cricoid cartilage; 8. trachea; 9. clavicle; 10. scalene muscles; 11. Sternohyoid muscle

One of the suprahyoid muscles is the mylohyoid muscle which contributes to the formation of the floor of the buccal cavity. Deep to it, there is the geniohyoid muscle. On each side of the muscle, there is the stylohyoid muscle, which courses together with the digastric muscle. The latter was cleaned and isolated to better highlight the two bellies.

All the infra-hyoid muscles, were located within the investing layer of the deep cervical fascia, and are innervated by the ansa cervicalis; This the muscle-fascial plane was cut transversely. The edges of the sternocleidomastoid and sternothyroid muscles were reflected and the submandibular gland exposed. The gland was moved upward and the facial artery and the entire suprahyoid region was exposed. Afterwards, the lymph nodes of the jugular chain were identified.

Lateral to the visceral compartment the carotid sheath that envelops the vascular-nervous bundle was identified. It contained the common carotid artery, medially, the internal jugular vein laterally, the vagus nerve posteriorly. The components of this vascular-nervous bundle were isolated and carefully cleaned thoroughly by using blunt dissection (Figure 3).

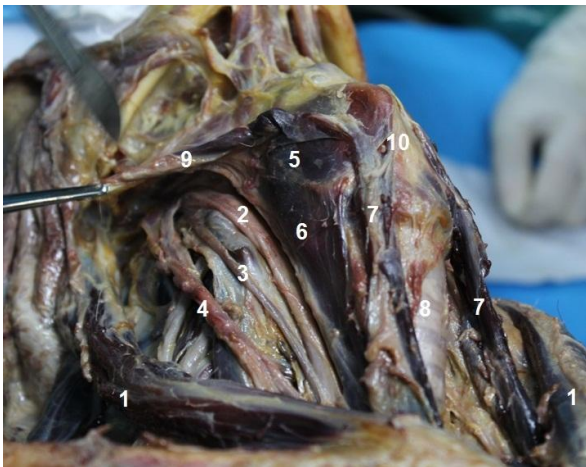


Figure 3 - This figure shows the lateral region of the neck. 1. Sternocleidomastoid muscle; 2. Common carotid; 3. Vagus nerve; 4. Internal jugular vein; 5. Thyrohyoid muscle; 6. Sternothyroid muscle ; 7. Sternohyoid muscle; 8. Cervical trachea; 9. Omohyoid muscle; 10. Thyroid cartilage.

Lateral to the vascular-nervous bundle of the neck there is the anterior scalene muscle, which originates from anterior tubercles of the transverse processes of C3 to C6 and courses latero-inferiorly, towards the upper aspect of the first rib. Superficial to this muscle, there is the phrenic nerve. The roots of the brachial plexus were located between the anterior and scalene muscle. All these structures were identified, as shown in figure 4. The roots and the trunks were identified. An anatomical variation was observed, the absence of the anterior division of the intermediate trunk of the brachial plexus. The lower part of the vascular-nervous bundle is characterized by the confluence of the internal jugular and subclavian veins which form the brachiocephalic trunk. The external jugular vein, as well as the anterior jugular vein, drain into the subclavian vein. Deep to the venous system, there are large arterial vessels: the common carotid artery and the subclavian artery.

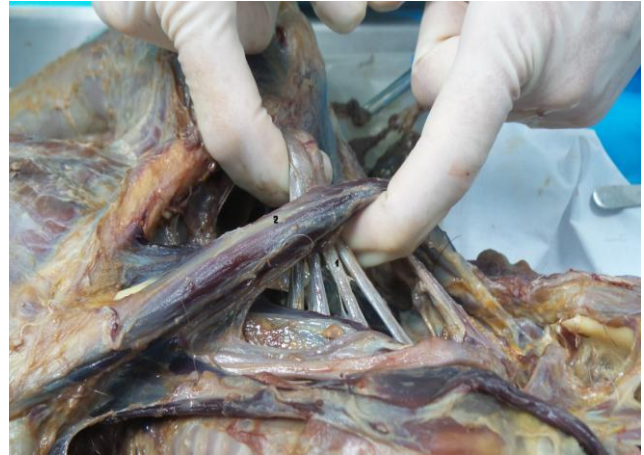

Figure 4 - This figure shows the roots of the brachial plexus. 1. Front branches of fifth, sixth, seventh, eighth cervical nerves. 2. Scalene muscle

The Ansa of the Vieussens crosses the subclavian artery and the recurrent laryngeal nerve that hooks around the aortic arch. Enveloped in the visceral fascia the following are structures were observed:

- the thyroid gland;
- the cervical trachea;
- the recurrent laryngeal nerve;
- the esophagus.

Posterior to these structures it is possible the retro pharyngeal space was identified which continues, inferiorly, with the retro retro-esophageal space. This space is important from the clinical point of view, since oral infections, can track down to the retro pharyngeal and retro esophageal space and then to the mediastinum, causing mediastinitis. To access the retro pharyngeal space, the tongue was reflected by incising the floor of the oral cavity on the lower margin of the mandible body using scalpels and forceps. This allowed to expose the prevertebral fascia that contains the cervical vertebrae (Figure 5).

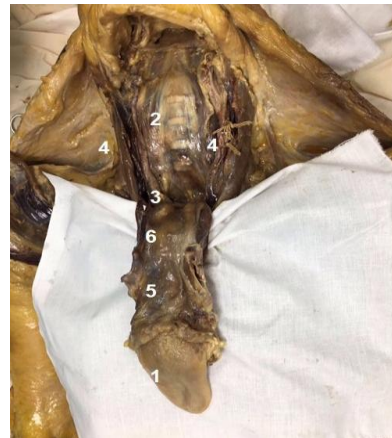

Figure 4 - This figure shows the tongue and the retro-esophageal space. 1. Tongue; 2. Vertebral bodies; 3. Retro-esophageal space; 4. Neurovascular bundle; 5. Pharynx; 6. Esophagus

4. Conclusions

This course of anatomical dissection has allowed to the students to deviate from the simplified and two-dimensional image offered by atlases and anatomy books and to approach the real understanding of three-dimensional anatomy.

Despite the preparation offered by course of study, identifying on the cadaver the anatomical structures, previously studied in books and atlases, was initially difficult for the students. Only after practice and experience they have been able to acquire a certain degree of awareness. In our opinion, this opportunity should be given to a higher number of students, as already reported (9)

5. Acknowledgements

Our special thanks go to Professor Francesco Cappello whose personal availability and professional were essential in the carrying out this project.

References

1. Costantino C, Maringhini G, Albeggiani V, Monte C, Lo Cascio N, Mazzucco W. Perceived need for an International elective experience among Italian medical residents. *EuroMediterranean Biomedical Journal* 2013; 8:10-15.
2. Mazzucco W, Marotta C, De Waure C, Marini G, Fasoletti D, Colicchio A, Luppi D, Pignatti, Sessa G, Silenzi A, Puccio G, Parente P, Costantino C, Bonetti P, Gangi S, Maffongelli E, Nania R, Russo S. Motivational aspects and level of satisfaction of Italian junior doctors with regard to knowledge and skills acquired attending specific general practice training courses. A national web survey. *EuroMediterranean Biomedical Journal* 2017; 12:77-86.
3. Etrusco A, Salvaggio L, Arrigo G, Cataldi S, Farina C, Gattuso L, La Bruna M, Pistone M, Tinaglia S, Torregrossa F, Carini F, Tomasello G, Pomara C. Anatomical dissection and analysis of the structures of the upper limb. *EuroMediterranean Biomedical Journal* 2017; 12: 13-16.
4. Pollara P, Inzerauto P, Ravi N, Tomasino C, Scorsone A, Liguoro B, Busardò FP, Slama F, Capitummino R, Seidita E, Tomasello G, Carini F, Pomara C. Experiences that "Reach the heart". Taking part in a whole body dissection course at the University of Malta. *EuroMediterranean Biomedical Journal* 2017; 12: 108-112.
5. Costantino C, Moscadini S, Puccio G, Cappello F, Mazzucco W. *EuroMediterranean biomedical journal: the renewed manuscript layout and web rendering foreshadow further journal improvement.* *EuroMediterranean Biomedical Journal* 2017; 12:1-5.
6. Costantino C, Moscadini S, Puccio G, Cappello F, Mazzucco W. *EuroMediterranean biomedical journal: The renewed journal for young doctors aims even higher.* *EuroMediterranean Biomedical Journal* 2014; 9: 1-6.
7. Barni T, Billi AM, Businaro R, Cannas M, Cappello F, Castellucci M, Cocco L, D'Agata Velia, De Caro R, De Luca R, Dolci S, Geremia R, Guerra G, Gulisano M, Loreto C, Macchi V, Manzoli L, Mezzogiorno A, Montella A, Morini S, Nori S, Palumbo C, Papa M, Porzionato A, Rezzani R, Rodella L, Rossi P, Sbarbati A, Serrao G, Vercelli A, Vertemati M, Vitale M, Zancanaro C, Zecchi S, Zummo G. *Anatomia del Gray*. Edra.
8. Gilroy AM, MacPheerson BR, Ross LM. *Prometheus. Atlante di Anatomia*. Edises
9. Saguto D, Gaglio V, Lanza LML, Albanese PG, Caponnetto AM, Piazza VG, Doria G, Sanfilippo F, Crimi S, Stamile A, Li Calzi G, Rappa F, Bongiorno V, Dispenza F, Salamone G, Biondi A, Fucarino A. Survey on the demand of Sicilian physicians for a specific training on human cadavers and animals. *EuroMediterranean Biomedical Journal* 2018;13: 9-14.