




Contents lists available at ScienceDirect

## Progress in Retinal and Eye Research

journal homepage: [www.elsevier.com/locate/preteyerres](http://www.elsevier.com/locate/preteyerres)

## Retinal changes in Alzheimer's disease— integrated prospects of imaging, functional and molecular advances

Veer B. Gupta<sup>a</sup>, Nitin Chitranshi<sup>b</sup>, Jurre den Haan<sup>c</sup>, Mehdi Mirzaei<sup>b</sup>, Yuyi You<sup>b</sup>,  
Jeremiah KH. Lim<sup>d</sup>, Devaraj Basavarajappa<sup>b</sup>, Angela Godinez<sup>b</sup>, Silvia Di Angelantonio<sup>e,f</sup>,  
Perminder Sachdev<sup>g,h</sup>, Ghasem H. Salekdeh<sup>i</sup>, Femke Bouwman<sup>c</sup>, Stuart Graham<sup>b,j,\*\*,1</sup>,  
Vivek Gupta<sup>b,\*,1</sup>

<sup>a</sup> School of Medicine, Deakin University, VIC, Australia<sup>b</sup> Faculty of Medicine Health and Human Sciences, Macquarie University, North Ryde, NSW, 2109, Australia<sup>c</sup> Department of Neurology, Alzheimer Center Amsterdam, Amsterdam Neuroscience, Vrije Universiteit Amsterdam, Amsterdam UMC, The Netherlands<sup>d</sup> Optometry and Vision Science, College of Nursing and Health Sciences, Bedford Park, South Australia, 5042, Australia<sup>e</sup> Center for Life Nanoscience, Istituto Italiano di Tecnologia, Rome, Italy<sup>f</sup> Department of Physiology and Pharmacology, Sapienza University of Rome, Rome, Italy<sup>g</sup> Centre for Healthy Brain and Ageing (CHeBA), School of Psychiatry, Faculty of Medicine, University of New South Wales, Sydney, New South Wales, Australia<sup>h</sup> Neuropsychiatric Institute, Prince of Wales Hospital, Sydney, New South Wales, Australia<sup>i</sup> Department of Molecular Systems Biology, Cell Science Research Center, Royan, Institute for Stem Cell Biology and Technology, ACECR, Tehran, Iran<sup>j</sup> Save Sight Institute, Sydney University, Sydney, NSW, 2000, Australia

## ARTICLE INFO

## Keywords:

Retina  
Amyloid  
Tau  
Proteomics  
Dementia  
Imaging  
Vascular changes  
Retinal ganglion cell  
Neuroinflammation  
Glaucoma  
Optic nerve  
Optical coherence tomography (angiography) (OCTA)  
Hyperspectral imaging

## ABSTRACT

Alzheimer's Disease (AD) is a devastating neurodegenerative disorder of the brain, clinically characterised by cognitive deficits that gradually worsen over time. There is, at present, no established cure, or disease-modifying treatments for AD. As life expectancy increases globally, the number of individuals suffering from the disease is projected to increase substantially. Cumulative evidence indicates that AD neuropathological process is initiated several years, if not decades, before clinical signs are evident in patients, and diagnosis made. While several imaging, cognitive, CSF and blood-based biomarkers have been proposed for the early detection of AD; their sensitivity and specificity in the symptomatic stages is highly variable and it is difficult to justify their use in even earlier, pre-clinical stages of the disease. Research has identified potentially measurable functional, structural, metabolic and vascular changes in the retina during early stages of AD. Retina offers a distinctively accessible insight into brain pathology and current and developing ophthalmic technologies have provided us with the possibility of detecting and characterising subtle, disease-related changes. Recent human and animal model studies have further provided mechanistic insights into the biochemical pathways that are altered in the retina in disease, including amyloid and tau deposition. This information coupled with advances in molecular imaging has allowed attempts to monitor biochemical changes and protein aggregation pathology in the retina in AD. This review summarises the existing knowledge that informs our understanding of the impact of AD on the retina and highlights some of the gaps that need to be addressed. Future research will integrate molecular imaging innovation with functional and structural changes to enhance our knowledge of the AD pathophysiological mechanisms and establish the utility of monitoring retinal changes as a potential biomarker for AD.

## 1. Introduction

Alzheimer's disease (AD) is a chronic and multifactorial

neurodegenerative disorder characterized by progressive cognitive impairments, behavioral abnormalities and disturbances in circadian rhythm (Ismail et al., 2016). The disease also involves several less frequent clinical presentations that are gradually being established. The

\* Corresponding author. Faculty of Medicine Health and Human Sciences, Macquarie University, NSW, 2109, Australia.

\*\* Corresponding author. Faculty of Medicine Health and Human Sciences, Macquarie University, NSW, 2109, Australia.

E-mail addresses: [stuart.graham@mq.edu.au](mailto:stuart.graham@mq.edu.au) (S. Graham), [vivek.gupta@mq.edu.au](mailto:vivek.gupta@mq.edu.au) (V. Gupta).<sup>1</sup> Equal authors.<https://doi.org/10.1016/j.preteyerres.2020.100899>

Received 4 July 2020; Received in revised form 24 August 2020; Accepted 27 August 2020

Available online 2 September 2020

1350-9462/© 2020 Elsevier Ltd. All rights reserved.

clinical and molecular features of AD were initially reported by German scientist Aloisius Alzheimer in 1906 and the disease named in his

connotation, that eyes not only reflect our emotions and intelligence but also mirror systemic and brain health. The retina offers unique attributes

### Abbreviations

ADAS-Cog	AD assessment scale-cognitive subscale	MRI	magnetic resonance imaging
ANX776	annexin-5 labelled with fluorescent dye	Mrp12	Mitochondrial Ribosomal Protein L2
ApoE	apolipoprotein E	MS	multiple sclerosis
APP	amyloid precursor protein	MRPL2	39S ribosomal protein L2
AP1S2	Adaptor Related Protein Complex 1 Subunit Sigma 2	mTOR	mammalian target of rapamycin
A $\beta$	amyloid beta	NFL	Nerve fiber layer
BACE1	Beta-secretase 1	NFT	neurofibrillary tangles
C1q	complement component 1q	NF $\kappa$ B	nuclear factor kappa-light-chain-enhancer of activated B cells
BMO-MRW	Bruch's membrane opening–minimum rim width	OCT	optical coherence tomography
CDR	clinical dementia rating	OCTA	optical coherence tomography angiography
CHAT	Choline O-acetyltransferase	opa1	OPA1 Mitochondrial Dynamin Like GTPase
CHOP	C/EBP homologous protein	OPN	osteopontin
CRVE/CRAE	central retinal artery and vein equivalent	p70S6K	Ribosomal protein S6 kinase beta-1
CSTF2	cleavage stimulation factor subunit 2	PD	Parkinson's disease
CSV	contrast sensitivity vision	PDGFR $\beta$	platelet-derived growth factor receptor beta
CT scan	computed tomography scan	pERG	pattern electroretinogram
cTORTa	curvature tortuosity of the arterioles	PHF	paired helical filament
DHX38	DEAH-Box Helicase 38	PI	propidium iodide;
DVA	dynamic vessel analyzer	POAG	primary open angle glaucoma
Eef1a1	Eukaryotic Translation Elongation Factor 1 Alpha 1	pRNFL	Peripapillary retinal nerve fiber layer
Eef1e1	Eukaryotic Translation Elongation Factor 1 Epsilon 1	PSEN1	presenilin-1
elf2	E74-like factor 2	PSD-95	Postsynaptic density protein 95
elf4	ETS-related transcription factor	Psma5	Proteasome 20S Subunit Alpha 5
ERG	electroretinogram	Psmb2	Proteasome 20S Subunit Beta 2
ESR1	Estrogen Receptor 1	Psmc3	26S proteasome non-ATPase regulatory subunit 3
F4/80	EGF-like module-containing mucin-like hormone receptor-like 1	pSTR	positive scotopic threshold response
FAZ	foveal avascular zone surface	pTau	phosphorylated tau
FDa	fractal dimension	Rbmx11	RNA binding motif protein, X-linked-like-1
GCC	Ganglion cell complex	SC	superior colliculus
GCL	ganglion cell layer	SUVr	standardized uptake value ratio
GFAP	glial fibrillary acidic protein	TREM2	triggering receptor expressed on myeloid cells 2
GSK3 $\beta$	glycogen synthase kinase 3 $\beta$	Rp9	Retinitis pigmentosa 9
HSI	hyperspectral imaging	Rp135a	Ribosomal Protein L35a
IL	interleukin	R9136a	Ribosomal Protein L36a
INL	inner nuclear layer	SNAP-25	Synaptosomal-Associated Protein
LGN	lateral geniculate nucleus	TrkB	tropomyosin receptor kinase B
LRP-1	low density lipoprotein receptor-related protein 1	TUNEL	terminal deoxynucleotidyl transferase dUTP nick end labelling
MAPT	Microtubule Associated Protein Tau	TUJ 1	$\beta$ -Tubulin 3
mRGC	melanopsin ganglion cells	VEP	visual evoked potential
		Zn-DPA	Bis(zinc(II)-dipicolylamine)

honour by his colleague and mentor, Emil Kraepelin (Toodayan, 2016). The disease presently accounts for about 70% of all dementia cases globally. Age is the major risk factor and the probability of a person developing the disorder doubles approximately every 5 years after the age of 65 (Corrada et al., 2010). Therefore, as the global proportion of older people increases, the disease has emerged as one of the largest medical and socio-economic problems of our time. Since the 1990s, the prevalence of dementia has doubled, and approximately 50 million people are believed to be currently living with this disorder as continuum. Estimates suggest that around 100 million people could be affected by 2050 (Collaborators, 2019), and with the world's ageing demographics, this poses a grave public health challenge.

Although AD has traditionally been recognized as being restricted to the brain, our understanding of AD has developed to also include extracerebral manifestations with increasing evidence of ocular involvement (Chiu et al., 2012; Koronyo et al., 2012). The aphorism “Les yeux sont le miroir de l'âme” — “the eyes are the mirror of the soul” — reminds the

in that owing to clear optics of the eye, it is the only place where neurons and blood vessels can be directly visualized (Lim et al., 2016; Patton et al., 2005; S. Mojtaba Golzan, 2017). Anatomically and developmentally, the retina is an extension of the CNS and is composed of several neurons including the retinal ganglion cells (RGCs), whose axons connect with the lateral geniculate nucleus (LGN) and superior colliculus (SC), which in turn project axons to the visual cortex (Erskine and Herrera, 2014; Yucel et al., 2003). Retina therefore shares similarities with the brain tissue and hosts neuronal, astroglial and microglial populations. It is protected by blood-retinal barrier (BRB) that implements selective blood-retinal permeability resembling to that of the blood-brain barrier (BBB). The eye also exhibits immune response processes commensurate with that observed in the brain and spinal cord. Thus, as the retina provides a “strategic glimpse of the brain”, retinal examination can be a novel, non-invasive, inexpensive, and tractable marker for AD diagnosis. Various retinal changes in AD have been investigated in the last three decades, and here we provide a brief

historical timeline of the key studies that have propelled research into this space, as shown in Fig. 1.

AD most likely begins with the accumulation and propagation of misfolded A $\beta$  assemblies in the brain, followed by the hyperphosphorylation of tau protein leading to paired helical filaments (PHFs) and neurofibrillary tangles (NFTs) (Braak and Braak, 1991; Spire-Jones and Hyman, 2014). These molecular events are accompanied by sequelae of neurodegenerative changes and glial cell activation in the brain (Andreone et al., 2020; Itagaki et al., 1989). Currently, a diagnosis of AD is based on clinical symptomatology combined with biomarker evidence of AD neuropathological change (McKhann et al., 2011;

Sperling et al., 2011). With continuous imaging and CSF biomarker developments, an organized approach was required to bring uniformity in research and diagnostic criteria for AD. Towards this end, National Institute of Neurological Disorders and Stroke (NINDS, USA) and Alzheimer's Association (USA) working group in (2007) recommended neuropsychological assessment as a means to establish cognitive impairment in patients and diagnose them into possible or probable AD cases (Cummings, 2012; Dubois et al., 2007). The AD diagnostic criteria was refined by National Institute on Aging and Alzheimer's Association (NIA-AA) in 2011 and again revised in 2018 wherein an understanding was reached with an objective to define and stage AD spectrum for

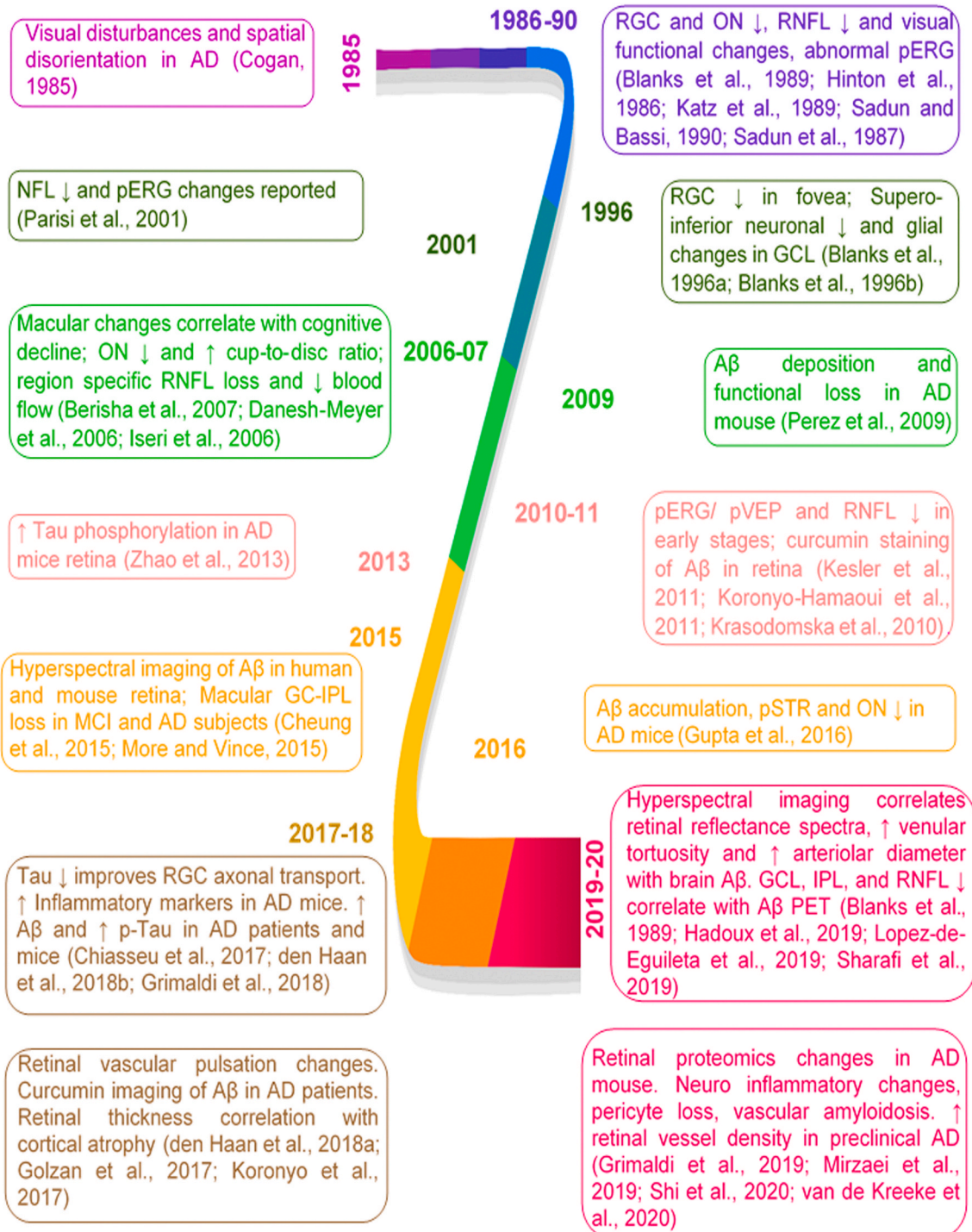


Fig. 1. Timeline marking various reports with a focus on elucidating retinal changes in AD.

research framework (Jack et al., 2011, 2018; McKhann et al., 2011). Based on these recommendations, AD is defined to include cases in which there is a combined clinical evidence for A $\beta$  (A), pathological tau (T) and neural injury (N) biomarkers [(AT(N)]. Complete biomarker investigations based on AT(N) recommendations can be contingent to either imaging or CSF analytical approaches or combination of both

strategies (Jack et al., 2018). Magnetic resonance imaging (MRI), computerized tomography (CT), and positron emission tomography (PET) scans are frequently used to image the build-up of amyloid and accompanying cerebral atrophy in the brain in cases where AD is likely (Thientunyakit et al., 2020). Since Robertson and colleagues (NY, USA) designed initial PET instrumentation in 1961, the performance and

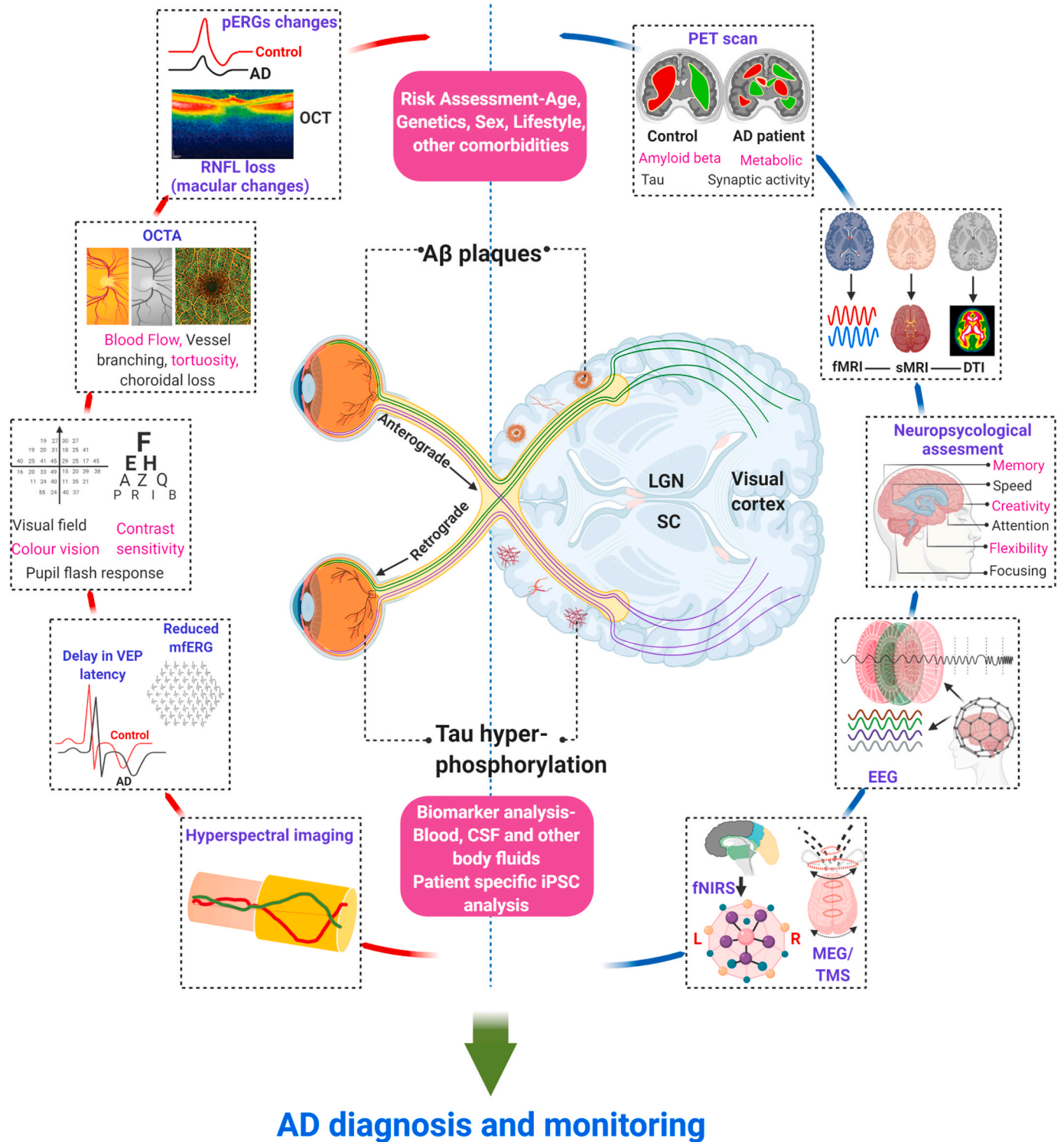


Fig. 2. Schematic representation illustrating various approaches that can be used to detect and monitor AD changes using the visual system. The anatomical relationship of the eye and the brain is presented. Various retinal and brain tests that can potentially differentiate healthy subjects from AD are presented and labelled. fNIRS: Functional near infrared spectroscopy, MEG: Magnetoencephalography, TMS: Transcranial magnetic stimulation, pERG: pattern ERG, OCTA: optical coherence tomography angiography.

scope of the technique has greatly expanded in AD diagnosis (Lu, 2019). This is particularly made possible by development of PET tracers that selectively bind A $\beta$  and tau proteins and distinguish metabolic changes in the brain (Hanseeuw et al., 2019). Amyloid and Tau-PET are very disease specific that measure the exact pathological process but with a certain threshold and limited spatial resolution. MRI also has limitations in terms of spatial resolution. Cerebrospinal fluid (CSF) provides a good reflection of brain processes, although collecting it requires lumbar puncture, which hampers widespread acceptability as a first-line test to screen AD asymptomatic cases. The validated AD biomarker assays for A $\beta$  and phosphorylated tau (pTau) changes in CSF, can enable differential diagnosis of AD (Gordon et al., 2016; Villemagne et al., 2018). PET imaging also is not easily translatable to population-wide screening mainly due to high costs involved, low half-life of radioligands such as fluorodeoxyglucose (110 min for F-18 FDG) and exposure to ionizing radiations. Consequently, accurate prediction of early, non-symptomatic stages of AD, even with these gold-standard tests is highly variable. Monitoring retinal changes may thus provide a cost effective and patient friendly way to diagnose AD. More recently, plasma p-Tau 181 is reported to track with tau-PET scores and CSF levels of p-tau181, establishing it as a potential tool for screening of MCI and asymptomatic AD patients (Janelidze et al., 2020; Thijssen et al., 2020). Development of early stage specific blood biomarkers is likely to greatly improve the AD diagnosis.

Various studies have increasingly established that the retina is affected in patients with AD (Golzan et al., 2017; Grimaldi et al., 2019; Hadoux et al., 2019; London et al., 2013; Shi et al., 2020). Since the first reports of degenerative changes in the optic nerve in AD patients (Cogan, 1985; Hinton et al., 1986; Sadun et al., 1987), retinal pathology in AD has been specifically reported as the loss of RGCs and the NFL, the deterioration of the macular ganglion cell complex, and optic nerve axonal diminution (Cheung et al., 2015; Danesh-Meyer et al., 2006; Gao et al., 2015b; Gupta et al., 2016b; Kesler et al., 2011; Koronyo-Hamaoui et al., 2011; Parisi et al., 2001). Studies from our team and others have also described retinal blood flow and vascular alterations (Feke et al., 2015; Golzan et al., 2017), astrogliosis and inflammatory changes (Grimaldi et al., 2018) associated with the AD pathophysiology (Cheung et al., 2015; Feke et al., 2015; Gao et al., 2015b; Krasodomka et al., 2010; Ramirez et al., 2017). A schematic representation of the established and emerging visual system examination technologies is shown in Fig. 2, and exemplifies that when integrated with brain imaging, biomarker and neuropsychological assessment, the eye could potentially improve AD risk assessment, detection, and monitoring.

The inability to diagnose AD early or accurately monitor the progression of the disease in a viable and non-invasive way is a major impediment in both disease management and therapeutic development (McAleese et al., 2016). Of late, several strategies including drugs and lifestyle-based changes have been proposed to be protective in cases of AD. However, most clinical trials have not been able to meet their primary objectives (Egan et al., 2019; Honig et al., 2018) with an exception of Aducanumab (Biogen) which was able to meet pre-defined end points, when administered at a high dose (Schneider, 2020). One potential explanation for these unremarkable outcomes could be the current technological limitations in monitoring subtle brain changes due to inherent difficulties in accessing the intracerebral pathologies. Another possibility underlying this failure could be that biochemical alterations are underway in the brain nearly 10–20 years before the development of the clinical syndrome. Consequently, it is vital to clinically ascertain AD pathology at earlier stages—when synaptic connections and neuronal functions may still be intact (Blennow et al., 2015; Jack et al., 2018). Recent evidence, obtained from both human and animal studies, continues to reinforce the feasibility of retinal examination to detect AD symptoms (Nguyen et al., 2017). The remainder of this review elucidates the use of recent advances in retinal imaging and its functional and structural determinants as novel biomarkers for AD. We also comprehensively summarize data regarding molecular changes in the AD retina

to understand disease mechanisms. The ongoing clinical trials, future implications and overlap with other retinal neurodegenerative disorders is also discussed.

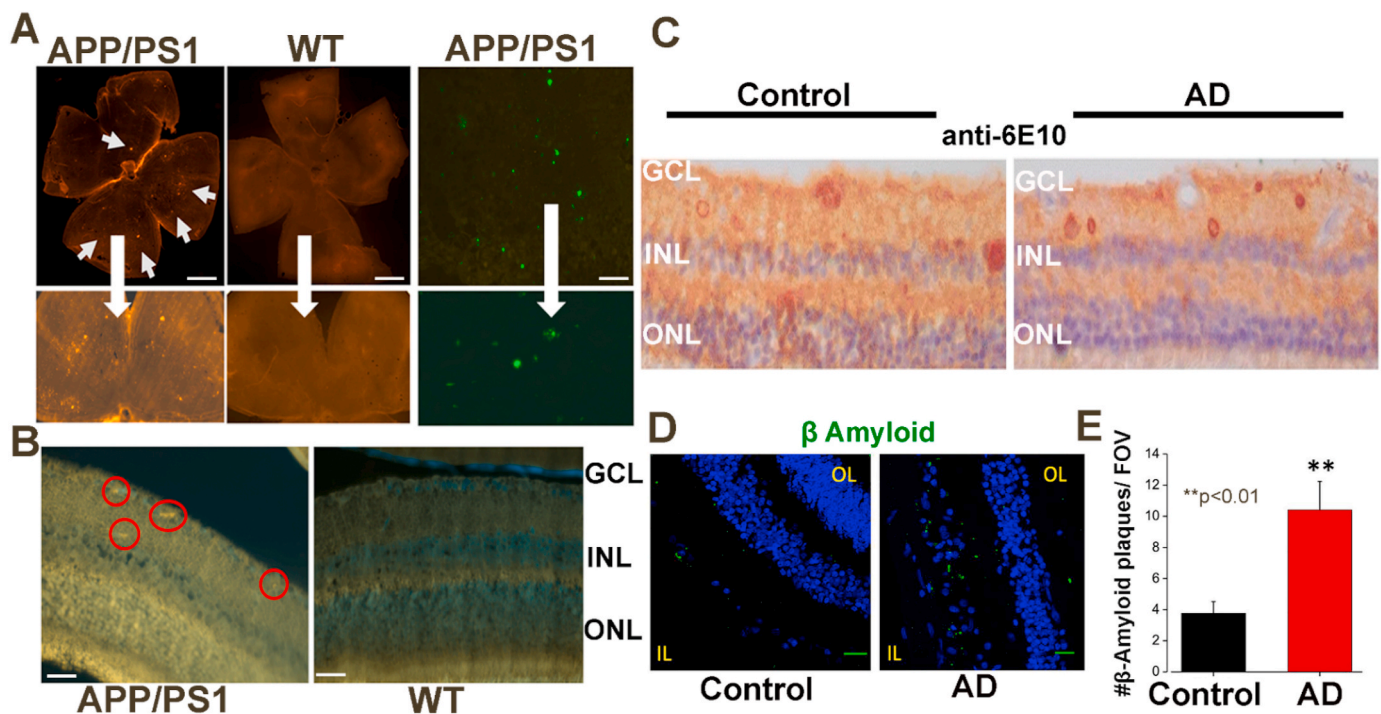
## 2. Amyloid and tau protein changes in the retina

### 2.1. Neuropathological features of amyloid in the retina

Clinical, post-mortem, and animal model studies have in general, revealed the association of AD pathophysiology with retinal dysfunction and structural alterations. Genetic, electrophysiological, and biochemical evidence suggests that build-up of A $\beta$  peptides in the brain is one of the earliest events in AD pathology, which ensues from an imbalance between its production and clearance (Selkoe and Hardy, 2016). Cortical levels of A $\beta$  are increased with low A $\beta$ 42 in CSF and these changes can be assessed using amyloid imaging and CSF analysis as per AT(N) scheme (Jack et al., 2018). A $\beta$  is small peptide fragment of 36–43 amino acids (4–5 kDa), that is derived from transmembrane amyloid precursor protein (APP) (Marsden et al., 2011). APP is expressed as several isoforms ranging in size from 695 to 770 amino acids (100–140 kDa), although APP695 is the one which is predominantly expressed in neurons (Chen et al., 2017). A $\beta$  peptides aggregate into soluble oligomers and then into transitional globular structures, and are believed to initiate a cascade of secondary pathologies involving distinct inflammatory responses, chronic vascular compliance issues, oxidative stress, mitochondrial dysregulation, and progressive synaptic and neuronal loss (Jack et al., 2018; Polanco et al., 2018; Selkoe and Hardy, 2016). Additionally, compromised glial cell capacity to mediate A $\beta$  uptake has been shown to play a vital role in AD pathogenesis, and thus modulating glial cell function has been suggested as a potential strategy to reduce the burden of A $\beta$ . Both APP and pTau are hallmark proteins of AD pathology, and a growing body of evidence indicates alterations in these proteins in the retinal tissues of both animal models of AD and human post-mortem samples. This is based on enhanced amyloid deposits and phosphorylated tau reactivity reported in several studies while others have highlighted detection of intracellular APP positivity in human AD postmortem retinal tissues, without evident A $\beta$  plaque formation (Figs. 3 and 4). This was established by using multiple APP and A $\beta$  specific antibody stainings in the superior and medial regions of the human AD retinas (den Haan et al., 2018c; Ho et al., 2014; Williams et al., 2017).

Most cases of AD are sporadic that may be linked to complex interactions between multiple genes and epigenetic factors while about 3% cases are attributed to genetic mutations (Selkoe, 2011). Animal models of both sporadic AD such as degus, beagle dog etc. and transgenic models that specifically modulate APP, tau (MAPT), neuro-inflammation genes leading to protein over-expression and aggregation pathology are known (Prpar Mihevc and Majdic, 2019; Sasaguri et al., 2017). These genetic models offer a more tractable system for AD research but have limitations in deducing correlation of pathological mechanisms with human sporadic AD condition. A $\beta$  deposition in the retina has been detected in transgenic drosophila, common degu and in the transgenic mice Tg2576, 3xTg-AD, APPSWE/PS1 $\Delta$ E9, and APPSWE/PS1M146L/L286V, 5xFAD etc. and tau retinal pathology reported in mutant MAPT, APP/PS1/MAPT models at different ages (Chiasseu et al., 2017; Du et al., 2015; Gupta et al., 2016b; Liu et al., 2009).

Our group and other researchers have identified A $\beta$  accumulation and assemblies of mini-deposits in the retina, mainly in the GCL and NFL, of APP/PS1 and 3xTg-AD mice as early as 2–3 months of age, which is several months prior to when significant A $\beta$  deposition is known to occur in the hippocampus and cerebral tissues (Koronyo-Hamaoui et al., 2011; Mirzaei et al., 2019b). Enhanced A $\beta$  deposition has also been demonstrated in retinal flat-mounts of ageing APP/PS1 mice (13–16 month), suggesting that sustained upregulation of soluble A $\beta$  could gradually lead to deposit formation in the retina (Gupta et al., 2016b). Immunoblotting analyses have also shown that soluble A $\beta$  and its various oligomers are indeed elevated in APP/PS1 mouse retinal tissues



**Fig. 3.** Amyloid changes in the retina in AD. (A) APP/PS1 mouse retinal flat mount indicating deposition of thioflavin S positive amyloid aggregates (arrows) in the retina. Scale bar 500  $\mu$ m. Amyloid  $\beta$  plaques in the corresponding brains of these animals stained using methoxy-X04 (Right panel, green). (B)  $A\beta$  specific staining (arrows) with  $\beta$ -Amyloid D54D2 antibody in the retinal cross-sections (blue-DAPI). Data reused with permission from (Gupta et al., 2016b), doi.org/10.1016/j.neulet.2016.04.059. (C) APP/ $A\beta$  staining in human AD and control retinas (superior region) using 6E10 antibody. Reused from (den Haan et al., 2018c) under the Creative Commons Attribution 4.0 International License: Creativecommons.org/licenses/by/4.0/(D) Representative human AD retinal sections displaying  $A\beta$  aggregates (green- anti- $A\beta$  antibody, D54D2, Cell Signalling) (blue- hoechst) scale- 20  $\mu$ m. (E) Change in  $A\beta$  deposits/field of view (n = 45/5 fields/patients). Reused from (Grimaldi et al., 2019) under the Creative Commons Attribution 4.0 International License: Creativecommons.org/licenses/by/4.0/.

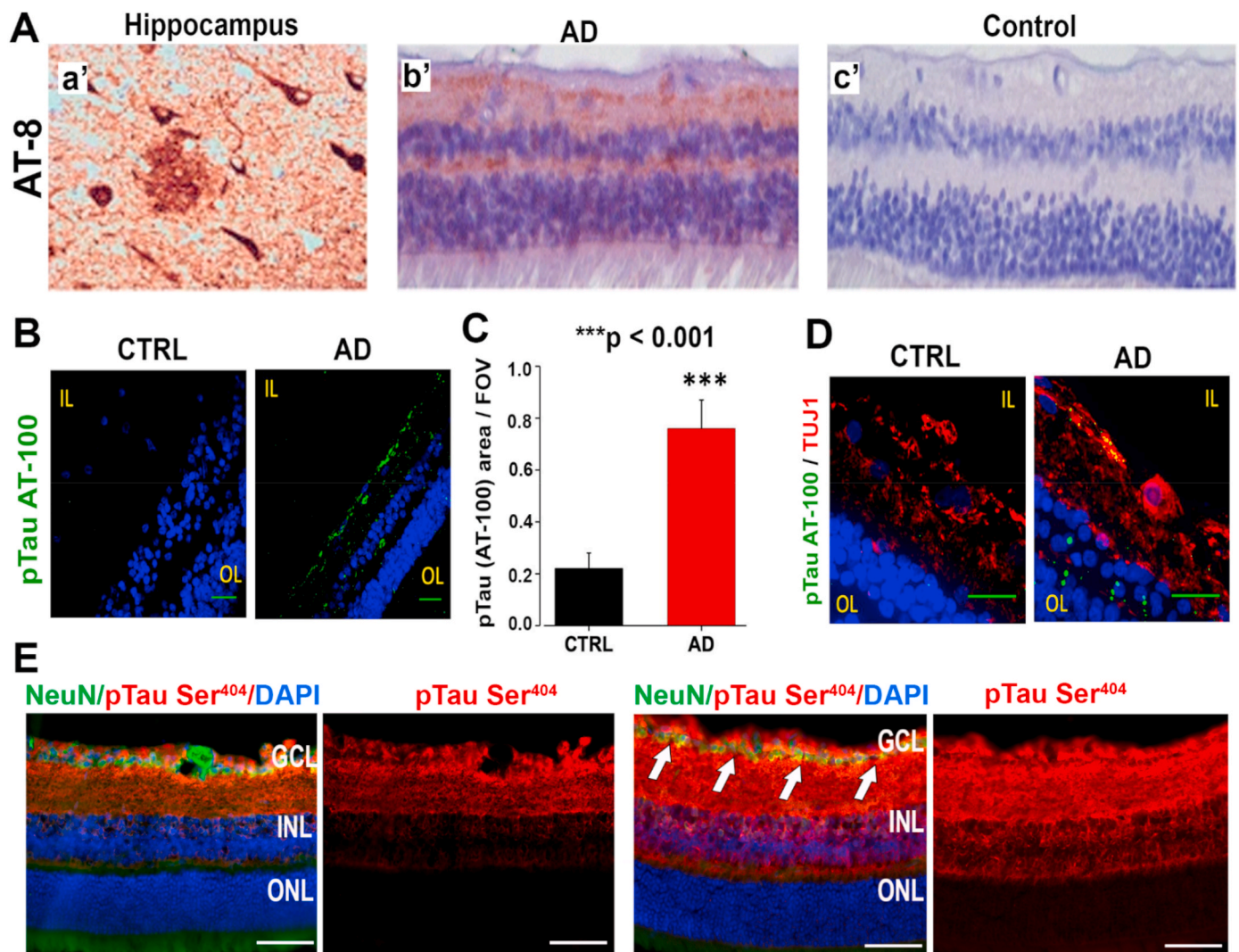
(Gupta et al., 2016b). This observation is particularly relevant given the fact that the soluble form of  $A\beta$  may exhibit more pronounced neurotoxic properties in comparison to insoluble deposits and plaques (Benilova et al., 2012). Enhanced levels of cytoplasmic  $A\beta$  labelling were also documented in the inner nuclear layer (INL) and the vacuolar structures of the GCL in 14-month-old Tg2576 and 9-month-old APP/PS1 mice models (Dutescu et al., 2009). These findings correspond with observed increases in  $A\beta$  plaque formation in the brain and demonstrate quantitative and temporal correlations between  $A\beta$  deposition in these two parts of the CNS (Grimaldi et al., 2018), although there are evident differences in morphology of  $A\beta$  deposition in the two tissues. Another recent study also quantified  $A\beta$  oligomers in 5xFAD mouse model of AD using immunohistochemical analysis. It was observed that oligomer levels peaked at around 6 months of age, before gradually declining as the animals progressed to beyond one year of age. This was consistent with the recruitment of soluble oligomers into complex insoluble diffused structures leading to increased retinal amyloid deposition with age (Habiba, 2020). A recent study revealed that the  $A\beta_{1-40}$  species is particularly enriched in the inner layers of the central region of the human postmortem retina (Shi et al., 2020). Evidence of increased  $A\beta$  deposits in retinal regions that are particularly rich in rod cells, means that these could influence contrast sensitivity and visual motion perception changes observed in AD subjects (Koronyo et al., 2017; Risacher et al., 2013). Changes in retinal blood flow and blood-vessel diameter, choroidal changes, tissue permeability, and variations in light exposure, are some of the factors that could further influence  $A\beta$  aggregation or its clearance from specific regions of the retina.  $A\beta$  deposition in AD patient retinas was further shown to correspond to the loss of melanopsin-containing RGCs, the cells of which have been shown to play an important role in regulating circadian rhythm (La Morgia et al., 2016). This selective loss of photosensitive RGCs could decode the mechanistic basis of circadian sleep- cycle disruption and

visual field defects that underlie AD, even in the early stages (Ju et al., 2013). The retinal  $A\beta$  pathology and the unique pattern of its deposition has also been shown to occur concomitantly with brain amyloid pathology (Hadoux et al., 2019; Koronyo et al., 2017).

Apart from changes in the neurosensory and vascular retina, some studies have also documented the detection of  $A\beta$  peptides and protein aggregates in other ocular regions, such as the lens, vitreous humor, corneal epithelium and choroidal tissues in human and animal studies (Dong et al., 2018; Goldstein et al., 2003). Investigating these changes along with tear film analysis has been gaining traction, however larger sample sizes will be required to obtain meaningful results. A similar deposition of  $A\beta$  in the lens has been observed in cases of Down's syndrome (Moncaster et al., 2010). Down's syndrome patients possess three copies of APP gene which results in  $A\beta$  over-production, and studying molecular pathological changes in these patients could help understand the effects of  $A\beta$  on the eyes (Moncaster et al., 2010). The structural and functional ramifications of  $A\beta$  aggregation in the retina in AD, as well as in other neurodegenerative disorders of the retina and eye, are currently poorly understood. However, the deleterious effects of  $A\beta$ —including protracted synaptic transmission, dendritic network remodeling of cholinergic amacrine cells, and inadequate levels of acetylcholine—are believed to be some of the key pathological changes related to AD (Reed et al., 2017). While these ancillary indicators are shared by several other neurodegenerative diseases, these molecular clues could reflect the advancement of AD and aid-in clinical stratification of the disease.

## 2.2. Neuropathological features of tau in retina

In addition to amyloid deposition, AD pathology typically involves increased amounts of pTau in neuropil filaments, neurofibrillary tangles, and neuritic plaques, primarily along cerebral cortical stretches (Brettschneider et al., 2015; Gibbons et al., 2019). Tau is a heterogenous



**Fig. 4.** Tau phosphorylation in the retina. (A) Representative staining of phosphorylated tau using AT-8 antibody in human postmortem AD hippocampus and superior region of AD and control retinas. Reused from (den Haan et al., 2018c) under the Creative Commons Attribution 4.0 International License: [creativecommons.org/licenses/by/4.0/](https://creativecommons.org/licenses/by/4.0/) (B) Human retinal section from human AD tissue demonstrating increased pTau labelling (green-pTau, AT-100 antibody; blue-hoechst). Scale = 20  $\mu$ m. (C) Quantification indicating increased fluorescent signal/field of view for pTau staining,  $n = 38/6$  fields/patients. (D) High magnification image of pTau labelling in human retina with TUJ1 (red), which is an RGC specific marker. Reused from (Grimaldi et al., 2019) under the Creative Commons Attribution 4.0 International License: [creativecommons.org/licenses/by/4.0/](https://creativecommons.org/licenses/by/4.0/). Scale = 20  $\mu$ m. IL, inner layer and OL, outer layer, of the retina. (E) pTau Ser404 (red) levels (white arrow) were elevated in APP/PS1 retinal ganglion cell layer compared to the WT eyes. Scale = 50  $\mu$ m. Reused with permission of Springer Nature for Mol Neurobiology, 2019, 56, pages 6017–6034 (Mirzaei et al., 2019b).

group of microtubule-associated proteins derived through alternative splicing of *MAPT* and is abundantly expressed in the neurons in CNS. The protein isoforms range in length from 352 to 441 residues, with 79 Ser and Thr sites that can potentially undergo phosphorylation by Erk, GSK3 and CDK5, out of which approximately 38 phosphorylated sites have previously been reported in AD patients (Hanger et al., 2007; Martin et al., 2013). The hyperphosphorylation of tau proteins reduces their ability to interact with and bind to microtubular proteins (Lathuiliere et al., 2017). Increased cortical tau as assessed by tau-PET and enhanced p-Tau levels in CSF can be useful AD biomarkers as per AT(N) scheme. CSF total tau level is also one of the biomarkers for neurodegeneration in AD brain (Jack et al., 2018).

Within the retina, the tau protein is expressed in layers enriched with axonal connections, such as the inner and outer plexiform layers (IPL and OPL). OPL is composed of fibres and synaptic reticulum formed by interactions between photoreceptors and cells in INL. IPL in contrast is much wider and is comprised of GCL dendrites interlacing with INL neurons. In AD, increased tau phosphorylation has been observed in

these layers in comparison to normal retinal tissues. pTau and the staining of tau paired helical filaments, in addition to microglial activation, RGC loss, and the impairment of retinal function, have been reported in 3xTg-AD and APP/PS1 animal models of AD (Chiasseu et al., 2017; Grimaldi et al., 2018; Gupta et al., 2016b) (Fig. 4). In addition, authors have also shown increased pTau immunoreactivity within the inner retinal layers of human AD postmortem tissue using different antibodies (den Haan et al., 2018c). This staining also co-labelled with RGC marker, TUJ 1 which is 50 kDa neuron specific  $\beta$ 3 tubulin, further indicating that these cells are prominently affected in the disease process (Grimaldi et al., 2019) (Fig. 4). Similar to that observed for A $\beta$  deposition, only moderate cytoskeletal pathology related to pTau has been observed in the retina of AD patients (den Haan et al., 2018c). While significant NFTs, neuropil threads, or plaque formation are typically seen in the brain, much smaller and diffused protein deposits have been observed in the retinas of AD patients. The pTau increase also tends to be more localised in the superior and peripheral regions of the retina relative to the medial areas (den Haan et al., 2018c). Similar to the

findings from human studies, total tau protein expression was not found to be significantly altered in the APP/PS1 mouse retina, even though significant increases in the levels of pTau (Ser404) were noted (Mirzaei et al., 2019b). Increased pTau in APP/PS1 animals has also been shown to correspond to levels of the protein in the CSF in 6-month-old mice (Chiasseu et al., 2017). Interestingly, while increased pTau reactivity has been reported around A $\beta$  deposits in the brain (Ittner and Gotz, 2011), not much is known about their relative localization within the retina, however, increased levels of A $\beta$  have been reported in the GCL while pTau reactivity in addition to the GCL has also been observed in IPL and OPL layers of the retina. The accumulation of A $\beta$  and pTau aggregates in the retinal tissues of both human AD patients and mouse models has been reported by some labs (Grimaldi et al., 2018, 2019; Gupta et al., 2016b; Koronyo et al., 2017; Zhao et al., 2013). It is important to mention that there are also studies that have been unable to replicate neuropathological A $\beta$  deposition in the retina (den Haan et al., 2018c; Ho et al., 2014; Schon et al., 2012; Williams et al., 2017). Therefore, caution is warranted against generalizations, as changes in A $\beta$  and tau phosphorylation could also be caused by ageing or other retinal diseases that elicit overlapping molecular pathologies, including for example glaucoma (Gupta et al., 2008; Mirzaei et al., 2019b). Further studies involving different neurodegenerative diseases will enhance the accuracy and specificity of utilizing retinal changes in amyloid deposition and tau phosphorylation to detect AD.

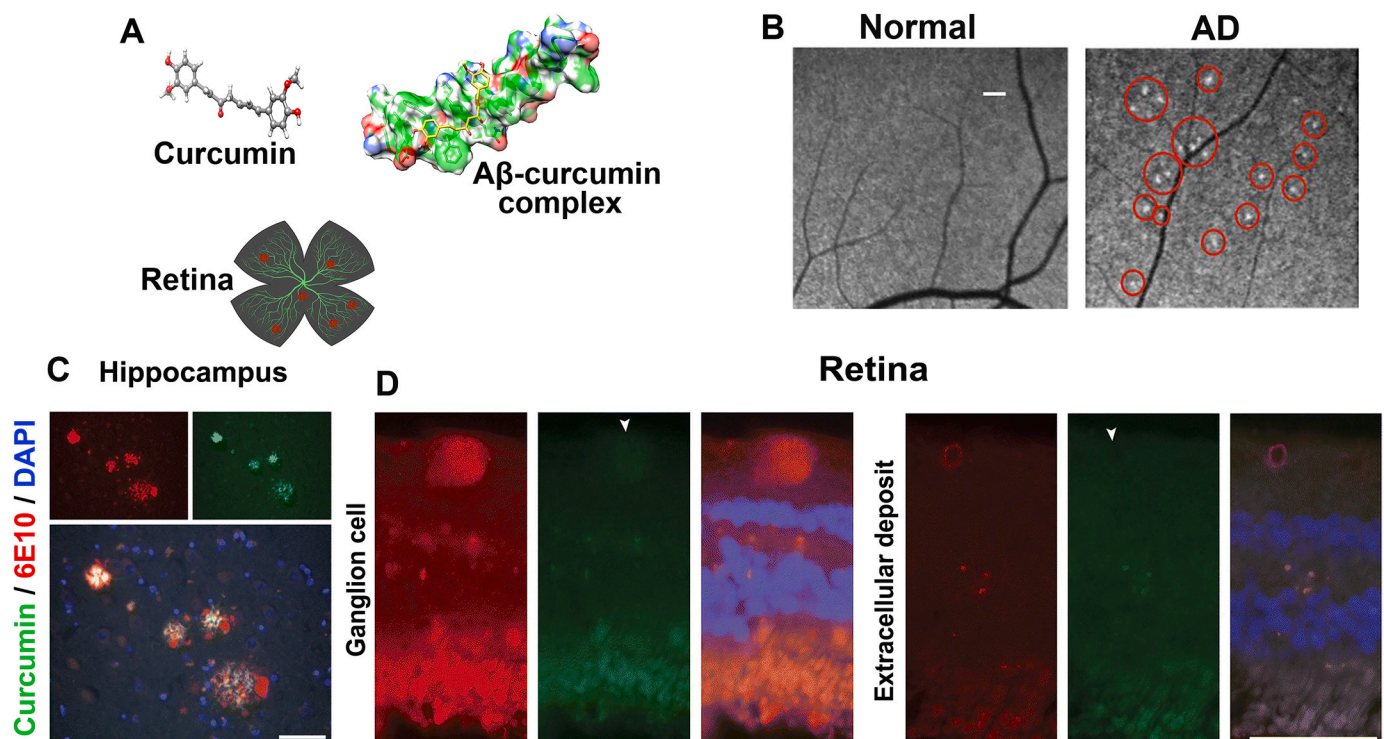
### 2.3. Molecular imaging and the identification of AD markers in retina

In the last decade scientists have increasingly focused on investigating retinal changes in AD using various molecular imaging technologies. The reports of diffused protein aggregates and fibrillar deposits in

the retina, suggests that the molecular signs of AD may overlap to a certain extent with the brain. In attempt to detect and monitor AD specific differences, studies have centered on both endogenous changes in the retina as well as the use of exogenous non-toxic staining agents, such as that can bind to A $\beta$ . The morphology of these deposits in the retina, however, is different from plaques in the AD brain and this may hamper visualization in similar ways that are used to detect brain deposits.

#### 2.3.1. Curcumin imaging of retinal AD changes

Curcumin, or diferuloylmethane, is a natural fluorescent polyphenol that is obtained from turmeric rhizome and exhibits an affinity for A $\beta$  aggregates (Fig. 5). Curcumin is a food constituent and considered to be safe for administration by US FDA. Chronic oral administration of curcumin formulation Longvida was shown to have beneficial effects on mood and cognition in older population (Cox et al., 2015). Furthermore, its specificity has been validated by co-labelling with specific monoclonal antibodies against amyloid  $\beta$  peptide (den Haan et al., 2018c; Koronyo et al., 2017). The compound has also been shown to efficiently cross both the blood–brain and the BRB and can thus reach retina when delivered systemically, however >99% is directly conjugated by the liver, so the circulating curcuminoids are either sulfates or glucuronides (den Haan et al., 2018b). Curcumin and its conjugates bind to  $\beta$ -pleated sheets of A $\beta$ , as well as its oligomers, fibrils and plaques with high affinity, and also stains PHF-tau neurofibrillary tangles to some extent (Mutsuga et al., 2012). More recently, the fluorescence imaging of amyloid deposits using curcumin–A $\beta$  interactions has been applied to image A $\beta$  deposits in the retina. The optical imaging of curcumin fluorescence in the retina was shown to juxtapose with A $\beta$  deposits in live retinal imaging of AD subjects as well as in post-mortem samples, thus



**Fig. 5.** Curcumin staining of the retinal amyloid (A) Schematic representation showing curcumin (ball and stick model) binding to A $\beta$  (space filled model). Binding of curcumin to A $\beta$  deposits leads to fluorescent signal from the retina. (B) Representative magnified images demonstrating retinal *in vivo* detection of curcumin spots in superior temporal region of human retina in healthy control and AD patient. Red circles highlight retinal spots attributed to curcumin-increased fluorescence. Scale bar: 400  $\mu$ m. Reproduced with permission of American Society for Clinical Investigation for JCI Insight. 2017 2(16): e93621, <https://doi.org/10.1172/jci.insight.93621>, (Koronyo et al., 2017); conveyed through Copyright Clearance Center, Inc. (C) Curcumin staining of human AD post-mortem brain (hippocampus) and retinal tissue sections. There is an intense signal in fibrillary plaques which co-stains with 6E10 in the hippocampus. In retina, significant curcumin staining was not evident although there was intracellular APP reactivity against 6E10 antibody. Scale bar 50  $\mu$ m. Reused from (den Haan et al., 2018c) under the Creative Commons Attribution 4.0 International License: [creativecommons.org/licenses/by/4.0/](https://creativecommons.org/licenses/by/4.0/).



making it a promising tool for monitoring AD pathology (Koronyo-Hamaoui et al., 2011; Koronyo et al., 2017). Following curcumin administration, Koronyo et al. (2011) demonstrated that A $\beta$  deposits were detectable in the 2.5-month-old APP/PS1 mice retina, which is much earlier than when A $\beta$  plaques are reported to be formed in the brain. In this study, they correlated the observed fluorescence changes with progressive brain pathology in APP/PS1 mouse model (Koronyo-Hamaoui et al., 2011; Koronyo et al., 2017). Curcumin staining followed by optical imaging of the whole mounted retinas revealed a two-fold increase in the amyloid intensity in human AD post-mortem in comparison to that of control samples, and the staining of A $\beta$  deposits was shown to correspond with the neuronal loss in the retina (Koronyo-Hamaoui et al., 2011; Koronyo et al., 2017). Subsequent studies revealed curcumin labeling within the retinas of living patients with amyloid depositions occurring mainly near the central and peripheral regions of the superior quadrant of the retina. The live retinal imaging of AD patients also exhibited a fluorescence pattern similar to that of the amyloid staining previously reported in human post-mortem retinas (Koronyo et al., 2017) (Fig. 5).

Axonal loss and NFL thinning in AD patients has been acknowledged previously, and mainly occurs in the superior regions of the retina that also demonstrate increase in amyloid pathology. Neuronal loss in the superior quadrant and the mid- and far-peripheral regions of the retina was initially observed by Blanks et al. (1996) (Blanks et al., 1996b). More recent investigations have demonstrated mRGC loss and A $\beta$  accumulation in the same superior quadrant region, supporting the prior work (La Morgia et al., 2016). Another study has reported that upon curcumin administration, patchy hypo-fluorescent signals were identifiable using fundus autofluorescence and OCT in the areas surrounding macula and vascular regions of the retinas of MCI patients (Kayabasi et al., 2014). Another group however has shown that while curcumin and 6E10 antibody co-stained amyloid deposits in the hippocampus, only 6E10 antibody positive APP/A $\beta$  staining was evident in the extracellular space in human postmortem AD retinal tissues (Fig. 3) (den Haan et al., 2018c). Studies at Alzheimer's Centre Amsterdam also indicate that amyloid deposition signal in the retina was not detected upon oral administration of Theracurmin, Novasol and Longvida curcumin formulations (unpublished data). The paucity of literature on this topic and conflicting observations emphasize that additional studies in different cohorts may be required to establish the sensitivity and specificity of retinal curcumin staining to achieve clinical utility in AD patients. In addition to the retinal imaging modality, infrared laser confocal quasi-elastic light scattering procedure and the fluorescent ligand eye scanning techniques (Kerbage et al., 2015) have ascertained amyloid pathology in the lens using extrinsic fluorescent dyes. However, cataracts and corneal pathologies can significantly confound lens imaging analyses for AD in elderly cohorts.

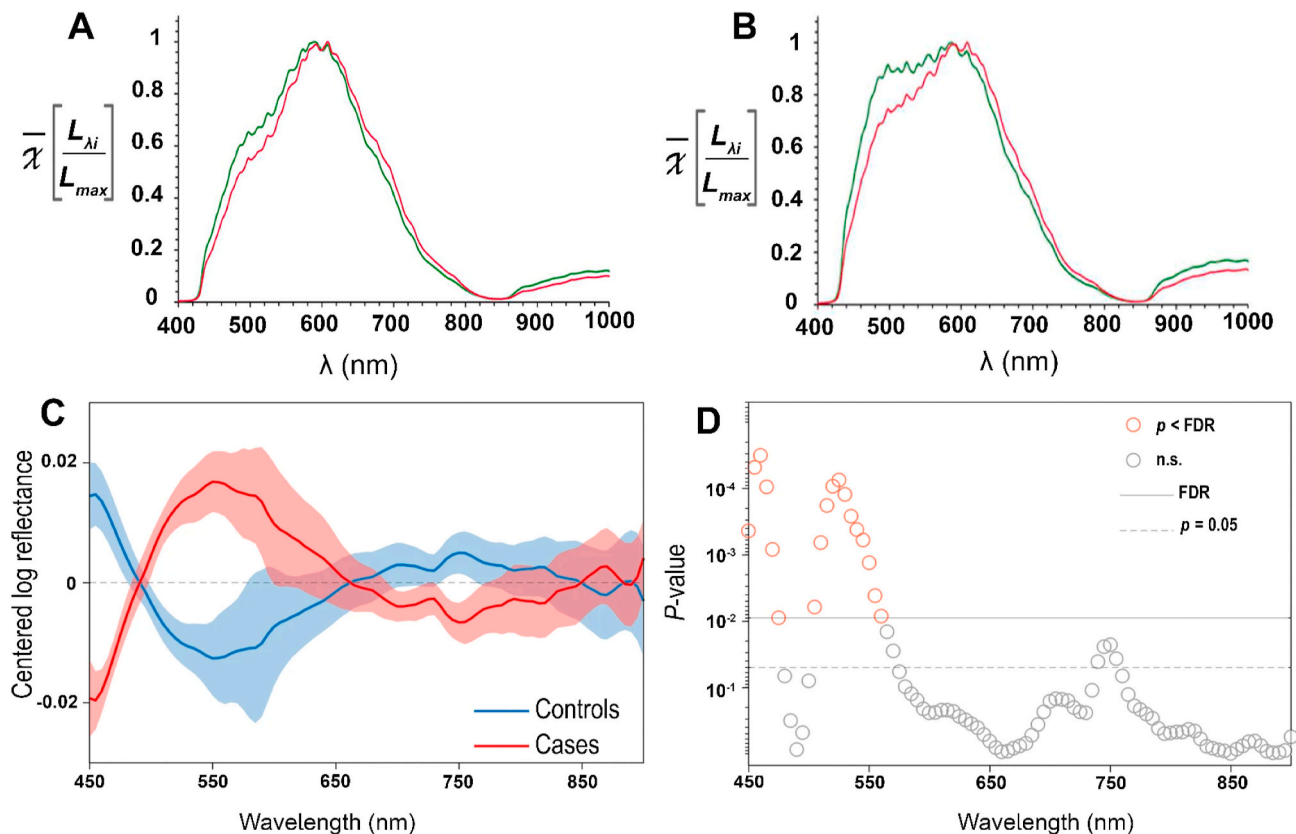
### 2.3.2. Hyperspectral imaging of retinal AD changes

More recently, there have been attempts to distinguish A $\beta$  deposition in the retina using hyperspectral scanning (HSI) (Hadoux et al., 2019; More and Vince, 2015; Sharafi et al., 2019). HSI does not require extrinsic fluorophore labelling and works by acquiring and analysing adjacent wavelength spectra within a given range. This technique takes advantage of the light scattering properties of small particles in tissue, which is governed by Rayleigh scatter principle. Optical and digital processing of the sequential HS images allows non-invasive discrimination of structural and biochemical changes in the tissues. In the retina, small soluble A $\beta$  oligomers are believed to contribute to an HSI signature most salient in the short visible wavelength spectrum. The proof-of-principle studies demonstrated that HSI spectral signatures from AD post-mortem brain tissue differed significantly in comparison to that acquired from normal age-matched individuals. Similar patterns of the spectral variation in wavelengths have also been observed between normal and A $\beta$ 1–42 peptide treated SHSY5Y cells (More and Vince, 2015). Interestingly, an analysis of retinal tissue samples from

normal and AD subjects offered similar differentiating results. Total wavelength scattering in samples from AD patients was diminished, suggesting its dispersal by protein aggregation neuropathology, or associated structural alterations. *Ex vivo* HS imaging of retinal tissues from a mouse model at different stages of the disease, supported these observations, with significant differences observed at 4 months, which increased exponentially at 6 months of age. At 8 months, APP/PS1 mice have some A $\beta$  plaque formation, and accordingly, discernible differences in HSI were further observed between the control and transgenic mice at this stage (More and Vince, 2015). Intriguingly, at 4 months of age, amyloid deposition is not evident in APP/PS1 mice brains, which suggests that the light scattering properties of small soluble A $\beta$  species preserves the HSI signature even in the absence of insoluble plaques, and this property makes this approach a potentially useful tool for early detection of AD (Fig. 6).

The translation of HSI technology to human *in vivo* imaging has proven to be challenging with significant inter-subject spectral variability. Hadoux et al. (2019) recently demonstrated that HS can discriminate between individuals who have high A $\beta$  load from those with less A $\beta$  load on cerebral PET scanning (Fig. 6). However, owing to a considerable inter- and intra-subject ocular reflectance variability within different regions of the retina, HSI data in its unprocessed form was not remarkably distinguishable between AD and control subjects. Following the normalization of the spectral features with known spectral interference caused by various proteins and pigments in the ocular tissues, spectral discrimination was observed between AD and control subjects, and results largely corresponded with the spectral profile of A $\beta$  in solution (Hadoux et al., 2019). The processed data was able to make a distinction between retinal milieu of AD and control subjects. Again, there was a significant degree of variation within the retina depending on which region was examined, and HS scores were particularly high and discriminatory in the superior and foveal regions between AD and control subjects. Although, the exact distribution of various A $\beta$  species and their production in the retina remains poorly defined, higher levels of A $\beta$  plaque-like formations have been reported in the superior quadrant previously (Koronyo et al., 2017). While the discriminatory signature of retinal HSI from human AD subjects and AD mice models likely arises from the accumulation of A $\beta$ , there are many other factors that complicate the scenario and could influence spectral shift such as metal ion accumulation, changes in pTau, inflammatory processes, and various other structural and biochemical changes could play a role (Chiasseu et al., 2017; Gupta et al., 2005). Although it is also possible that changes in vascular tortuosity and anterior segment tissues affect the spectral measurements of the retina; wavelengths in the range of 700–900 nm also exhibited significant differences (Sharafi et al., 2019). Due to the increased tissue penetrance afforded by the longer wavelengths of near infrared light, it is less likely to have been significantly affected by ocular tissues in the anterior segment. Broadly, this emerging imaging application is not without drawbacks, as a combination of intertwined biochemical changes and structural variations could alter the hyperspectral signal. These findings warrant further investigation for a clear understanding of the mechanisms and their validation in different cohorts. A few other studies have also noted localized fundus auto-fluorescence signals using SD-OCT from at-risk AD subjects, that positively correlated with amyloid  $\beta$  florbetapir-PET imaging scores, further supporting the hypothesis that the retinal changes in AD might be associated with brain pathology (Snyder et al., 2016).

The chronic effects of A $\beta$  accumulation on neuronal cell death in the retina and impact of cellular loss on intrinsic or exogenous fluorophore mediated imaging are not known. The imaging of ganglion cell death in real time in glaucoma patients, as well as in glaucoma and AD animal models, has been recently demonstrated (see below) and some effects of these degenerative changes could contribute to the aforementioned differences (Cordeiro et al., 2017). Notwithstanding, ongoing optical, and analytical software developments in HSI camera technology will refine its sensitivity and specificity to detect AD changes. This approach



**Fig. 6.** Amyloid imaging in the retina in AD (A) Hyperspectral imaging waveform scatter plots ( $\bar{\chi} \left[ \frac{L_{\lambda_i}}{L_{\lambda_{max}}} \right]$  vs  $\lambda$ ) obtained from human control (green) and AD (red) retinal tissues demonstrate remarkable differences between 450 and 580 nm. APP/PS1 (red) mice retinal HSI waveform at (B) 8 months of age, demonstrate progressive spectral differences between 480 and 560 nm (green- WT).  $L_{\lambda_i}$  and  $L_{\lambda_{max}}$  represent emergent intensity at the  $i$ th and maximally intense wavelength, respectively. Reproduced with permission from ACS open access article: <https://doi.org/10.1021/cn500242z> (More and Vince, 2015). Further permissions related to the material excerpted should be directed to the ACS. Spectral difference between control and AD patient groups with (C) representing corrected reflectance spectra in the superior retina ( $n = 20$  controls,  $n = 15$  cases, mean  $\pm$  SEM). (D)  $P$  values for two-sided unpaired  $t$  tests between groups using false discovery rate (FDR) control for significance across all the wavelengths (n.s. - non-significant). Reused from (Hadoux et al., 2019), under the Creative Commons Attribution 4.0 International License: [Creativecommons.org/licenses/by/4.0/](https://creativecommons.org/licenses/by/4.0/).

has the potential to screen individuals in combination with other biomarkers of disease to increase the predictive power. It could also likely find applications in studying intrinsic wavelength signature differences in other ocular disorders, such as glaucoma and AMD.

### 2.3.3. Imaging of cellular apoptotic changes

Apoptotic activation and cell death constitute the key pathological drivers for neuro-degenerative processes in AD. Hence, cell death markers have been the subject of intense research and development to track apoptotic cell imaging within the retina. Novel techniques to identify cells undergoing apoptosis in the retina has the potential to not only help to diagnose the disease much earlier than in the brain, but can also provide valuable insights to the molecular mechanisms by which apoptosis may affect neuronal loss in AD, and how these stages may be targeted by future therapeutic agents. For example, externalisation of membrane phospholipid phosphatidylserine (PS) in apoptotic cells has emerged as a promising early marker for cell death. PS is able to bind with Bis(zinc(II)-dipicolylamine) (Zn-DPA) compound (Kwong et al., 2014). NMDA induced toxicity studies have shown that intravitreal administration of Zn-PDA- fluorescein conjugates successfully detect apoptotic cells during live retinal imaging (Kwong et al., 2014). This technique can also identify RGC apoptosis in rodent models much earlier than changes in DNA fragmentation (Kwong et al., 2014; Mazzoni et al., 2019). Recently, Zn-PDA conjugated with a Texas-red fluorochrome (PSVue-550) was able to detect apoptotic photoreceptor cells when instilled *via* eyedrops (Mazzoni et al., 2019). Retinal

electrophysiological studies further revealed no significant functional changes in the administered eyes, indicating that the conjugate was pharmacologically safe whilst eliminating the potential side-effects caused by repeat intravitreal injections (Mazzoni et al., 2019). Similar to Zn-PDA, the radio- labelled annexin-5 protein when administered intravenously, efficiently labelled the RGCs undergoing apoptosis both in glaucoma patients and in animal models of glaucoma and AD (Cordeiro et al., 2010, 2017). Fluorescently labelled annexin-5 interacted with apoptotic RGCs in various injury models and was effectively tracked by real-time imaging with scanning laser ophthalmoscopy (Cordeiro et al., 2004). This approach was also exemplified in a triple transgenic model of AD, whereby retinal apoptosis was observed in its various phases ranging from early to late apoptosis and necrosis (Cordeiro et al., 2010). This detection of apoptosing retinal cells (DARC) using annexin-5 has since been translated to human studies in phase I clinical trial and initial proof-of-concept studies demonstrate that intravenous annexin-5 labelled with fluorescent dye (ANX776) is pharmacologically safe and well tolerated in glaucoma patients (Cordeiro et al., 2017). Similar approaches may also be useful in monitoring early cellular degenerative changes in the retina in AD patients. Akin to annexin-5, propidium iodide (PI) dye can also differentiate apoptotic and necrotic neuronal cell populations in an animal model of focal ischemic stroke (Bahmani et al., 2011). These *in vivo* imaging advancements to track changes in early cell death markers suggest that cellular degenerative changes in AD can potentially be detected and monitored in the retina much more effectively than is possible in the

brain. When combined with A $\beta$ /HSI in future, this technology can potentially correlate region-specific changes with localization of apoptotic cells. The initial studies on various molecular retinal imaging approaches though promising, need refinement and validation in independent cohorts to be established as reliable AD biomarkers.

### 3. Neurodegenerative changes in the retina in AD

#### 3.1. Retinal structural changes in AD patients

Since initial reports that highlighted the loss of RGCs, and particularly melanopsin expressing RGCs (mRGCs) in AD (Sadun and Bassi, 1990; Blanks et al., 1989), several studies have published findings that support the degenerative impact of AD on the inner retinal laminar architecture, including the loss of RGCs in the foveal and para-foveal regions (Blanks et al., 1996b). These findings were supported by post-mortem studies, which revealed a loss of approximately one-third of all neurons in the retina, particularly distributed in the superoinferior axis, with a loss of approximately one half in the mid-peripheral region, and the greatest losses within the inferior peripheral regions of the retina (Blanks et al., 1996a). Since the initial structural changes in the retina reported in AD subjects using cross-sectional OCT imaging studies (Parisi et al., 2001), there have been tremendous improvements in OCT technologies, which now provide better resolution and analysis algorithms for layer segmentation *in vivo*. Significant thinning of both the naso-temporal and superoinferior regions of the RNFL in AD subjects, in addition to the thinning of the inner and outer macular rings was observed (Ascaso et al., 2014). Other reports indicate retinal changes that are predominantly focused on the superior and inferior regions of the RNFL (Doustar et al., 2017; Lu et al., 2010). Another report has indicated the loss of the GCL and IPL, the preferential thinning of the superior and inferior quadrants of the RNFL, as well as the thinning of the peripapillary region of the RNFL, where RGC axons converge in early AD subjects (Lopez-de-Eguileta et al., 2019). This study suggested that RNFL, IPL and GCL changes might be useful for AD diagnosis, however Bruch's membrane opening–minimum rim width (BMO-MRW) remained unchanged. Thus, advancements in ocular imaging have provided evidence of inner retinal thinning and loss of the retinal nerve fiber layer (RNFL) in AD and its preclinical and prodromal stages, although some studies have also suggested a non-significant relationship between the effects of AD and changes in retinal imaging by OCT (den Haan et al., 2019; Haan et al., 2019a; Sanchez et al., 2020; Sanchez et al., 2018). An initial meta-analysis concluded that there was a significant RNFL thinning in early stages of AD (Knoll et al., 2016). Another meta-analysis of 887 AD, 216 MCI and 864 control subjects from 25 different studies revealed reduced macular thickness in AD subjects and peripapillary RNFL thinning in AD and MCI subjects compared to the controls (den Haan et al., 2017). More recently, a further meta-analysis of 30 cross sectional studies that included 1257 AD, 305 MCI and 1460 control cases, supported these observations and indicated peripapillary RNFL loss and choroidal thinning, in addition to macular changes such as GC-IPL and ganglion cell complex (GCC) deficits and loss of macular volume and thickness, in MCI and AD subjects (Chan et al., 2019). Overall, these studies indicate that retinal monitoring to detect changes in RNFL and macula GCC may be an important additional measure to assess disease progression when combined with other assessments; but the differences are expected to be small, and may not be directly useful in clinical practice.

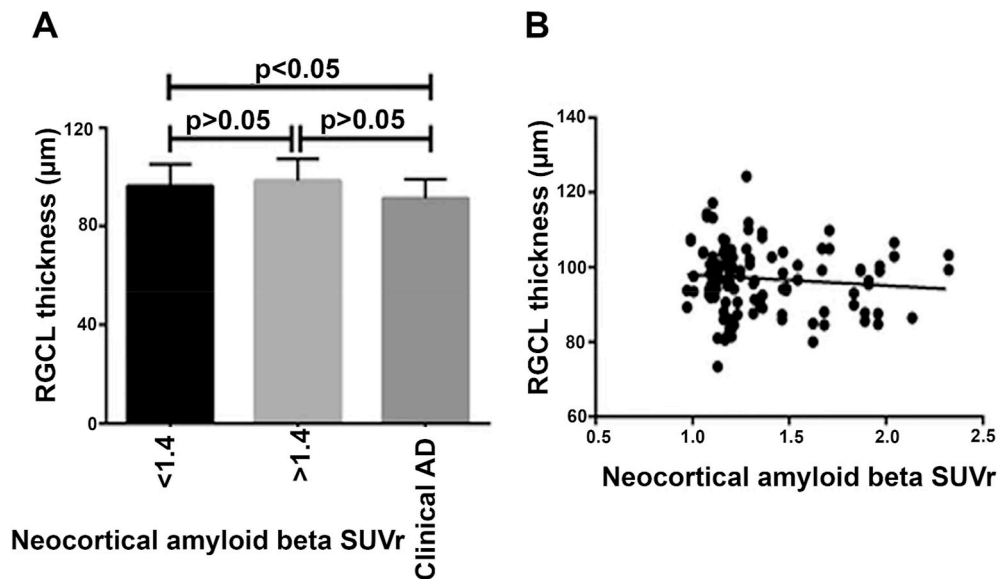
Retinal changes in patients with AD and MCI have been demonstrated to correlate with neuropsychological changes. Significant loss of the thickness of the RNFL and GCL-IPL complex was observed in subjects with MCI and AD, which was found to correlate with mini mental state examination (MMSE) scores (Ferrari et al., 2017). MMSE is a commonly used clinical test to assess cognitive function. MMSE defects implicate that changes in retinal and brain pathologies could show congruence to some extent (Liu et al., 2015). Other studies have corroborated this and

shown that changes in MMSE were significantly correlated with the losses in superoinferior regions of the RNFL and average peripapillary RNFL thickness (Cunha et al., 2017a). These changes in cognitive parameters were concomitant with macular changes, such as changes in average macular thickness and GCL-IPL loss (Cunha et al., 2016b, 2017a). Other studies have added to the growing body of evidence and reported similar correlations between changes in MMSE and values for RNFL thickness in various regions of the retina in AD and MCI patients (Oktem et al., 2015; Shen et al., 2014). For instance, a potential association between certain episodic memory changes and RNFL thickness in MCI was observed, particularly in the inferior quadrant region of the retina (Shen et al., 2014). The involvement of the macular region was further supported by findings that MMSE scores, which reflect cognitive impairment in AD subjects, correlated with the loss of macular volume (Iseri et al., 2006). In agreement with previous cross-sectional reports, the correlation between neuropsychological changes and defects detected *via* retinal imaging was established in a one-year longitudinal study. This study provided evidence that shifts in peripapillary RNFL thickness were concomitant with progressive changes in clinical dementia rating (CDR) and AD assessment scale-cognitive subscale (ADAS-Cog) tests (Trebbastoni et al., 2016). A UK Biobank, three year longitudinal cohort study also found that changes in RNFL thickness in OCT scans were associated with cognitive decline as measured with prospective memory, pairs matching, reaction time and reasoning based analysis (Ko et al., 2018). Thus, there is evidence for a correlation between specific inner retinal changes and cognitive decline in cases of AD, supporting the theory that retinal changes may be related to CNS pathologies. Our research team also observed a significant difference in retinal GCL thickness in a cross-sectional study of control, pre-clinical AD, and clinical AD groups (Golzan et al., 2017). The association between changes in retinal GCL thickness and neocortical A $\beta$  standardized uptake value ratio (SUVr) in PET scans in preclinical AD subjects was found to be not significant. Similarly, the correlation between RNFL thickness and neocortical A $\beta$  standardized uptake value ratio in the control and preclinical cohort was not significant. There was, however, some decrease in RGCL thickness corresponding to the macular region in clinical AD cases in comparison to the control and preclinical AD subjects (Fig. 7).

As mentioned above, although spectral domain OCT-based techniques are promising, they lack specificity for AD, as the thickness of various retinal layers is highly variable in the normal population and is also affected by other age-related neurodegenerative disorders of the eye and the brain such as age related macular degeneration (AMD), glaucoma (Gupta et al., 2016a), demyelinating optic neuritis, multiple sclerosis (MS), and Parkinson's disease (PD) (Moreno-Ramos et al., 2013; You et al., 2018). Patients with frontotemporal dementia also have been shown to exhibit a significant reduction in peripapillary RNFL thickness, similar to that reported in AD patients (Ferrari et al., 2017). Retinal parameters could also be secondarily altered in vascular disorders such as diabetes or hypertension (Cheung et al., 2017; Ng et al., 2016). Therefore, the detection of additional effect of AD is likely to be complicated by several factors, particularly in cross-sectional studies. Longitudinal measurements hold the promise of measuring the effects of diseases while minimizing statistical variations, but concurrent pathology may complicate interpretation. Investigations into the distinct effects of AD on specific regions of the retina is likely to enhance the clinical value of OCT in disease diagnosis.

#### 3.2. Functional changes in AD patient retinas

In addition to the documented laminar structural changes in various studies, retinal functional deficits have also been reported in AD patients. Significant delays in latency, which indicate a disruption in signal processing and decreased amplitude, were observed in various components of pattern electroretinogram (pERG) and were correlated with overall changes in the thickness of the RNFL in AD patients (Katz et al.,



**Fig. 7.** Retinal ganglion cell layer changes in AD subjects. (A) Graph representing correlation between GCL thickness and standardised uptake value ratio (SUVR) in control, preclinical AD and clinically diagnosed AD subjects. (B) Association of SUVR values obtained from control and preclinical AD subjects is plotted against GCL thickness. Reused from (Golzan et al., 2017) under the Creative Commons Attribution 4.0 International License: [Creativecommons.org/licenses/by/4.0/](https://creativecommons.org/licenses/by/4.0/).

1989; Krasodomska et al., 2010; Parisi et al., 2001). pERG provides an objective measure of central retinal and ganglion cell function through repeated checkerboard or grating stimulation. Visual evoked potential (VEP) assessments provide a measure of the integrity of the entire visual pathway and ability of cortical regions to efficiently detect and interpret visual stimuli (You et al., 2012). Thus, while another study found significant thinning of parapapillary and macular RNFL, no evidence of the latency shift or amplitude changes of VEP P100 component was observed, indicating that cortical and optic nerve function may not be significantly affected in AD subjects despite RNFL losses (Iseri et al., 2006). These differences in pERG and VEP support the premise that AD might affect specific cells and regions along the visual pathway, and these effects may potentially be elucidated through comprehensive longitudinal studies. The findings further indicate that visual dysfunction in AD patients may not necessarily stem from cortical pathology but could instead be a direct outcome of retinal abnormalities or the combined effect of changes in both the retina and the brain (den Haan et al., 2019). Improvements in the sensitivity of clinical electrophysiology testing will enhance its applicability to detect relatively small changes in AD patients. While information about other functional changes that can be detected via electrophysiological measurements is limited, it can offer useful insights into the neuro-retinal effects of AD.

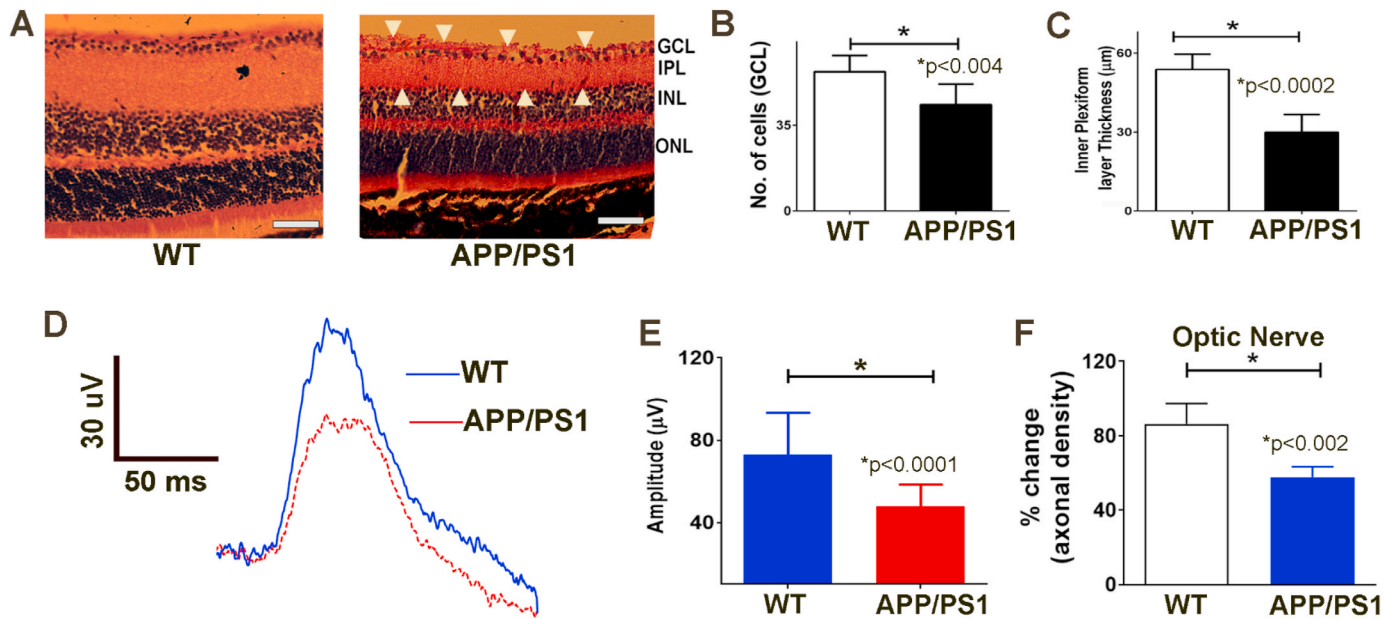
Ocular disturbances and visual dysfunctions including deterioration of contrast sensitivity, visual acuity, and declining color vision have also been reported (Chang et al., 2014; Cronin-Golomb and Dementias, 2011; Tzekov and Mullan, 2014) and shown to correlate with measurements of spectral domain OCT in AD patients (Polo et al., 2017). This was supported by evidence that the superior quadrant loss of RNFL was associated with loss of contrast sensitivity vision (CSV) and reduced color vision in AD subjects. Decreased color vision has been shown to associate with changes in macular volume, while visual acuity at various levels of contrast is associated with both macular and RNFL thickness deficits (Polo et al., 2017). In contrast, other studies argue that color sensitivity may not be a reliable factor on its own in AD (Chang et al., 2014). Visual field constriction has been linked to the severity of AD (Chang et al., 2014), however, the caveat is that the visual field performance may also become impaired in more severe AD cases due to lack of concentration and not just sensory loss.

Additionally, deficits in motion perception and sensitivity owing to potential adjustments in the magnocellular visual pathway have been

suggested to occur in patients with AD (Chang et al., 2014). Reduced depth perception and stereopsis that are at times observed in AD patients have also been linked to cognitive impairment (Chang et al., 2014). Also, deviations in saccadic eye movement, which reflect oculomotor disturbances, reiterate the effects of AD on the eyes independently of sensory retinal functions (Crawford et al., 2015). Furthermore, while changes in pupil size and photo-pupillary reflexes have been well documented in AD (Chang et al., 2017; Fotiou et al., 2007), their specificity in disease needs to be established, as similar deficits are also common in elderly people and in PD patients (Wang et al., 2016).

### 3.3. Retinal structural and functional changes in animal models of AD

Animal models of AD illustrate deficits in inner retinal thickness and electrophysiology. Our studies have revealed that APP/PS1 mice exhibit increased levels of soluble and aggregated forms of A $\beta$  in their retinas (Fig. 8) (Gupta et al., 2016b). APP/PS1 is a mouse model of AD that expresses human APP transgene with Swedish mutation, which involves a double mutation involving Lys670Met and Asn671Leu sites along with Leu166Pro mutation in PSEN1 gene. The expression of both these transgenes is regulated under the control of Thy1 promoter (Radde et al., 2006). Recent studies have demonstrated aggregation of A $\beta$  in the endoplasmic reticulum and its neurotoxic effects (Meli et al., 2014), as well as the formation of neuritic plaques in the extracellular space from degenerating neurons. A diminution of the neuronal density in the GCL, as well as a significant thinning of the IPL, was observed in 13-16-month-old APP/PS1 in our study, indicating that the inner retina was preferentially affected in these animals. Increased TUNEL staining—which is an indication of cells undergoing apoptosis—was also observed in the inner retinal layers (Gupta et al., 2016b). An increase in the expression of the microglial/inflammatory F4/80 cell surface glycoprotein antigen and monocyte chemoattractant protein-1 in the GCL of APP/PS1 animals has also been reported in other studies (Gupta et al., 2014b; Perez et al., 2009). Consistent with this, optic nerve sections have been shown to exhibit a reduction in axonal density in APP/PS1 mice in Bielschowsky's silver staining, while a reduction in retinal thickness has previously been described in a Tg2576 AD mouse model (Liu et al., 2009). Interestingly, there are growing reports of increased IPL thickness in the early stages of AD, and one mechanism to explain this paradoxical inflation is the increased neuroinflammation in



**Fig. 8.** Retinal structural and functional changes in APP/PS1 mouse model of AD (A) Hematoxylin and Eosin (H and E) staining of WT (Left) and APP-PS1 (Right) mice depicting inner retinal thinning (arrows). Quantification of the (B) GCL density and (C) thickness of the inner plexiform layer. Retinal electrophysiological changes in animal models of AD (D, E) A significant decline in inner retinal function in the APP-PS1 compared to age matched WT animals was observed. (F) Bielschowsky's silver staining of optic nerve and its quantification revealed reduced axonal density in APP/PS1 compared to WT mice. Scale 20  $\mu\text{m}$ . Data reused with permission from (Gupta et al., 2016b), doi.org/10.1016/j.neulet.2016.04.059.

the synaptic layers of the retina (Liu et al., 2019; Snyder et al., 2016). These changes however are reduced with disease progression and completely reversed in late stage AD where a thinning is observed. This is in agreement with reports that nearly one-third of the A $\beta$  plaques are invariably identified in the INL, resulting in a significant decrease in IPL thickness in end-stage AD models (Fig. 8C) (Perez et al., 2009). A $\beta$  deposition in the GCL could further explicate ganglion cell degeneration and the abnormal ERG patterns reported in rodent models of AD (Gupta et al., 2016b). The INL is principally composed of cell bodies involved in the vertical transmission of information from photoreceptors *via* their dendrites and axonal connections. Hence the accumulation of A $\beta$  in these segments can disrupt their normal function, impacting on synaptic transmission and ultimately lead to a decrease in the amplitudes of inner retinal electrophysiological responses observed in mice models of AD. Postsynaptic density protein 95 (PSD-95) which is located in the post-synaptic axonal regions, showed reduced density in AD and epigenetic editing of the gene rescued cognitive deficits in APP/PS1 mice (Bustos et al., 2017). The protein was also shown to be reduced in RGCs in microbead induced glaucoma models indicating synaptic loss (Williams et al., 2016). In ageing APP/PS1 mice, the degenerative changes in the RGC dendritic arbour were observed to precede cell loss (Williams et al., 2013). The accelerated RGC dendritic atrophy and pruning is likely attributed to the deposition of A $\beta$  and other protein aggregates in proximity to synaptic junctions and axons. As a consequence of retinal A $\beta$  deposition, amplitudes of positive scotopic threshold response (pSTR), which is an important element of the dark-adapted ERG were observed to be reduced in APP/PS1 mice. pSTR peak arises at approximately 120 millisecond after very dim light stimulus and primarily reflects inner retinal function in rodents (Bui and Fortune, 2004; Gupta et al., 2014b, 2016b). STR is considered to be a predominantly RGC-driven component and deficits have previously been reported in human glaucoma as well as in primate models of optic nerve injury (Frishman et al., 1996; Korth et al., 1994). APP/PS1 mice between the ages of 13–16 months were shown to exhibit significant pSTR differences with amplitudes reduced to approximately half in comparison to wild type mice (Fig. 8D). Additional evidence of electrophysiological deficiencies in AD pathology comes from animal models, with abnormal

flash VEP measurements reported in APP/PS1 mice (Gao et al., 2015a).

Observed reductions in a-waves which represent rod cell function, and b-wave amplitudes which primarily represent bipolar cells and other interneurons have been reported in other studies and are suggested to be affected by A $\beta$  accumulation (Ning et al., 2008). Interestingly, we detected that APP/PS1 animals have slightly elevated intraocular pressure (IOP)  $12.1 \pm 0.86$  mmHg in APP/PS1 mice vs  $9.8 \pm 0.67$  in WT animals. This could potentially be elicited by nucleation of A $\beta$  aggregates and their deposition in the trabecular meshwork and interconnecting blood vessels, which can impede the outflow facility. However, the exact underlying cause of IOP elevation, or its impact on retinal changes in these animals, remains unclear (Gupta et al., 2016b).

#### 4. Retinal vascular changes in AD

Epidemiological information has suggested a role for vascular involvement in the pathophysiology of AD (Bell and Zlokovic, 2009). Various examples of vascular pathology have been described at post-mortem in approximately 75% of all AD cases (van der Flier et al., 2018); while approximately 85–95% of patients demonstrate substantial A $\beta$  deposition in blood vessels, as well as demonstrate other vascular abnormalities in the brain (Viswanathan and Greenberg, 2011). These vascular changes include chronic ischemia of various sized vessels, lacunar infarcts, atherosclerosis, and widespread cerebral amyloid angiopathy associated with microhemorrhages (Charidimou et al., 2017). A broad array of research has established an association between the cardiovascular parameters of arterial blood pressure and markers of arterial stiffness including, pulse wave velocity and pulse pressure, arterial stiffness, reduced endothelial cell response to stress, carotid intimal-medial width, on the one hand, and declining cognitive function on the other (Hajjar et al., 2016; Zeki Al Hazzouri et al., 2013). Thus, there is a considerable interaction between AD and cerebrovascular disease and due to overlapping symptomatology it may be at times, difficult to clinically differentiate AD from mixed dementias. The differential effects of mixed dementias on the retina are not known, however, it is acknowledged that concomitant pathology may have additive or synergistic ocular effects and make the interpretation challenging.

Once a clear validation of the scope of vascular changes in AD is established, it can be incorporated as a potential diagnostic measure to the NIA-AA research framework and scheme could likely be updated as ATV(N) (Jack et al., 2018).

Multiple groups have actively pursued the potential correlation of AD-associated changes in the brain with various aspects of static and dynamic vascular parameters. Emerging evidence alludes that parallel vascular alterations in the retina could be indicative of the initial neurovascular dysfunction observed in AD. A wide range of abnormalities—including constricted retinal vessels with increased tortuosity, microinfarct development, atherosclerosis, amyloid angiopathy, endothelial cell dysfunction, reduced arterial fractal dimensions, and changes in branching patterns of vessels—have been reported in AD (Golzan et al., 2017; Lesage et al., 2009). Sharafi et al. (2019) recently showed that subjects with higher levels of A $\beta$  in the brain (A $\beta$ +) also exhibit considerably more retinal vein tortuosity in comparison to people with lower A $\beta$  scores in PET (A $\beta$ -) (Sharafi et al., 2019). In addition, reductions in blood flow and increased blood oxygen saturation levels, akin to those reported in the brains of patients with AD pathology, have also been documented in the retina (Fekete et al., 2015; Olafsdottir et al., 2018). The Rotterdam study initially launched in 1990s, identified a correlation between retinal vessel caliber and cognitive diminution, with data indicating that retinal venular widening is associated with an increased risk of vascular dementia (de Jong et al., 2011). Imaging studies involving the retinal fundus have also described increases in venous diameter and decreases in arterial diameter in conjunction with reduced fractal dimensions in AD subjects (McGrory et al., 2017). However, the arteriolar diameter of amyloid-positive subjects by PET was found to be higher than the amyloid-negative subjects in a zone adjacent to the optic nerve head (Sharafi et al., 2019). Another recent study that outlined the tightening of fractal dimensions of retinal arterioles in cases of vascular cognitive impairment did not identify differences between control and AD groups (Jung et al., 2019). Several studies have also described choroidal attenuation in cases of dementia *via* OCT enhanced depth scanning (Cunha et al., 2017b; Wong et al., 2011), thereby further corroborating the evidence of a relationship of vascular attenuation in AD. The visual disturbances in AD could also be attributed to the local atrophy of retinal and choroidal vessels or endothelial disintegration arbitrated by A $\beta$  toxicity (Berisha et al., 2007).

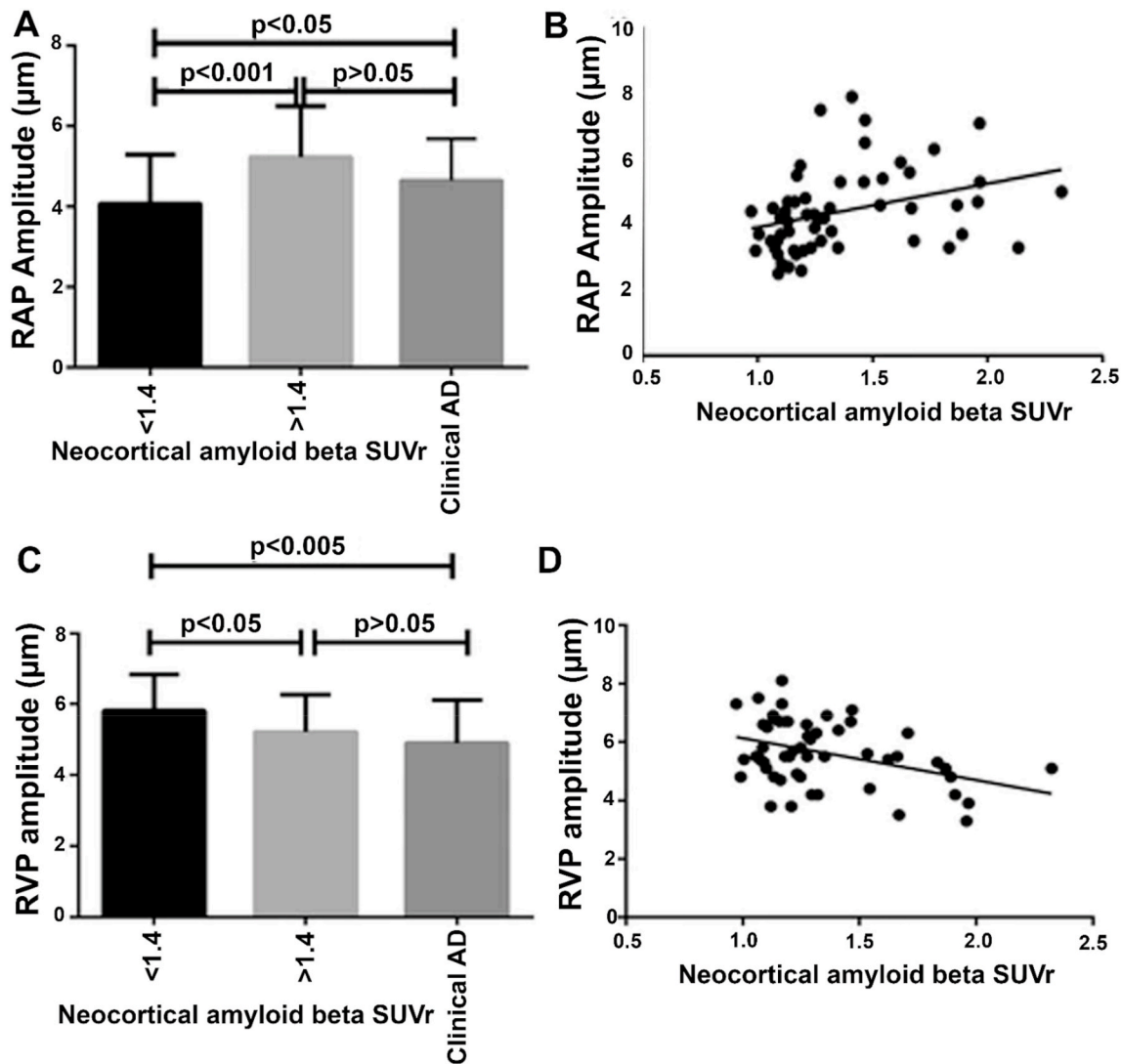
In addition to the extracellular deposition, amyloid plaques and aggregates are extensively distributed proximately to the blood vessel walls and networks in the AD brain (Bu et al., 2018). This is similar to that reported in cerebral vascular amyloid pathology (Koronyo et al., 2017). Owing to endothelial and physiological similarities in the micro-vessels of the retina within the brain, amyloid deposition could restrict the flow of blood in smaller vessels in the retinas of AD patients. Murine models of AD likewise manifest augmented vascular rigidity in response to amyloid build up in blood vessel walls, which impede blood flow and induce leaks owing to compromised permeability (Tanifum et al., 2014). A $\beta$  deposition was also found to be associated with damage to capillaries in 14-month-old Tg2576 mice retinas (Dutescu et al., 2009). Endothelial cell dysfunction is an additional factor that could influence APP metabolism in these cells in culture and potentially contribute to the overproduction of A $\beta$  in the vasculature (Gangoda et al., 2018). These studies are supported by recent evidence that the loss of pericytes in the retina eventuates in conjunction with vascular A $\beta$  deposition. This is in addition to reduced PDGFR $\beta$  levels in retinal vessels, which was interestingly associated with brain amyloid deposition (Shi et al., 2020). PDGFR $\beta$  impaired animals indeed exhibited neurovascular coupling deficits and compromised permeability of BBB. This was supported by observations that ablating PDGFR $\beta$  allele in APP<sup>sw/0</sup> mice resulted in exacerbation of AD pathology (Sagare et al., 2013). Vascular low-density lipoprotein receptor-related protein 1 (LRP-1), which is involved in mediating the clearance of A $\beta$  from the brain *via* blood vessels, was observed to be downregulated in AD retinas concomitantly with increased apoptosis of retinal pericytes. The

vascular involvement in mediating A $\beta$  clearance is evident from studies that demonstrate increased vascular aggregation following the treatment of AD mice with A $\beta$  specific antibodies (Deane et al., 2009). Although both A $\beta$  1–40 and 1–42 were elevated in the retinal blood vessels of AD subjects, the levels of 1–40 peptide were substantially higher in comparison to A $\beta$ 42 (Shi et al., 2020). These data suggest that A $\beta$ 40 processing could be preferentially affected in the retinal blood vessels over A $\beta$ 42, although the implications of these findings remain uncertain. Intriguingly, the level of both A $\beta$  species was significantly correlated with A $\beta$  plaque burden in the hippocampus and entorhinal and visual cortices. HSI differences elicited in retinal scanning at around 500 nm wavelength, could also potentially arise from amyloid accumulation in the retinal vasculature and surrounding regions that might affect vascular properties (Sharafi et al., 2019).

White matter hyperintensity changes have also been shown to be correlated with retinal fractal dimensions in AD retinas (Jung et al., 2019). These changes in various retinal vascular measures may be reflective of different stages in AD pathology. Furthermore, some studies have described decreases in the central retinal artery and vein equivalent (CRVE/CRAE) and the fractal dimension of the arteriolar and venular networks, as well as altered curvature tortuosity of the arterioles and venules, in AD patients (Cheung et al., 2014; Williams et al., 2015). OCT-angiography (OCTA) advances have made it possible for ophthalmologists to obtain insights into capillary bed changes in the retina in a clinical setting. While some studies have reported a decline in vessel density and blood flow and an increase in the foveal avascular zone (FAZ) area in early AD using OCTA imaging, studies carried out by other groups have failed to detect any differences in these measures (Bulut et al., 2018; Haan et al., 2019b; O'Bryhim et al., 2018). A reduced vascular and perfusion density in the macular regions was reported recently using OCTA in AD compared to MCI and control cases (Yoon et al., 2019). More recently, significantly higher vascular density around macular and optic nerve head regions was observed, with no significant FAZ area differences in preclinical stages of AD, as determined by A $\beta$ <sup>+</sup> PET scans (van de Kreeke et al., 2020).

In addition to static vascular changes, the association of dynamic measures such as vessel pulsation has been examined in AD. Spontaneous retinal venous pulsations is a normal finding in humans and is believed to originate from interaction between IOP, CSF pressure, ocular perfusion and central retinal vein pressures (Golzan et al., 2017). Our investigations into the association between retinal hemodynamics and cerebral A $\beta$  load in preclinical AD subjects revealed a negative correlation between the amplitude of retinal venous pulsations and A $\beta$  levels, indicated as SUVr in PET scanning. Of note, a positive correlation was detected between retinal arterial pulsation amplitudes and A $\beta$  SUVr in pre-clinical AD (Golzan et al., 2017). We also observed a similar trend in clinically diagnosed AD subjects, which supports an association between retinal hemodynamics and AD (Fig. 9). Reduced dilation of arteries in the retina of AD patients in response to light flicker by dynamic vessel analyzer (DVA) further attests to ongoing changes in blood-flow parameters and neurovascular decoupling (Querques et al., 2019). Although we are uncertain of the significance of these findings, chronic vascular changes and/or sustained high arterial pulse amplitudes could contribute to degenerative changes in the brain as well as inner retina and macular volume deficits.

In conclusion, identifying and characterizing new biomarkers for vascular changes in the retina will provide mechanistic insights into the disease process and could complement current diagnostic tools for AD (Golzan et al., 2017). Currently, our knowledge of the vascular changes in AD including alterations in perivascular spaces, microbleeds and small infarcts mainly arises from brain MRI. It is to be emphasized that various aforementioned vascular parameters could be affected by age and other ophthalmological comorbidities such as glaucoma, diabetic and hypertensive retinopathy and a further limitation is that not all studies used amyloid proven AD cases. In addition, individual variations in the retinal layers, vascular thickness, spherical equivalent and image



**Fig. 9.** Retinal vascular changes in AD. (A) Association between retinal arterial pulsations (RAP) and standardised uptake value ratio (SUVR) across control, pre-clinical AD and clinical AD subjects. (B) Linear association between RAP and SUVR obtained from control subjects and participants with preclinical AD. (C) Association between retinal venous pulsations (RVP) and SUVR across control, preclinical AD and clinical AD subjects and (D) Linear association between RVP and SUVR obtained from control subjects and participants with preclinical AD. Reused from (Golzan et al., 2017) under the Creative Commons Attribution 4.0 International License: [Creativecommons.org/licenses/by/4.0/](https://creativecommons.org/licenses/by/4.0/).

quality could contribute to these differences.

## 5. Other biomarkers of AD in the retina

### 5.1. Retinal proteomics changes in AD

While the reports of retinal changes have been increasing in AD, there is inadequate information regarding the molecular pathways that are impacted at different stages of the disease. A greater understanding of these progressive molecular changes will untangle the mechanistic basis of the functional, imaging, and histological changes observed in the retina in AD. Knowledge of region specific proteomics changes will enhance our ability to explain localized neural/vascular and imaging deficits in the retina. While proteomic changes in the blood and CSF have been investigated in detail, and more information has started to emerge from brain tissues of human AD post-mortem and transgenic animal models (Bai et al., 2020; Johnson et al., 2020); AD retinal tissues remain relatively under-investigated.

#### 5.1.1. Proteomics changes in the retina of APP/PS1 mouse model

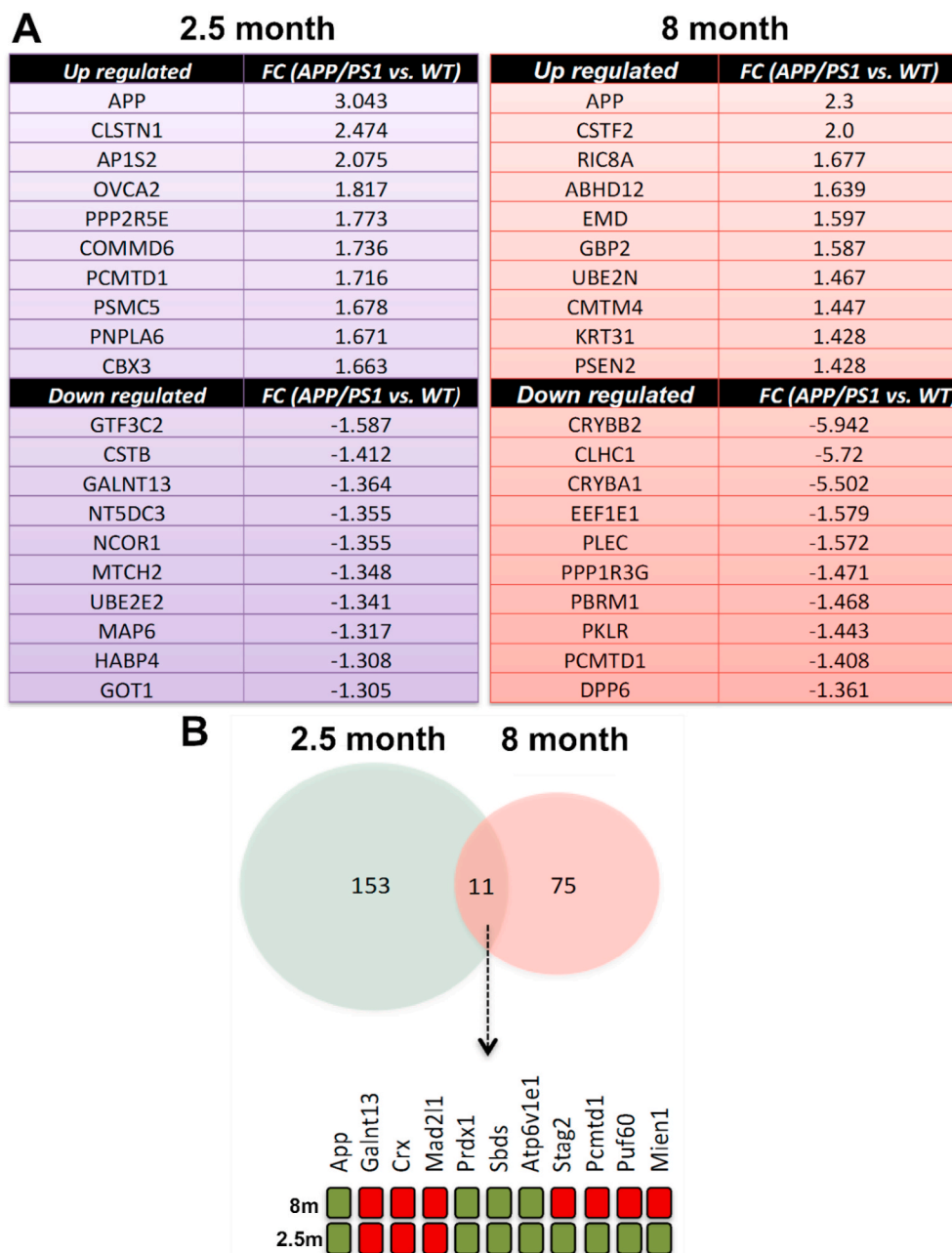Our retinal proteomics investigations in APP/PS1 transgenic mouse model of AD demonstrated significant protein expression changes at 2.5 months, much before A $\beta$  aggregation pathology is evident in the brain of these animals (Mirzaei et al., 2019b). These changes were compared with findings in 8-month-old APP/PS1 mice retinas. At this age, APP/PS1 mice exhibit cognitive, learning, and behavioral deficits, but without the neuronal cell loss that accompanies later stages of the disease in this model, which can confound protein expression analysis due to wide spread senescence and tissue atrophy (Gengler et al., 2010; Radde et al., 2006).

Proteomics analyses have revealed insights into the activation of various biochemical processes, such as phagosome maturation, ubiquitination, mitochondrial function, amyloid processing, oxidative stress, and the ER stress response (Mirzaei et al., 2019b). There were approximately 2000 proteins identified, of which 50 and 36 proteins were altered at 2.5 months and 85 and 79 in 8-month-old mice retinas, with increased and decreased abundance respectively (Fig. 10). In 8-month-old retinas, the proteins involved in APP processing, proteasomal activation, and ribosomal networks were differentially regulated, reflecting

the biochemical response to developing AD pathology (Fig. 11). APP, antioxidant enzymes peroxiredoxin 1, ribosome biogenesis protein Sbds, and ATPase enzyme Atp6v1e1 were enriched while the acetyl-galactosaminyl transferase Galnt13, transcription factor Crx, and mitosis regulator Mad2l1 were downregulated in the APP/PS1 retinas irrespective of the age. Intriguingly, levels of APP in the retina were elevated 2–3 fold in both young and older mice, providing evidence of retinal amyloid accumulation in this model much before the disease is manifested clinically. Furthermore, calyntenin-1 and AP1S2 adapter proteins, that play roles in protein sorting within the Golgi network and regulating sensory axonal arborization respectively, exhibited a two-fold increase in young 2.5-month-old retinal tissues. This is in contrast to the expression of cleavage stimulation factor CSTF2, which is involved in polyadenylation signal and mediating 3' cleavage of pre-mRNAs, which was increased two-fold in older APP/PS1 mice retinas (Mirzaei et al., 2019b).

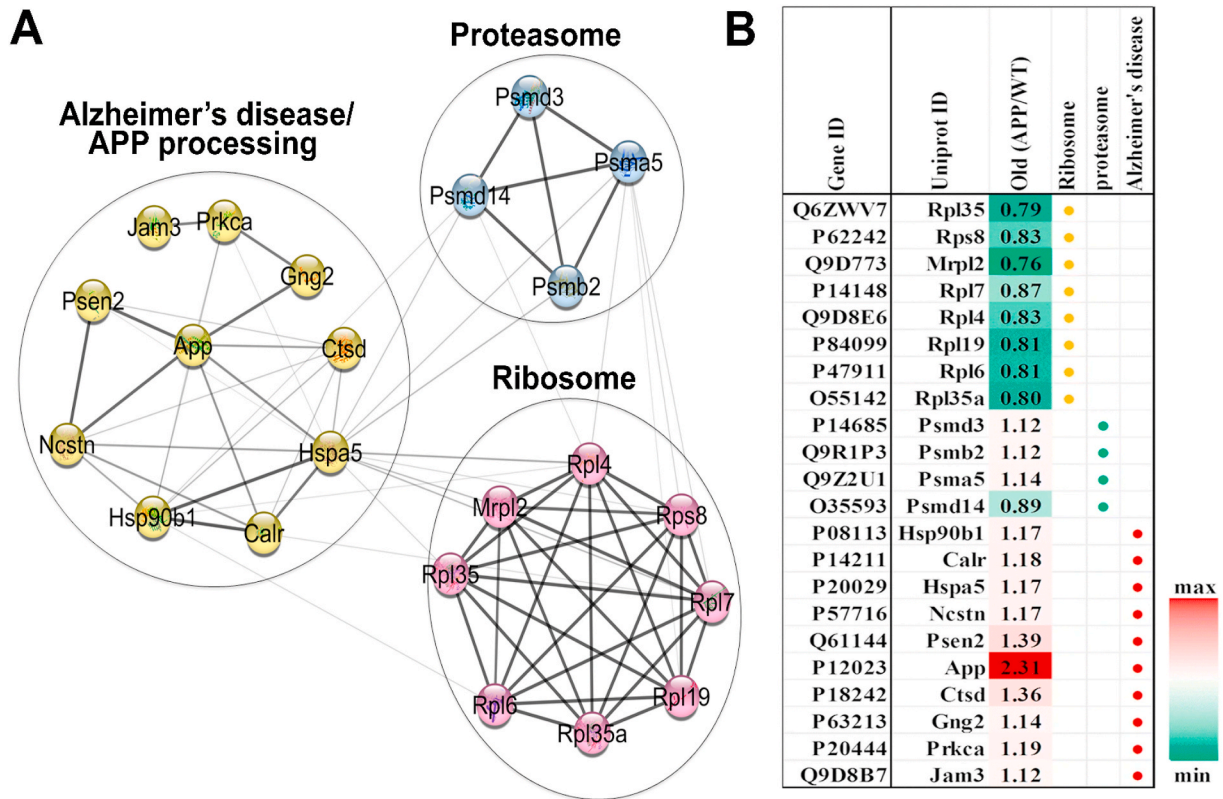
Amongst the downregulated proteins, general transcription factor

GTF3C2 and transcription regulatory protein cystatin B were most downregulated proteins in young mice retinas while crystallins BA1 and BB2 exhibited approximately five-fold downregulation in older mice tissues. With advancing pathology, APP/PS1 mice retinas depicted an increase in amyloid processing proteolytic enzymes such as cathepsin D, presenilin 2, and nicastrin. Our work also identified that proteasomal proteins Psma5, Psmd3 and Psmb2 were remarkably enriched in the retina. This was supported by findings of significant downregulation of protein synthesis and elongation factor proteins such as Eef1a1, Rpl35a, Mrpl2, and Eef1e1 in older mice retinas. Overall, amyloid processing, cytoskeletal and microtubule organization, neuronal development and differentiation, apoptosis, and biological functions associated with neurogenesis were the pathways most prominently affected (Mirzaei et al., 2019b). These differential changes in protein expression are characteristic of the progressive effects of AD on the retina with respect to age. While the significance of some of these molecular changes in AD retina may not be clear at this stage, proteomics data will serve as



**Fig. 10.** Differential protein expression changes in APP/PS1 mouse retina (A) List of 10 most upregulated and downregulated proteins in the 2.5 (left) and 8 month (right) old APP/PS1 mice retinas, respectively. (B) Overlap of the differentially regulated proteins between the 2.5 and 8-month-old APP/PS1 mice retinas (p value ≤ 0.05). The common differentially affected proteins in 2.5- and 8-month cohorts are listed. Reused with permission of Springer Nature for Mol Neurobiology, 2019, 56, pages 6017–6034 (Mirzaei et al., 2019b) (red, up and green, down-regulated).





**Fig. 11.** Biochemical pathway changes in AD mice retinas. (A) Functional interaction networks of differentially expressed proteins from 8-month old APP/PS1 mice retinas analyzed using open source Cytoscape software with the string DB plugin. The enriched networks are proteasomal enzymes, ribosomal machinery, and APP processing proteins. (B) List of proteins from interaction networks with corresponding fold changes. Reused with permission of Springer Nature for Mol Neurobiology, 2019, 56, pages 6017–6034 (Mirzaei et al., 2019b) (red- up and green- downregulated proteins).

important reference material for future studies. Similar studies need to be carried out in human AD postmortem retinas and knowledge generated will elucidate disease mechanisms and identify novel disease biomarkers. Analyzing proteomics data in conjunction with immunohistochemical analyses will establish the localization of specific markers to individual layers or cell types within the retina. Ability to isolate specific regions of the retina with the help of laser dissection microscopy or serial tangential section techniques is likely to ascertain the extent and significance of proteome alterations in various retinal cell populations (Kanan et al., 2010). Comparing retinal changes with specific regions of brain will demarcate the relative biochemical effects of AD on these two tissues and help to establish whether/or not the retinal tissue is affected much earlier in the disease process. Furthermore, comparing the effects of AD on the retina with other age-related retinal disorders such as glaucoma and AMD will clarify the specific effects of AD and molecular commonalities and differences between these neurodegenerative disorders (Mirzaei et al., 2017; Rozing et al., 2020).

### 5.1.2. Effects of A $\beta$ on 661W retinal neuronal cell proteomics

The specific effects of A $\beta$ 42 peptide on 661W retinal neuronal cells has been studied by carrying out comprehensive time- and dose-dependent proteomic analyses, to understand the mechanisms underlying A $\beta$  neurotoxicity (Deng et al., 2019). 661W is a mouse retinal neural precursor cell line that is shown to express opsin 1 cone-specific marker Opn1mw. The cells are also reported to express some of the RGC and neuronal cell markers such as Thy1, Brn3b, Tuj1, NeuN along with intermediate filament protein nestin, which plays a role in radial axonal growth (Sayyad et al., 2017). Similar to the changes observed in animal retinas, treatment with A $\beta$  depicted time- and concentration-dependent perturbations of cellular pathways that are involved in protein synthesis, RNA processing, autophagy, cytoskeleton reorganization and oxidative

phosphorylation (Deng et al., 2019). Overall, 5837 proteins were identified, out of which 380 proteins were differentially affected in response to treatments with various A $\beta$  concentrations. Nucleolar protein URB1 and U6 snRNA-associated protein Lsm1, which plays a role in mRNA processing, as well as RNA binding protein 47 and nuclear ribonucleoprotein RBMX were enriched in response to treatment with A $\beta$ . In contrast, levels of 60s ribosomal proteins such as Rpl29 and Rpl36a and 40s ribosomal protein RPS19 were reduced. Comparatively, cell cycle regulatory protein DPY30, which is involved in epigenetic transcriptional activation, and histone H3 acetylation were decreased in retinal neuronal cells subjected to treatment with A $\beta$  for 24h (Deng et al., 2019). The canonical pathway analysis revealed that elf2, elf4, and p70S6K proteins which are involved in regulating transcription signaling pathways, were also differentially affected. Amyloid accumulation has previously been shown to associate with mitochondrial dysfunction in primary cortical neurons both in culture and in AD tissues (Cha et al., 2012). A $\beta$  treatment indeed resulted in the downregulation of regulatory proteins involved in mitochondrial function and oxidative phosphorylation in retinal neuronal cells. Apart from these changes, authors also identified that proteins associated with autophagy, actin cytoskeleton, keratin filaments, spliceosome, and the lysosome were enriched, implicating these key cellular pathways to be affected by A $\beta$  in these cells (Deng et al., 2019). Sirtuin signaling which is inversely associated with Tau accumulation in AD, was differentially affected in retinal neurons in response to A $\beta$  treatment (Yin et al., 2018). Sirtuins protect cells via their inhibitory effects on NF $\kappa$ B signaling and accordingly, a negative correlation was observed between sirtuins and mTOR signaling in the retinal neurons upon treatment with A $\beta$  (Guo et al., 2011; Mirzaei et al., 2019b). Furthermore, splicing factors such as Rp9, DHX38, and snRNP proteins like PRPF3 have been shown to play important roles in the retina (Lv et al., 2017; Ruzickova and Stanek,

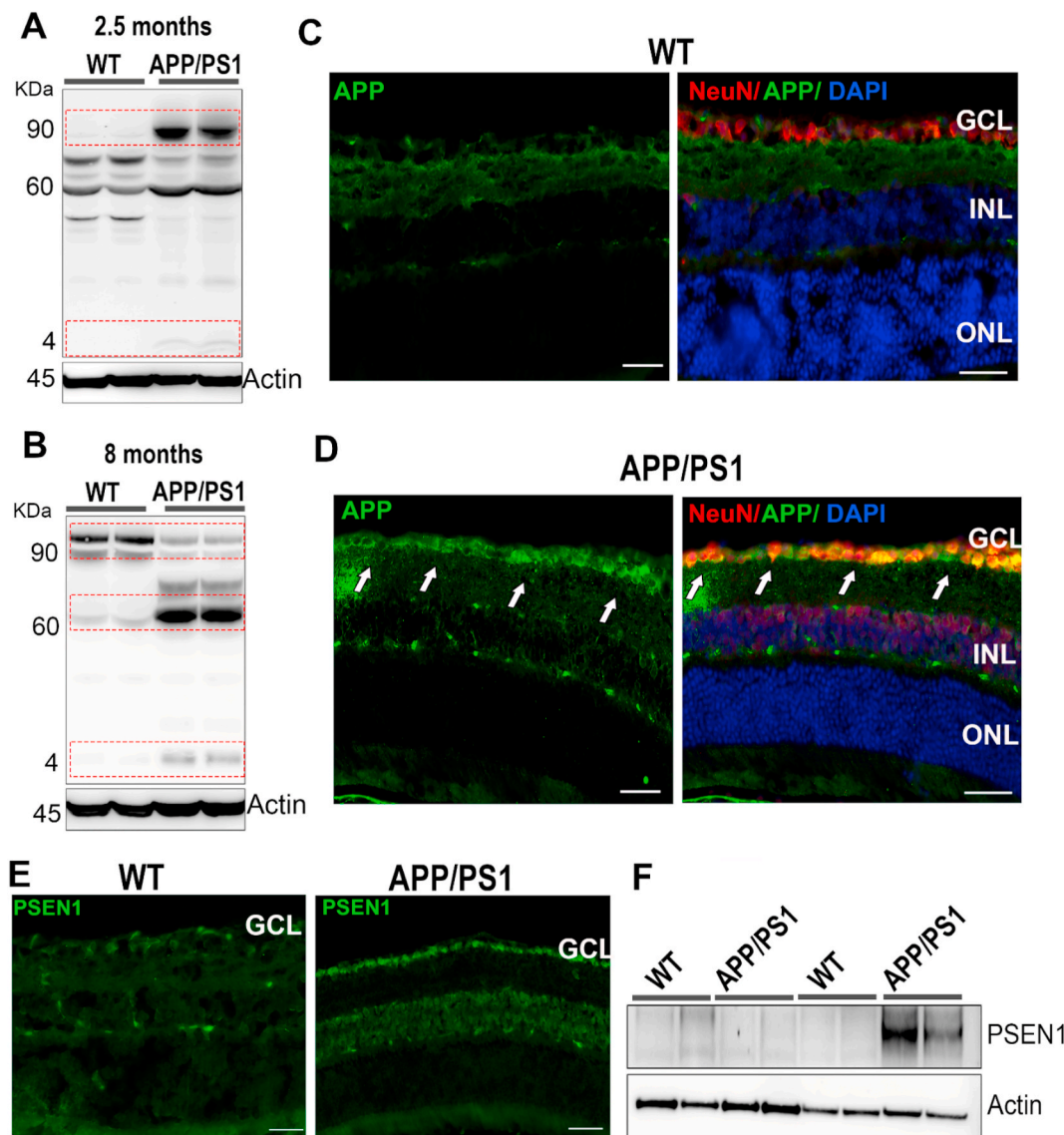
2017). While exposure to A $\beta$  resulted in significant perturbations in these proteins indicating spliceosome impairment and RNA splicing changes in retinal neurons (Mirzaei et al., 2019a), similar defects have previously been reported in AD (Bai et al., 2013; Nuzzo et al., 2017).

Significant perturbations in the proteins associated with the actin cytoskeletal and keratin filament networks were also evident in the 661W retinal neuronal cells in response to A $\beta$  treatment. Cytoskeletal assembly and cellular adaptability is affected in AD (Deng et al., 2019; Mirzaei et al., 2019b; Zempel and Mandelkow, 2012) and studies have shown that the sub-retinal administration of the A $\beta$  42 peptide resulted in cytoskeletal disorganization in the retinal pigment epithelium cells (Bruban et al., 2009). Tau plays an important role in preserving neuronal cytoskeleton and axodendritic architecture and hyperphosphorylation of this protein promotes paired helical filament (PHF) and neurofibrillary tangle (NFT) formation, which orchestrates microtubular dysfunction and cytotoxicity. We observed elevated tau phosphorylation in

661W retinal cells in response to A $\beta$  treatment, that also corresponded with GSK3 $\beta$  activation in these cells. GSK3 $\beta$  plays a major role in regulating tau phosphorylation and accordingly its pharmacological inactivation was recently shown to be neuroprotective and rescue behavioral and cognitive impairments in APP(SW)/Tau (VLW) mouse model of AD (Griebel et al., 2019). Thus, synergistic proteomics investigations that combine human post-mortem tissues with various animal and cellular models, will gradually unravel a true understanding of the retinal neurodegenerative alterations in various stages of AD pathogenesis.

## 5.2. Altered amyloid processing in the retina in AD

Various studies discussed above have demonstrated enhanced levels of A $\beta$  and its parent protein APP in ageing and AD retinas, in both human and transgenic animal model tissues (Grimaldi et al., 2019;



**Fig. 12.** Altered processing of amyloid precursor protein and its processing enzymes in APP/PS1 mice retina. Western blots were probed for APP expression changes in (A) 2.5 month and (B) 8-month APP/PS1 mice retinas compared to WT animals ( $n = 4$ ). (C–D) Retinal sections from WT and 8-month old APP/PS1 mice were stained with amyloid (green) and NeuN (red) antibodies ( $n = 3$ ). DAPI (blue). GCL-ganglion cell layer, INL, inner nuclear layer, ONL, outer nuclear layer. (E) Immunostaining showing enhanced presenilin expression (green) in the GCL of 8-month-old APP/PS1 retinas compared to the WT animals ( $n = 3$ ). (F) APP/PS1 mice retinal lysates were probed for presenilin 1 expression changes using immunoblotting ( $n = 3$ ). Significantly increased presenilin expression was observed in 8-month-old APP/PS1 mice retinal lysates compared to WT ones. Actin was used as loading control in each case. Scale = 50  $\mu$ m. Data reused with permission of Springer Nature for Mol Neurobiology, 2019, 56, pages 6017–6034 (Mirzaei et al., 2019b).

Koronyo-Hamaoui et al., 2011; Mirzaei et al., 2019b). This is supported by recent findings that have demarcated differential abundance of amyloid proteins in various regions of the retina, with amyloid deposition particularly observed in the superior quadrant in human post-mortem tissues. Although, pathophysiological basis of these observations remains unclear, the findings were consistent with identification of amyloid positive spots in superior temporal and inferior temporal regions of the retina in AD patients *in vivo* (Koronyo et al., 2017).

Our proteomics screen identified a two to three-fold upregulation of APP and A $\beta$  in the retinas of 2.5 month and 8-month-old APP/PS1 mice. Retinal neurons and glial cells also express other key proteins associated with AD pathology such as BACE1,  $\gamma$ -secretase, and ApoE, which are implicated in the metabolism of A $\beta$  peptides in the brain (Sivak, 2013). In parallel to the APP changes, increased levels of APP processing enzymes were observed in animal retinas. Immunohistochemical staining revealed increased levels of APP, which was further validated by immunoblotting analysis of the retinal tissues (Mirzaei et al., 2019b). While 2.5 month APP/PS1 mice demonstrated only slightly elevated levels of small molecular weight A $\beta$  peptides; at 8 months, the parent APP levels were reduced, with a concomitant increase in A $\beta$  and its oligomerized forms, illustrating altered APP processing with age in the retina (Fig. 12). This altered amyloid processing is supported by prior reports of A $\beta$  plaque formation in cerebral cortex of mouse model starting at 6 weeks of age. Subsequently, amyloid deposition was identified in the hippocampus and other brain regions such as the thalamus, striatum, and brainstem between 3 and 5 months of age (Radde et al., 2006). By eight months, animals present with substantial cognitive and behavioral shortfalls, but without neuronal obliteration, which can camouflage *bonafide* changes in the protein expression (Cheng et al., 2013; Sadowski et al., 2004). APP staining was predominantly localized to the IPL and GCL, which supports the previous observations of inner retinal electrophysiological disturbances and thinning of retinal layers in APP/PS1 mice. This increased amyloid deposition in the vicinity of the INL and GCL correlated with enhanced RGC apoptosis in these mice at 13–16 months of age (Gupta et al., 2016b). Altered amyloid processing was also observed in human postmortem retinal tissues, wherein enhanced intracellular positivity for antibodies with APP affinity (6E10), in the absence of clear extracellular plaque formation was reported. These findings reflected intricate differences in the patterns of APP/A $\beta$  processing and deposition between the retina and the brain (den Haan et al., 2018c).

Presenilin (PSEN1) is a transmembrane protein that comprises the catalytic subunit of the  $\gamma$ -secretase protease complex and is involved in APP processing. Although, while presenilin expression remained constant early on in life, it increased in AD mice as they aged to 8 months, suggesting the differential APP processing activity of the  $\gamma$ -secretase protease complex and concomitant changes in A $\beta$  processing. Antibody staining of presenilin in the retinal sections revealed that the PSEN1 protein was predominantly localized to the inner retinal layers, which is the primary site of elevated A $\beta$  immunoreactivity and also the region that shows the greatest extent of degenerative changes in the retinas of AD animal models (Mirzaei et al., 2019b) (Fig. 12). The observed changes in APP and A $\beta$  levels, as well as its regulatory enzyme PSEN1, in the retina implicate that retinal imaging advances that could detect and quantify these molecular differences *in vivo*, have the potential to improve AD diagnoses and track disease progression.

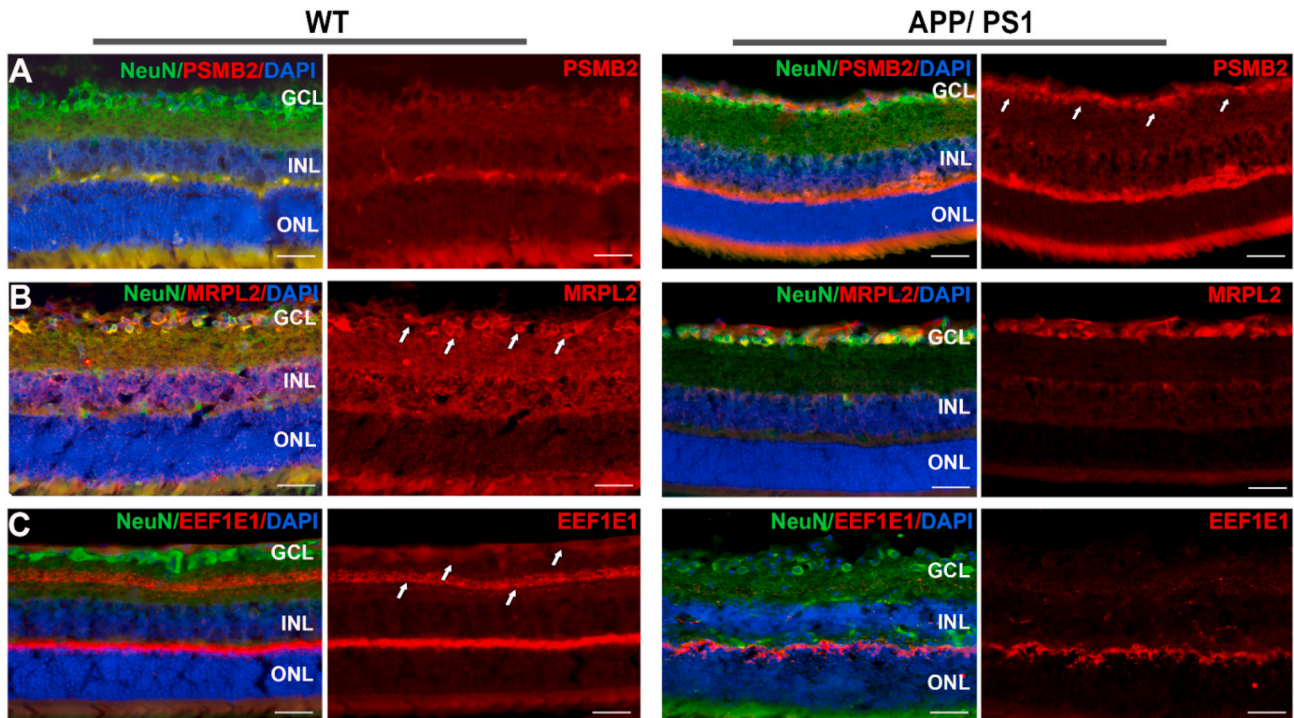
### 5.3. Activation of cellular proteolytic machinery in AD retinas

AD pathology can overwhelm the neuronal metabolism through accumulation of aggregating proteins. These misfolded and aggregated proteins are removed by activation of proteolytic enzymes and ubiquitin-proteasome system to maintain cellular proteostasis (Gadhav et al., 2016). APP/PS1 mouse model of AD exhibits enhanced proteolytic activation with age in retina and similar neurotoxic changes have been detected in 661W retinal neuronal cells upon exposure to A $\beta$  (Deng

et al., 2019; Mirzaei et al., 2019b). Plasmin—a potent proteolytic enzyme with broad specificity—is activated upon stimulation with A $\beta$  peptide and has been implicated in mediating amyloid clearance from the tissues. The plasminogen system was shown to be able to act upon and degrade both monomeric and aggregated forms of A $\beta$  peptide and protect primary cortical neurons from A $\beta$  induced toxicity (Tucker et al., 2000). Increased plasmin activity is also reported in the glaucoma retina, where it was associated with reduced protease inhibitory activity of neuroserpin and increased digestion of extracellular matrix proteins in the optic nerve head region (Gupta et al., 2017). Another proteolytic enzyme, caspase-3 which is a key apoptosis mediator, is involved in expedited cleavage of APP and presenilin family of proteins that comprise  $\gamma$ -secretase protease complex. The enzyme has been shown to associate with the accumulation of intraneuronal A $\beta$ 42 peptides in 4 and 9 month old 5xFAD mice, thus contributing to ongoing neurodegenerative processes in AD pathology (Eimer and Vassar, 2013). Increased caspase-3 activation in 3x Tg-AD mice retinas was observed in advanced stages of AD (Grimaldi et al., 2018). Similar increase in cleaved caspase 3 staining was also detected in the human AD postmortem retinas and it co-localized with the RGCs (Grimaldi et al., 2019).

Retinal proteomics investigations have revealed an increased abundance of several key proteolytic enzymes and proteasome-associated proteins in the retinas of APP/PS1 mice. For example, cathepsin B—which plays a role in APP processing and regulation of A $\beta$  levels—was specifically elevated in the GCL region in APP/PS1 mice (Mirzaei et al., 2019b). The modulation of cathepsin B activity has been shown to play a role in reducing A $\beta$  production and in improving memory (Embury et al., 2017). Nicastrin—the largest constituent of the  $\gamma$ -secretase complex—similarly exhibits elevated expression within the inner retinal layers of APP/PS1 mice retinal tissues, as demonstrated by mass spectrometry and immunodetection analyses. It is a 709 amino acid type I transmembrane glycoprotein of 78 kDa, that binds to APP and plays key roles in Notch and Wnt signalling cascades. Using 5xFAD mice which express five AD related genetic variations; Nicastrin mediates the biochemical cascade of A $\beta$  generation, and conditional inactivation of this protein led to reduced amyloid deposition (Sesele et al., 2013). Targeting this protein in the retina may lead to similar outcomes of reduced amyloid accumulation in AD.

Proteasome assemblies degrade distorted or aggregated proteins *via* proteolysis and play a key role in regulating protein quality control. Proteasome complexes are involved in regulating the proteolytic processing of aggregated A $\beta$  and tau proteins. A $\beta$  deposition could induce neurotoxic effects and promote unwarranted proteasomal activation in AD (Aso et al., 2012). Other reports suggest that protein catabolic processes, including proteasomal activity and ubiquitination, are diminished in AD brains. These varied effects can be indicative of various stages of the disease process or region- and tissue- specific effects. Our quantitative proteomics investigations revealed specific upregulation of proteasomal protein PSMB2 in the retinas of 8-month old APP/PS1 mice. PSMB2 is a critical component of 20S proteasomal complex and induces ATP-dependent cleavage of ubiquitinated proteins. Immunoblot analysis of the retinal tissues using anti-PSMB2 antibody did not show significant differences in expression of this protein. Therefore, we performed immunohistochemical analysis of the retinal sections which validated the proteomics findings and demonstrated striking upregulation of PSMB2 expression specifically in the GCL region (Mirzaei et al., 2019b) (Fig. 13). These findings signify that AD affects distinct populations of retinal cells in different ways and examining the whole retina may not necessarily be the best approach to identify disease specific variance. Future studies will elucidate whether proteasomal activation in AD retina is primarily caused by elevated A $\beta$  and tau assemblies; or a cellular response to clear these proteins, or a combination of both processes.



**Fig. 13.** Effect on proteasomal markers and protein synthesis machinery in the retina in AD mice. WT and APP/PS1 retinal lysates of 8-month-old mice were stained with (A) proteasomal marker PSMB2 (red). Immunofluorescence analysis of retinal sections demonstrated that expression of PSMB2 was enriched in the GCL of APP/PS1 mice. (B) MRPL2 (red). A reduced expression of MRPL2 was observed in the GCL (arrows) in APP/PS1 mice. (C) Eef1e1 (red) with reduced expression observed in the ganglion cells of APP/PS1 mice. NeuN (green) is the ganglion cell marker in each case and blue colour indicates DAPI nuclear staining ( $n = 3$  each). Scale = 50  $\mu\text{m}$ . GCL-ganglion cell layer, INL, inner nuclear layer, ONL, outer nuclear layer. Data reused with permission of Springer Nature for Mol Neurobiology, 2019, 56, pages 6017–6034 (Mirzaei et al., 2019b).

#### 5.4. AD crosstalk with protein biosynthesis, mitochondrial function, and cytoskeletal proteins in retina

The dysregulation of ribosomal function and protein biosynthesis are some of the initial biochemical processes that are affected in AD pathogenesis (Aso et al., 2012). Proteins involved in the mechanisms of transcription, translation, and elongation have been shown to be downregulated in APP/PS1 mice retinas using mass-spectrometry analysis. Wide-spread deviations in expression of various components of protein production machinery including initiation, translation, and elongation stages has been observed in ribosomes (Aso et al., 2012). Ribosomes are multi-component organelles that synthesize proteins in cells, and both mitochondrial and cytoplasmic fractions of ribosomal proteins are differentially affected in APP/PS1 mice retinas. We observed that 39S ribosomal protein L2 (MRPL2) which is a component of mitochondrial large ribosomal subunit, was reduced in the inner retinal layers (Fig. 13). The expression of elongation factor Eef1e1 also revealed downregulation in the inner retinal layers of APP/PS1 mice as a consequence of developing disease pathology (Mirzaei et al., 2019b) (Fig. 13). This is supported by evidence that upregulation of APP proteins correlates with negative modulation of protein synthesis and elongation processes. Tau hyperphosphorylation has similarly been suggested to promote ribosomal anomalies and suppress protein synthesis machinery, which may lead to the impairment of synaptic function and neural plasticity. Interestingly, in a proteomics study carried out by our group, we identified differential modulation of the abundance of seven mitochondrial ribosomal proteins in human glaucoma retinas, suggesting a potential biochemical overlap of pathological processes between the two neurodegenerative disorders (Mirzaei et al., 2017, Mirzaei et al., 2020b).

The accumulation of retinal A $\beta$  in transgenic animals and the intra-ocular administration of this peptide aggravated wide-ranging

neurotoxicity that is consistent with the biochemical pathways affected in ageing and disease conditions (Gupta et al., 2014b; Mirzaei et al., 2017). In 661W retinal neuronal cells, A $\beta$  treatment had a significant impact on ribosomal protein synthesis, oxidative phosphorylation, cytoskeletal dynamics as well as spliceosome and lysosomal regulation. Indeed, similar to APP/PS1 mice retinas, treatment of retinal neuronal cells with A $\beta$ 42 peptide induced a decrease in mitochondrial and cytoplasmic ribosomal proteins following 6 h of A $\beta$  treatment. A particularly strong downregulation of expression was observed for Rpl29 and Rps19 ribosomal proteins (Deng et al., 2019).

Progressive mitochondrial diminution has been consistently reported in AD models, with A $\beta$  localizing at the mitochondrial membrane, which presumably chaperones cellular neurotoxicity through its inhibitory effects on pre-protein maturation (Cenini et al., 2016). Abnormal inter-neuronal A $\beta$  accumulation may elicit mitochondrial dysfunction, which ultimately precedes cell loss (Williams et al., 2013). Mitochondrial markers such as opa1, dynamin 1 and mitofusin 1/2 are reduced in AD leading to alterations in mitochondrial fission and fusion processes. These processes protect the cells against stress by maintaining mitochondrial integrity, through both complementation and elimination of damaged organelles. Electron microscopic analysis indeed revealed a marked shift in the mitochondrial morphology and reduced mitochondrial integrity in the RGCs, in AD transgenic mice. These changes were accompanied by alterations in the mitochondrial cristae leading to enlarged inter-mitochondrial spaces alongside mitochondrial swelling in the RGC dendrites (Williams et al., 2013). The expression of several proteins associated with oxidative phosphorylation and mitochondrial function in retinal neuronal cells was differentially modulated upon treatment with A $\beta$ . Ndufs4 and Atp6v1g1 were prominently down regulated (Deng et al., 2019), while abundance of several other proteins as a result of A $\beta$  treatment corroborated the previous observations in AD pathology (Mirzaei et al., 2019b). Defects in A $\beta$  and tau protein

expression impinge upon mitochondrial integrity and synchronically promote vulnerability of oxidative phosphorylation machinery in animal models of AD (Williams et al., 2013). The accumulation of these proteins may preferentially affect RGCs due to their high energy requirements as indicated by mitochondrial enrichment in the dendrites and the fact that their axonal projections are unmyelinated until they enter lamina cribrosa (Casson et al., 2020). Lamina cribrosa is a perforated mesh like structure where RGC axons converge and the tissue provides mechanical support against strain caused by translaminar pressure gradients. Impaired mitochondrial integrity has been shown to alter energy metabolism and trigger early AD pathology, emphasizing the key involvement of mitochondrial dysfunction in AD pathology (Moreira et al., 2010).

Approximately 10 proteins associated with spliceosome and mRNA were also observed to be differentially expressed in response to A $\beta$  treatment, suggesting that these processes are affected in response to A $\beta$  exposure. For example, RNA binding protein Rbmx11 illustrated most noticeable upregulation of protein expression, with pre-mRNA splicing factor Isy1 exhibiting downregulation upon treatment with A $\beta$ . Furthermore, while the RNA binding motif protein Rbmx was initially unchanged, its levels increased significantly as duration of A $\beta$  incubation with retinal neuronal cells was extended to 24 h (Deng et al., 2019).

Cytoskeletal architecture—with twenty-eight actin microfilament and six keratin intermediate filament proteins—was differentially affected upon exposure to A $\beta$ , suggesting that cellular stabilization, resistance to deformation and cell-matrix crosstalk are affected in retinal cells. Other proteins linked to the cytoskeletal system such as Tropomodulin 2, Murc, and Pfn2, were also differentially modulated in response to A $\beta$  exposure (Deng et al., 2019). Tau microtubule-associated protein is involved in cellular signaling and serve neuroprotective functions, and tau hyperphosphorylation can lead to pathological self-assembly in AD. Augmentation of Ser202/Thr205 tau phosphorylation was detected in response to A $\beta$  treatment in retinal neurons, with a parallel increase in glycogen synthase kinase 3 $\beta$  (GSK3 $\beta$ ) phosphorylation (Deng et al., 2019). GSK3 $\beta$  interacts with tau and plays a role in axon formation, and its dysregulation triggers both A $\beta$  production and a cascade of toxicity effects that lead to neuronal death in AD and cellular ageing (Chu et al., 2017). Together, these protein changes indicate that the toxic effects of A $\beta$  on retinal neurons may be exacerbated through its

modulatory effects on cytoskeletal organization and the filamentous architecture of the cells. A schematic representation of various potential molecular changes that are affected in the retina in AD is illustrated in Fig. 14.

### 5.5. BDNF/TrkB signaling in the retina in AD

Brain-derived neurotrophic factor (BDNF) is involved in mediating neurite outgrowth from RGCs, and can protect against optic nerve axonal degeneration and RGC apoptosis, as has been demonstrated in different experimental RGC injury models (Chitranshi et al., 2019b). BDNF is synthesized in both RGCs and Muller glial cells in the retina, and is also transported retrogradely from the superior colliculus and lateral geniculate nucleus to the RGCs via the optic nerve axons (Mysona et al., 2017). The protective effects of BDNF are accomplished via activation of downstream neuroprotective signaling such as PI3K/Akt/mTOR and MAPK/Erk 1/2 pathways through its high affinity receptor, tropomyosin receptor kinase B (TrkB), which is also well expressed in the RGCs and optic nerve axons (Gupta et al., 2014a, 2014b). TrkB is a tyrosine kinase receptor that has high affinity for BDNF and is extensively involved in regulation of neuronal survival and mediating dendritic growth, synapse formation and neural plasticity in CNS (Chitranshi et al., 2018). Our studies have demonstrated that TrkB interacts with non-receptor tyrosine phosphatase Shp2 (PTPN11) in the RGCs in a caveolin dependent manner. Interaction with Shp2 leads to dephosphorylation of intracellular tyrosine kinase domain of TrkB and negatively modulates receptor activity (Abbasi et al., 2018, 2020; Gupta et al., 2012). Accordingly, we observed that Shp2 upregulation in the retina using AAV2 intravitreal administration resulted in loss of BDNF/TrkB signaling. This Shp2 modulation was also associated with upregulation of ER stress markers CHOP/GADD153, GRP78, p-PERK and apoptotic activation in the retina. AAV mediated Shp2 silencing using shRNAmir on the other hand, protected the RGCs against ER stress activation and apoptotic changes and rescued the BDNF/TrkB signaling under glaucomatous stress conditions (Chitranshi et al., 2017, 2019b). Exposure of SHSY5Y cells to A $\beta$  peptide also eventuated the activation of GADD153 and pPERK markers and increased the expression of the pro-apoptotic BAD protein (Dheer et al., 2018).

Recent studies have described the loss of BDNF signaling in the AD

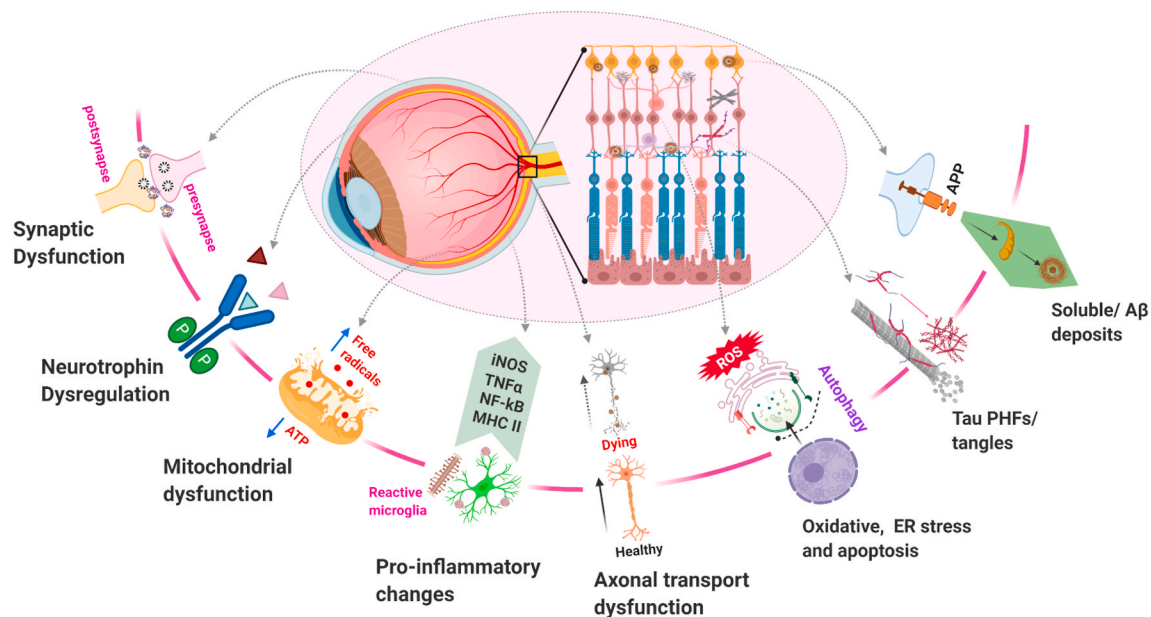


Fig. 14. Schematic representation illustrating various molecular changes in the retina in AD conditions. Chronic neuronal damage induces activation of microglial cells that can generate pro-inflammatory molecules such as iNOS, NF- $\kappa$ B, TNF $\alpha$ , MHC-II, ROS and various cytokines (Haque et al., 2018) which can potentially affect neurogenesis and axonal remodeling.

brain and the association of BDNF Val66Met and Cys270Thr variants with cognitive changes and a heightened risk of developing AD (Shen et al., 2018). BDNF impairment has been shown to induce A $\beta$  build-up in cases of AD and likewise, our studies have shown that BDNF impairment results in progressive accumulation of A $\beta$ 42 in the retina with age (Fig. 15), leading to a loss of neurons in the GCL and a decline in pSTR amplitudes (Gupta et al., 2014b). The induction of experimental glaucoma further exacerbated the retinal A $\beta$  accumulation phenotype in BDNF heterozygous mice, suggesting that BDNF actions could be involved in the generation of A $\beta$  or its degradation in the neural tissues (Gupta et al., 2014b). Similar to the retina, the sequestration of BDNF using anti-BDNF antibodies led to augmented amyloidogenesis in hippocampal neurons and accelerated senescence (Prakash and Kumar, 2014). Interestingly, the exogenous administration of BDNF to the hippocampus resulted in a reduction in A $\beta$  levels in the tissue, which supports a key role for this neurotrophic factor in imparting protection against A $\beta$  pathology (Zhou et al., 2008). The protective effect of BDNF are also evident from observations that BDNF infusion in the brain was not only effective in protecting the neurons but reversed the neuronal loss and synaptic deterioration associated with AD in an animal model. Further, while loss of BDNF has been shown to promote A $\beta$  deposition in the inner retina and optic nerve, it is equally possible that increased A $\beta$  deposition could restrict the retrograde transport of BDNF/TrkB to the retina from the superior colliculus and lateral geniculate nucleus via optic nerve axons.

### 5.6. ApoE genetic polymorphism and its effects

Studies on multiple genetic and blood biomarkers have revealed a tight association between ApoE and the sporadic manifestation of AD (Gupta et al., 2011; Liu et al., 2013). The gene is mainly expressed as three different isoforms-ApoE2, ApoE3 and ApoE4 and the 34 kDa ApoE protein plays key regulatory roles in lipid metabolism in blood. Polymorphisms in the ApoE gene strongly correlate with the risk of AD, and plasma levels of ApoE could serve as a potential disease biomarker (Gupta et al., 2011). In addition, the E4 isoform of ApoE which is present in approximately 10–15% of the population, bestows a three-fold heightened risk of developing AD with representation in almost 50% of the AD patients. Having two copies of the E4 allele can increase the risk of developing AD by as much as 10–15 times (Michaelson, 2014). In contrast, the ApoE2 allele, which is relatively rare and is present in approximately 5% of the population, has been shown to reduce the risk of AD. Intriguingly, in comparison to the more widely-distributed ApoE3 allele which is present in 75–80% people and generally does not influence risk, the ApoE2 allele has been shown to increase the risk of

developing AMD, while the ApoE4 allele diminishes this risk (Xiyang et al., 2017). The underlying mechanism for these puzzling differences involving reverse association of ApoE4 and E2 alleles with AD and AMD are not completely known. Subretinal inflammatory changes in AMD mouse model was shown to be ApoE isoform dependent, suggesting that the ApoE2 isoform is a risk factor and ApoE4 as beneficial in AMD (Levy et al., 2015). Further, retinoid X receptor (RXR) agonists have been implicated in mediating clearance of A $\beta$  from the tissues by promoting ApoE levels. Our studies revealed that RXR agonist bexarotene reduced A $\beta$  generation in SHSY5Y cells protecting them against ER stress and apoptosis (Chitranshi et al., 2019a; Dheer et al., 2018) and also protected the RGCs and optic nerve axons in animal models of experimental glaucoma (Dheer et al., 2019). In addition to ApoE, other major genetic polymorphisms that may or may not translate to protein sequence changes such as CHAT, CYP2D6, ABCA1, CHRNA7, ESR1, SNAP-25 etc. have been implicated in regulating the AD risk and responsiveness to various therapies (Sumirtanuridin et al., 2019). Future studies will unravel the correlation of ApoE and other genetic variants with ocular manifestations of disease. Ophthalmic investigations in association with genetic risk profiling could greatly improve AD diagnosis in early stages, evaluate disease course and clinically differentiate AD signs from other ocular disorders and age-related artefacts.

## 6. Neuroinflammation in the retina in AD

### 6.1. Neuroinflammatory biomarker changes in AD retinas

Chronic inflammation has increasingly been acknowledged as a hallmark feature of several age-related neurodegenerative disorders (Kinney et al., 2018). Accruing evidence indicates that sustained inflammation may compromise the core protective mechanisms that underlie neural injury in AD pathology (Heneka et al., 2015). Amyloid  $\beta$  plaques and tau protein PHFs and NFTs are often coupled with activated astrocytes and microglial cells in the AD brain (Selkoe and Hardy, 2016). A $\beta$  and tau accumulation can lead to inflammatory reactions that mediate astrocytic and microglial activation and may trigger the release of inflammatory mediators such as cytokines and thus promote apoptosis in both the retinal and brain tissues (Laurent et al., 2018). Astrogliosis is particularly evident in the GCL and inner and outer plexiform layers as evident by increased GFAP staining in retinal tissues from human AD subjects (Fig. 16). Pro-inflammatory molecules released by the microglia have been linked to the NLRP3 inflammasome and complement pathway activation (Spangenberg et al., 2016; Yue et al., 2017). It is well known that general neuroglial activation occurs with normal ageing; however, a significant increase in microglial cell density

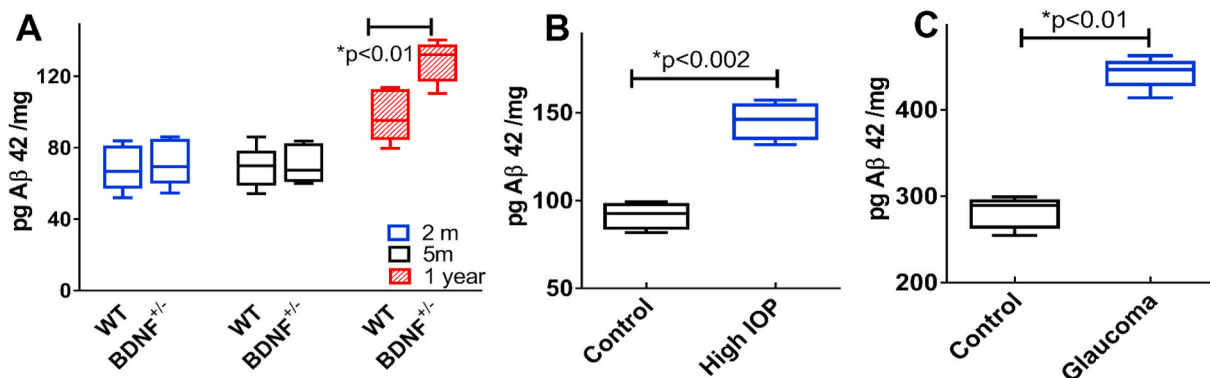
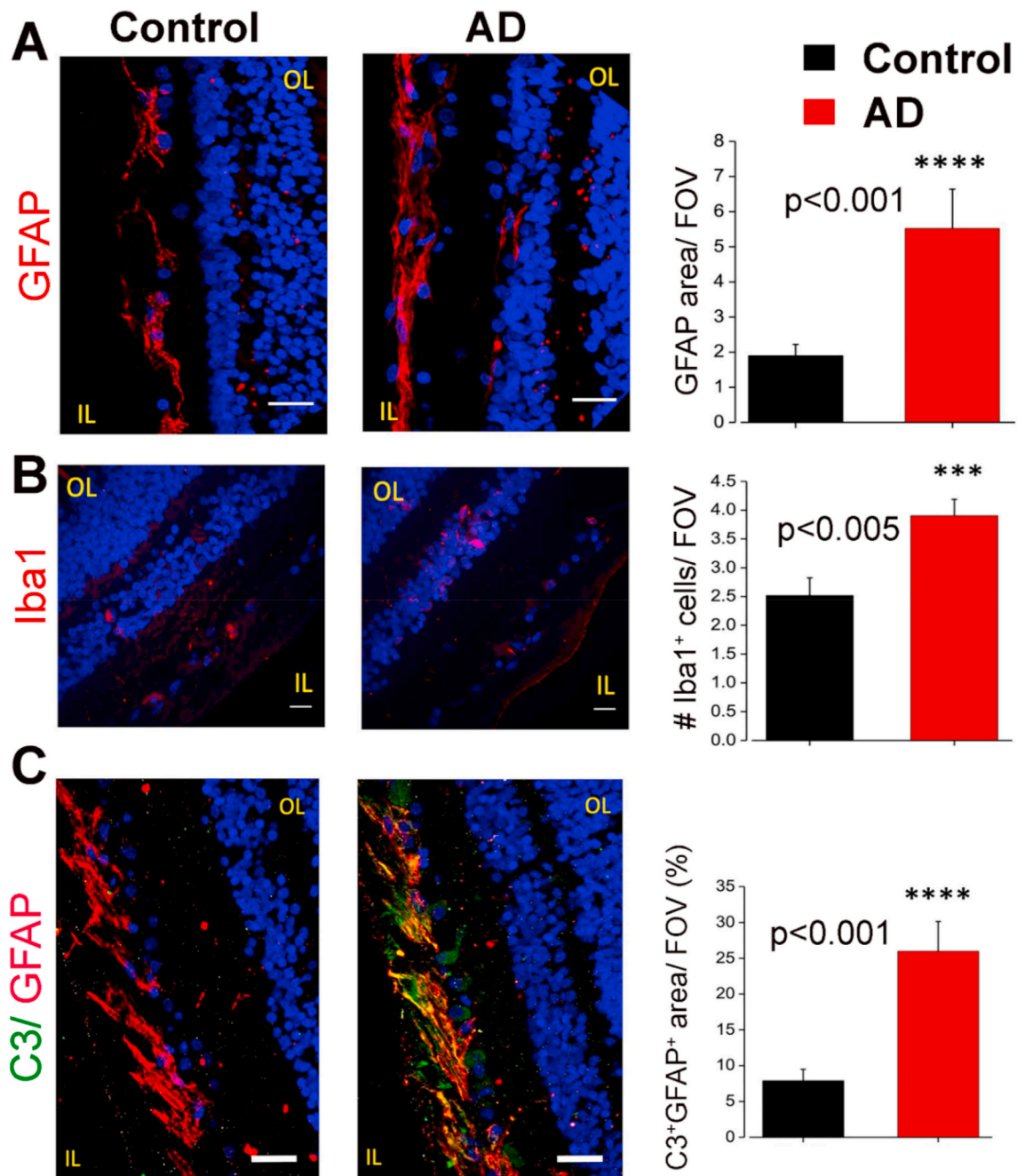


Fig. 15. BDNF loss promotes amyloid  $\beta$  accumulation in mouse retina with age. (A) A $\beta$  (1–42) levels were not affected in the optic nerve head of BDNF $^{\pm}$  mice at 2 and 5 months of age but were significantly increased at 1 year, compared to the WT animals as detected by ELISA (n = 5). Increased levels of soluble A $\beta$ 42 peptide were also detected in the optic nerve tissue of (B) WT mice exposed to microbead induced increased IOP of 23.71  $\pm$  3.78 mm Hg over a period of 8 weeks. (C) Human post-mortem optic nerve tissues also revealed increased A $\beta$ 42 levels compared to the control tissues (n = 4 each). Data replotted with permission from (Gupta et al., 2014b), <https://doi.org/10.1016/j.bbadis.2014.05.026>, conveyed through Copyright Clearance Center, Inc.



**Fig. 16.** Increased pro-inflammatory markers in the post-mortem AD retinas. Representative images from control and AD retinas stained for (A) GFAP (red) and quantification of GFAP area covered by fluorescent signal/field of view  $n = 44/6$  fields/patients (B) Iba1 (red) and quantification of its area shown by fluorescent signal/field of view  $n = 73/10$  fields/patients (C) complement C3 (green) immunoreactivity. Red- GFAP and quantification of GFAP/C3 co-localization area/field of view,  $n = 45/6$  fields/patients. Reused from (Grimaldi et al., 2019) under the Creative Commons Attribution 4.0 International License: [creativecommons.org/licenses/by/4.0/](https://creativecommons.org/licenses/by/4.0/). Blue- Hoechst. Scale 20  $\mu\text{m}$ . IL, inner layer; OL, outer layer.

is observed in the inner retinal layers under conditions of AD, with increased Iba-1 staining particularly in IPL and OPL regions (Fig. 16). Iba-1 is a  $\text{Ca}^{2+}$  binding microglial protein that is implicated in cytoskeletal remodeling and mediates cell migration. These observations emphasize that increased expression of IL-1 $\beta$  and augmentation of disease associated microglia are observed in the post-mortem retinal tissues of AD subjects, as well as in mouse models (Grimaldi et al., 2019; Ramirez et al., 2017). The enhanced expression of IL-1 $\beta$  was prominently localized to INL and co-stained with microglial marker Iba-1 in human AD retina (Grimaldi et al., 2019). In response to chronic injury or exposure to the oligomerized neurotoxic proteins, these microglia

migrate to sites of cell injury, secrete pro-inflammatory molecules, endeavoring to endocytose debris and protein fibrils (Ramirez et al., 2017). This neuroglial activation and the associated inflammatory response is also believed to mediate synaptic loss and neuronal degeneration (Spangenberg et al., 2016). However, while IL-1 $\beta$  expression is elevated in the astrocytes in the brain of an AD mouse model (Rosezweig et al., 2019), cytokine reactivity here, did not reveal colocalization with GFAP-positive cells in human AD retinas. In contrast, the extracellular matrix protein and cytokine, osteopontin (OPN), which interacts with multiple integrin receptors and plays a role in immune activation, including chemotaxis and cell activation—was enriched in

AD retinas and colocalized with  $\beta$ III tubulin in RGCs (Grimaldi et al., 2019). OPN is increased in AD brain tissues and treatments with immunomodulating compound glatiramer acetate (GA) resulted in extensive increase in OPN levels that corresponded with a decline in A $\beta$  deposits in the brains of AD mice (Rentsendorj et al., 2018).

Equally important is the role of TREM2 in CNS physiology, which has been widely recognized in recent years; as genetic variations in TREM2 enhance the risks of developing neurodegenerative diseases, and a surge in TREM2 transcript levels has been reported in AD brains (Sims et al., 2017). TREM2 receptor is shown to be expressed on microglial and dendritic cells and the molecule is now considered to be a crucial regulator of A $\beta$  and tau levels via phagocytosis and plays a role in promoting microglial responses to their accumulation in AD, suggesting that its expression could mirror AD progression (Lee et al., 2018). Notwithstanding the fact that there were no differences in TREM2 in the retinas of AD patients when analyzed with fluorescence using *in situ* hybridization, the overall number of cells expressing TREM2 was much higher in AD retinas compared to the control tissues (Grimaldi et al., 2019), emphasizing that TREM2 expression was indeed increased. Apart from the role of innate immune responses, the S1PR agonist FTY720 which exerts anti-inflammatory actions by reducing the infiltration of lymphocytes to CNS has been shown to protect the neurons in AD (Aytan et al., 2016). Our group has demonstrated that the compound also protects the RGCs in rodent models of experimental glaucoma (You et al., 2014). These findings indicate that targeting S1PR may be useful in imparting neuroprotection to the RGCs in AD and in potentially blocking chronic neuroinflammatory components associated with the disease. This underscores the importance of innate immunity and microglial activation in retinal neurodegenerative changes in AD.

### 6.2. Complement pathway protein changes in retina

The innate immune system and activation of the classical complement pathway plays an important role in regulating normal CNS physiology and tissue reorganization in healthy ageing and AD conditions. Multiple reports that highlight the involvement of complement pathways in AD pathophysiology have generated immense interest in its modulation, in a bid to impart protection against neuronal loss and chronic inflammation. Defective synaptic remodeling has been associated with inconsistent connectivity along the retinogeniculate pathway (Hong and Chen, 2011). C1q, C3, and C4 proteins have been shown to exhibit significant increases in expression in the AD brain (Fonseca et al., 2011). A $\beta$  stimulated the expression of C3 in astrocytes, which in turn suppressed A $\beta$  endocytosis resulting in aggravated AD pathology. In human AD postmortem retina, C3 expression coincided with GFAP-positive cells in the GCL (Fig. 16) and astrocytic activation by C3 has been shown to accelerate the deterioration of synaptic connections in AD. Whether alterations in levels of complement proteins in the retina is a result of increased synthesis or is augmented owing to compromised blood-retinal barrier remains to be established. Enhanced C1q levels in the AD brain have also been shown to correlate with tau protein accumulation (Dejanovic et al., 2018). Intriguingly, the inhibition of the C3a receptor resulted in reduced tau pathology in AD mice (Litvinchuk et al., 2018). Future studies should aim to investigate whether targeting C1q or inhibiting C3a receptor may be an alternative approach to target retinal tau pathology in AD.

Additionally, the expression level of complement factor H, a key repressor of the complement cascade, was reduced in the retina and in the anteroposterior axis of the visual pathway along the superior colliculus and primary visual cortex. This corroborated its reciprocal relationship with A $\beta$ 1-42 in Tg2576 and 5xFAD AD mice models (Alexandrov et al., 2011). This report supports the notion that the suppression of the complement pathway in retina may be inversely related to manifestation of AD pathology. Therapeutically inhibiting the complement pathway was also effective in rescuing the retinal ganglion neurons and imparting protection against synaptic and dendritic

disruption in experimental models of glaucoma (Bosco et al., 2018; Williams et al., 2016). The aggregation of A $\beta$  has further been extensively reported in sub-retinal drusen deposits in AMD and in response to ageing, which could elicit chronic complement activation and the associated degenerative retinal changes (Mirzaei et al., 2020a; Yehoshua et al., 2014). A greater understanding of the relative contribution of different complement pathway proteins that are specific to the retinal changes in AD, will lead to the development of mechanism-based strategies to restrict inflammation and protect the retinal function by augmenting synaptic connectivity and dendritic arborization.

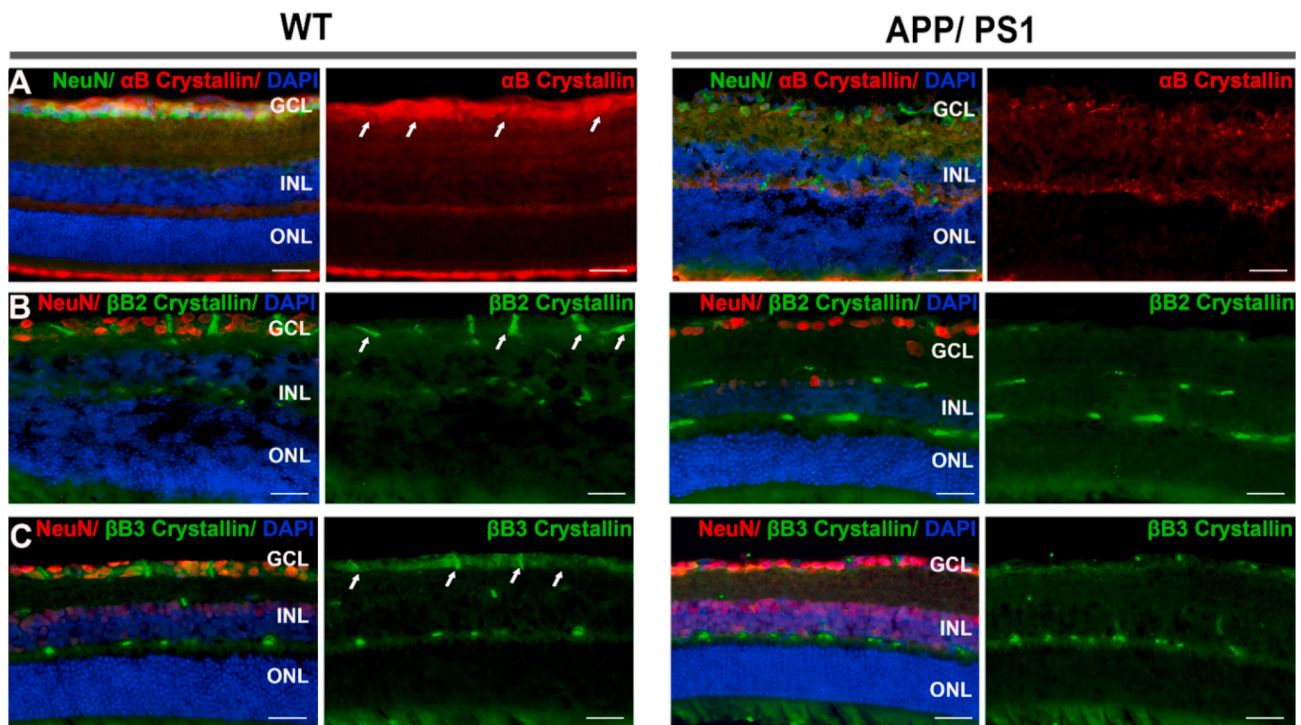
### 6.3. Reduced crystallin levels in the AD retinas

Crystallins are a family of heat-shock adapter proteins that play a role in neuroinflammatory processes in glial cells and protect them against the detrimental effects of misfolded proteins. Crystallins were identified as one of the most downregulated class of proteins in the retinal proteomics analysis of eight-month-old APP/PS1 mice (Mirzaei et al., 2019b). These proteins are involved in neural regeneration and reactive astrogliosis and protect neurons and their dendritic arbor morphology against the toxicity of abnormally folded proteins. Therefore, reduced crystallin levels could make the retinal neurons in AD susceptible to degenerative changes and senescence (Piri et al., 2013). A reduction in the expression of  $\alpha$ -crystallin was observed mainly in the GCL region of APP/PS1 mice (Mirzaei et al., 2019b) (Fig. 17). This crystallin isoform has been shown to colocalize with A $\beta$  aggregates and inhibit their fibrillization and is often part of PHFs and NFTs. Intriguingly, the overexpression of this protein corresponded with diminished tau phosphorylation in N2a neuroblastoma cells, implying that crystallin loss could also potentially exacerbate tau pathological changes in retinal neurons (Ecroyd and Carver, 2009). In addition to decreases in the  $\alpha$ -isoform, a significant loss of  $\beta$ B2-crystallin expression in various layers of the retina in APP/PS1 model using immunofluorescence and proteomics analyses, established this protein as one of the most differentially regulated proteins in AD retina. In a similar manner, the expression of  $\beta$ B3 crystallin was reduced as well, and collectively these findings imply that almost the whole family of these proteins is downregulated in the retina in AD pathology (Mirzaei et al., 2019b) (Fig. 17). Diminishing levels of various crystallin proteins and their transcripts have previously been described in RGCs under experimental glaucoma conditions (Piri et al., 2013). Proteomics investigations have also established reduced levels of various crystallin family members in the initial stages of IOP elevation in the retina. The fact that this trend was subsequently reversed as the disease progressed signifies the time-dependent effects of IOP on crystallin protein expression (Anders et al., 2017a). A potentially relevant finding is that the intravitreal administration of  $\beta$ -crystallin B2 protected the RGCs and retinal nerve fiber layer in case of experimental glaucoma and supported axonal regeneration in optic nerve injury models (Anders et al., 2017b). In agreement with these observations, our recent studies in human postmortem retinal samples established significant downregulation of eleven crystallin family members in POAG (Mirzaei et al., 2017). The downregulation of crystallins in both glaucoma and AD may represent a potential biochemical overlap that underlies these two divergent neurodegenerative disorders. Modulating expression of individual crystallin isoforms in retina using AAV under specific promoters, will elucidate the protective effects of these proteins in AD-induced retinal degenerative changes, thereby advancing future therapeutic developments.

## 7. Primary pathology in retina versus the effect of retrograde degeneration from brain

Apart from neurotoxicity induced by the accumulation of AD hallmark proteins and accompanying inflammatory changes, the retrograde spread of AD pathology from higher visual centers in the brain via optic nerve axons could contribute to retinal pathology. A $\beta$  fibrillization and





**Fig. 17.** Crystallin expression changes in AD retinas. WT and 8-month-old APP/PS1 mice retinas were stained with (A)  $\alpha$ B (B)  $\beta$ 2 and (C)  $\beta$ 3 crystallins. A significant downregulation of all three crystallins was observed in the ganglion cell layer (GCL) of APP/PS1 mice. NeuN was used as ganglion cell marker (A-green; B, C-red). DAPI (blue), ( $n = 3$  each). Data reused with permission of Springer Nature for Mol Neurobiology, 2019, 56, pages 6017–6034 (Mirzaei et al., 2019b). Scale = 50  $\mu$ m. INL, inner nuclear layer, ONL, outer nuclear layer.

plaque formation has been reported in the higher visual centers including in the superior colliculus and primary visual cortex of AD subjects (Aizenstein et al., 2008), and neurodegeneration is indeed known to spread from the brain to anatomically connected neural areas (You et al., 2019). Optic nerve potentially facilitates the vesicular transport and diffusion of APP and tau proteins along RGC axons (Kipfer-Kauer et al., 2010). APP and tau are co-transported with microtubular assemblies via axons that are propelled by kinesin and dynein proteins (Lacovich et al., 2017), which can be a potential mechanism underlying augmentation of the levels of these hallmark proteins in the retina from the brain (Gibbons et al., 2019). However, amyloid and tau aggregation can impair the diffusion of neurotrophins and axonal transport along the microtubular lattice leading to secondary insults. This is coupled with recognition of neuronal loss in the suprachiasmatic nucleus, which is involved in regulating circadian rhythms and the mRGC loss reported in AD could potentially be attributed to the retrograde degenerative changes that arise from this region of the brain (Zhou et al., 2016). Similar retrograde transmission of neurodegenerative changes to the retina has been demonstrated in MS pathology (Klistorner et al., 2017). Meanwhile, glaucoma has been shown to propagate molecular and structural deficits in the higher visual centers through anterograde spread of degenerative changes that are believed to emanate primarily from the retina (You et al., 2019). If retrograde transsynaptic degeneration in AD plays a consequential role, neural changes in the higher visual centers in the brain are expected to topographically correlate with anatomically communicating regions of the retina. This can be investigated using combined brain and retinal imaging/functional studies, visual field assessment as well as through post-mortem analysis. This is of critical importance since increasing evidence from AD animal models shows that  $A\beta$ /tau protein alterations in AD may manifest in the retina prior to the brain, and this suggests that retinal disparities are more likely to be a primary pathology in AD (Koronyo-Hamaoui et al., 2011; Mirzaei et al., 2019b). However, the potential of secondary contributions induced by brain changes cannot be

underestimated.

The correlation of retrograde changes in the retina in response to brain pathology was recently investigated by Haan et al. (2019), where they studied retinal thinning in a cohort of posterior cortical atrophy (PCA) subjects (den Haan et al., 2019). PCA is an atypical form of AD in which visual cortex and associated areas are specifically involved in the AD pathological process leading to remarkable visual symptomatology (Crutch et al., 2017). A correlation analysis of visual rating scores for cortical atrophy as measured by MRI, with pRNFL and total macular thickness changes in OCT revealed that while cortical thickness was discriminative between AD and controls, the retinal changes were not. This suggested smaller effect size in the retinal tissue compared to the brain. Further a comparison of pRNFL and macular thickness changes in healthy control and early onset AD (EOAD) patients with evidence of amyloid pathology in the brain demonstrated that retinal changes in general correlated with the extent of parietal cortical atrophy, but did not discriminate EOAD cases from controls (den Haan et al., 2018a). These findings suggested a relationship of retinal changes with visual cortex but also indicated that these changes were independent of amyloid pathology in the brain and could be more a reflection of ageing effects. Longitudinal follow up studies with sub-layer analysis of different regions of the retina are likely to provide further insights into the retrograde effects of AD pathology in the retina.

## 8. Overlap of retinal AD changes from other ocular disorders

Several neurodegenerative conditions of the brain such as AD, MS, Huntington's, and Parkinson's diseases have manifestations in the eye that foreshadow or continue concurrently with CNS pathology (Gupta et al., 2016a; Lee et al., 2019; London et al., 2013). Usually, these diseases have distinct clinical features to facilitate a differential diagnosis. However, several molecular and pathological aspects of AD overlap with glaucoma and AMD, including the deposition of archetypal proteins  $A\beta$  and tau in the retina (Gupta et al., 2016a). This means detectable

changes in the eye need to be considered in the light of other clinical signs and risk factors. A $\beta$  accumulation is associated with approximately 40% drusen and subretinal deposits in AMD patients, while it is detected as small, diffused fibrillar extracellular deposits in the inner retinal layers in AD (Curcio, 2018; Gupta et al., 2016a; Zhao et al., 2015). Interestingly, the administration of A $\beta$  antibodies targeting the c-terminal of the peptide in a mouse model of macular degeneration was shown to be protective for RPE and the retinal ultrastructure by reducing A $\beta$  levels (Ding et al., 2011). Parallel to this, vaccination against A $\beta$  peptides resulted in reduced retinal A $\beta$  plaque formation in Tg2576 AD model (Liu et al., 2009). Furthermore, studies have demonstrated an association between A $\beta$  deposition and hyper-phosphorylated tau with ganglion cell degeneration in glaucoma, whereby A $\beta$  deposition has been shown to be more localized in the inner retinal layers in glaucomatous eyes. Reports also indicate a higher prevalence of glaucoma in AD and that both the diseases are associated with progressive neural and vascular degenerative changes including microbleeds (Bayer et al., 2002; Golzan et al., 2017; Gupta et al., 2014b). Animal and human postmortem studies indicate increased levels of neurotoxic A $\beta$  and its aggregates in the inner retina which correlates with RGC apoptosis in cases of both glaucoma and AD (Gupta et al., 2014b). Apart from the effects of neurodegenerative disorders mentioned above, ageing remains a primary risk factor that induces prominent molecular, functional, and structural alterations in the retina in both healthy and disease states. Ageing is associated with progressive thinning of retinal layers. Ultrastructural analysis has revealed histopathological thickening of the RPE-Bruch's membrane region with concomitant loss of the fenestration of the choroidal small vessels (Ida et al., 2004). OCTA analysis has demonstrated a similar loss of choroidal capillary bed in ageing subjects (Camino et al., 2019). These age-related changes are invariably associated with enhanced accumulation of drusen and pigment deposits that may in turn give rise to chronic inflammation. Enhanced accumulation of amyloid  $\beta$  peptides in the photoreceptors, RPE and the adjoining capillaries along with subretinal macrophage build-up has been reported with age in both human tissues as well as in rodent models (Hoh Kam et al., 2010). Similar to that observed in the brain, age associated changes in the retina thus exhibit an overlap with effects of AD and could influence the early detection of AD associated symptoms in the eyes.

Our studies revealed that this increase in retinal A $\beta$  was more pronounced in *BDNF* impaired animals, suggesting a key role of *BDNF* in regulating A $\beta$  deposition in the retina (Gupta et al., 2014b). Elevated A $\beta$  levels were also detected in the inner retinal layers and optic nerve of DBA/2J mice that progressively develop glaucomatous changes in the retina with age. Similar to human AD post-mortem retinal tissues, human glaucoma retinas also exhibit increased A $\beta$  levels, and this makes it important to understand the molecular similarities and differences in the way these two diseases affect the neural tissue (Gupta et al., 2014b) (Fig. 15). Retinal imaging has revealed differences in the thickness of pRNFL and macular GCL regions, as well as an augmented global loss volume in both AD and glaucoma, although these deficits are clearly more marked in glaucoma patients as the disease progresses (Wang et al., 2018). Other points of differentiation include greater propensity for superior RNFL losses in AD as opposed to inferior RNFL deficits in the early stages of glaucoma. A possible distinction is the increase in IPL thickness in early stages of AD/MCI prior to thinning as opposed to inner retinal thinning associated with glaucoma neurodegeneration. Similarly, electrophysiological parameters that predominantly represent ganglion cell function have been reported to be affected in both glaucoma and AD. Prior research has described degenerative changes in the inner retinal layers, including reduced electrophysiological responses, in both AD and experimental glaucoma animal models (Gupta et al., 2016b). In contrast, abnormalities in the retinal vascular architecture and blood flow, the loss of RGCs in foveal region as well as NFL and choroidal degeneration have been reported in both AD and AMD patients (Cunha et al., 2016a). Along with it, shared determinants of the

dysregulation of the complement system suggest that the involvement of common inflammatory mechanisms, increased oxidative damage, and mitochondrial impairment are common features of both AMD and AD pathologies.

There are although, spatial differences within retina that can be used to further understand and demarcate pathological changes between these disorders. For instance, while AD retinas involve NFL and GCL losses along with protein aggregation pathology, which is reported to be more prevalent in the peripheral superior quadrant; glaucoma predominantly affects inner retina with optic nerve excavation and axonal damage. AMD patients in contrast, show deficits in the central visual field, which is at variance with inferior visual field deficits reported in AD (Berisha et al., 2007). AMD is typically associated with progressive photoreceptor and RPE degenerative changes, while AD and glaucoma predominantly affect the GCL and NFL (Golzan et al., 2017; Ohno-Matsui, 2011). The characteristic patterns of neural and functional loss in glaucoma and AMD are well recognized, usually with quite different characteristics. Importantly, pigment deposition and drusen agglomerates frequently occur in the retinas of elderly people and can exhibit a wide degree of variation across different populations. This can interfere with retinal imaging by generating significant background noise and auto-fluorescence that needs to be filtered.

Our quantitative proteomics studies have revealed that several of the biochemical pathways are affected in a similar manner in the retina in glaucoma and AD conditions. For instance, mitochondrial function and oxidative phosphorylation are affected in both glaucoma and AD (Almasieh et al., 2012; Mirzaei et al., 2017, 2019b) and this makes RGCs particularly vulnerable to degenerative changes due to their high metabolic activity. Studies have shown that treatment with ubiquinone, electron acceptor in complex 1 and 2 of mitochondria can protect RGCs in glaucoma. Conversely blocking dynamin-related protein 1 (Drp1) which is key component of mitochondrial fission process was also shown to protect the RGCs in glaucoma model (Kim et al., 2015). Mitochondrial targeting may thus have important implications in protecting RGCs against degenerative changes in AD.

To date, the dominant viewpoint is that there is molecular overlap between these degenerative processes, and they may commonly co-exist in the same individual. This limits our current investigative tools to differentiate structural, functional, or physiological/blood flow changes in these disorders in early stages, even though they have some characteristic features. It also raises a question of whether AD with glaucoma symptoms is a different AD variant? Nonetheless, it is tempting to speculate that co-existence of glaucoma in AD may serve as a possible lead to discover new pathophysiological processes in both diseases. Currently, our inability to detect retinal molecular neuropathological changes by imaging technologies, precludes definitive AD diagnoses and monitoring. Future imaging advances may provide more disease specific recognition.

## 9. Clinical trials involving retinal changes in AD

Investigations into retinal changes in AD patients, post-mortem samples and animal models has gradually paved way for clinical trials in the last few years. As of 4th July 2020, there are at least 19 currently recruiting or recently completed studies that are registered as clinical trials in [ClinicalTrials.gov](https://clinicaltrials.gov/) database (<https://clinicaltrials.gov/>). This registry is maintained by National Library of Medicine at the National Institute of Health (NIH), USA (Table 1). The listed studies are primarily focussed on investigating retinal amyloid deposition and different aspects of retinal and other ocular changes in MCI and AD subjects. The projected number of participants in most of these studies range from below one hundred to approximately two hundred on average, however some of the collaborative studies have much larger projected enrolment numbers. For instance, Janssen Research & Development/Janssen Research & Development sponsored trial (NCT02114372) based in UK aims to recruit 1137 subjects in their prospective cognitive health in

**Table 1**

Ongoing and Completed Clinical Trials investigating effects of AD on retina and other ocular changes (Status: R-Recruiting; C-Completed; A- Active, Not Recruiting).

Identifier/ Status	Title	Study Start	Study End	Interventions	Number	Sponsor/Collaborators/Location
NCT03420807 (R)	Retinal Metabolic Imaging of Alzheimer Patient	Dec 2017	Sep 2020	Device: MHRC	50	Optina Diagnostics Inc.; Sunnybrook Health Sciences Centre; McGill University; Polytechnique Montreal, Canada.
NCT01555827 (C)	Retinal Neurodegenerative Signs in Alzheimer's Diseases	Mar 2012	Jun 2014	Ophthalmological examination & Questionnaire	200	University Hospital Bordeaux, France
NCT03466177 (R)	Multimodal Retinal Imaging in the Detection and Follow-up of Alzheimer's Disease	Apr 2018	Dec 2020	Non-invasive, multimodal retinal imaging; Cerebral imaging; Neuropsychiatric testing; Venous blood sampling	90	Universitaire Ziekenhuizen Leuven, Leuven, Belgium
NCT02360527 (C)	Retinal Neurodegeneration in Type 2 Diabetes as Biomarker for Alzheimer's Disease	Sep 2014	Dec 2015		126	Hospital Universitari Vall d'Hebron Research Institute, Barcelona, Spain
NCT03447613 (C)	Retinal Nerve Fiber Layer Thickness and Cerebrospinal Fluid A $\beta$ /Tau	Aug 2013	Dec 2014	Procedure: surgery	86	Shanghai 10th People's Hospital; Massachusetts General Hospital
NCT02530255 (C)	Telomerase Activator and Retinal Amyloid	Dec 2016	Dec 2018	Dietary Supplement: Cycloastragenol and Placebo	48	Chippewa Valley Eye Clinic, Wisconsin, USA; TA-Sciences, USA
NCT03319810 (C)	Effect of IVIG on Cerebral and Retinal Amyloid in Mild Cognitive Impairment Due to Alzheimer Disease	Jan 2018	Jul 2018	Biological: Octagam 10%	5	Sutter Health, Sutter Neuroscience Medical Group, CA, USA
NCT03233646 (R)	OCTA in Mild Cognitive Impairment and Alzheimer's Disease	Jul 2017	Apr 2021	Device: Retinal Imaging	1000	Duke University Medical Center, North Carolina, USA; Alzheimer's Drug Discovery Foundation; University of Edinburgh, UK
NCT03761381 (R)	OCT Angiography and NRAI in Dementia	Sept 2018	Dec 2020	Device: Optical Coherence Tomography Angiography (OCTA) Imaging; Device: Noninvasive Retinal Amyloid Imaging (NRAI)	20	Oregon Health & Science University, Oregon, USA
NCT01937221 (C)	Novel Retinal Imaging Biomarkers in Early Alzheimer's Disease	Sep 2013	Jul 2017	Other: spectral domain Optical coherence tomography (SDOCT)	60	Duke University Medical Center; Duke Institute for Brain Sciences, North Carolina, USA; Alzheimer's Association; Duke-NUS Graduate Medical School.
NCT03859245 (R)	Photobiomodulation & Ketogenic Diet for Treatment of Mid-periphery Retinal Disorders for Alzheimer's Disease Prevention	Feb 2019	Sep 2020	Behavioral: Photobiomodulation; Behavioral: Ketogenic diet	30	Bristlecone Health, Inc.; University of Minnesota; Yankee Eye Clinic, MN, USA
NCT02663531 (R)	Retinal Neuro-vascular Coupling in Patients with Neurodegenerative Disease	Sep 2016	Dec 2020	Device: DVA; Device: FDOCT; Device: Pattern ERG; Device: Optical Coherence Tomography	150	Department of Clinical Pharmacology, Medical University of Vienna, Austria
NCT00921297 (C)	Cataract Removal and Alzheimer's Disease	Jun 2009	Mar 2017	Procedure: Immediate Cataract Surgery	122	University Hospitals Case Medical Center, OH; MetroHealth Medical Center, OH, Case Western Reserve University; National Institute on Aging (NIA), USA
NCT02524405 (R)	BEAM: Brain-Eye Amyloid Memory Study	Feb 2016	Dec 2021	Other: Pittsburgh Compound B [11C]-PIB	345	Centre for Addiction and Mental Health; Kensington Eye Institute; Brain Canada; Weston Brain Institute; GE Healthcare; Sunnybrook Health Sciences Centre; St. Michael's Hospital; University Health Network Canada; Baycrest Health Sciences, Canada.
NCT02264899 (A)	MEMENTO-VAScular Components of Dementia	Nov 2014	Dec 2020	Other: in Memento-VASCOD	350	CHU d'Amiens; CHU de Bordeaux – Pellegrin; CHU de Dijon; CHU de Lille; Hospices civils de Lyon; AP-HM, Marseille; CHU de Montpellier; AP-HP - Hôpital BROCA; AP-HP - Hôpital LARIBOISIERE; CHU de Strasbourg, France; Ministry for Health and Solidarity, France.
NCT02114372 (A)	Cognitive Health in Ageing Register: Investigational, Observational and Trial Studies in Dementia Research: Prospective Readiness Cohort Study	Feb 2014	Apr 2023		1137	Janssen Research & Development, LLC; Edinburgh, United Kingdom
NCT01630525 (C)	The Eyes Have it: Ocular Saccade Abnormalities in Prodromal Alzheimer's Disease	Dec 2012	Dec 2015	Other: Neuropsychological Assessment; Other: Ophthalmologic checkup; Other: Automated non-invasive oculometry	83	University Hospital, Bordeaux; Lyon University Hospital; AP-HM, Marseille, France
NCT02141971 (C)	Down Syndrome Biomarker Initiative (DSBI)	Jun 2013	Apr 2017		12	Michael Rafii; Janssen Research & Development, LLC; University of California, San Diego, USA
NCT04104373 (C)	The Ontario Neurodegenerative Disease Research Initiative	Jul 2014	Apr 2018	Other: Observational Cohort	522	Ontario Neurodegeneration Disease Research Initiative; Hamilton Health Sciences Centre; Providence Care Mental Health Services; London Health Sciences Centre; Parkwood Institute; The Ottawa

(continued on next page)

Table 1 (continued)

Identifier/ Status	Title	Study Start	Study End	Interventions	Number	Sponsor/Collaborators/Location
						Hospital; Elisabeth Bruyere, Ottawa; Thunder Bay Regional Research Institute; Sunnybrook Health Sciences Centre; St. Michael's Hospital; University Health Network; Baycrest, Toronto; Centre for Addiction and Mental Health, Ontario, Canada

ageing registry. Similarly, Ontario Neurodegeneration Disease Research Initiative (NCT04104373) with 522 participants is aimed to document retinal nerve imaging, best corrected visual acuity, and eye movement – both pro-saccade and anti-saccade changes in AD subjects over a period of 5 years. The University Hospital, Bordeaux (France) sponsored Memento-VASCOD study (NCT02264899) aims to enrol 350 subjects and determine the association between retinal vasculature defects and brain neurovascular damages in a multicentre longitudinal cohort study. This study has proposed extensive retinal imaging and visual acuity measurements along with cerebral MRI and neuropsychological testing. BEAM: Brain-Eye Amyloid Memory Study is another large-scale trial facilitated by Sunnybrook Health Sciences Centre, Canada (NCT02524405). It is aimed to investigate OCT and eye tracking changes in MCI and AD subjects. The study has proposed to collect data on retinal blood vessel diameter and RNFL changes and correlate findings with brain MRI and amyloid  $\beta$  PET data. Further “OCTA in MCI and AD” is an important trial supported by Duke university (NCT03233646) which has an estimated enrolment of 1000 subjects. This non-randomised trial aims to develop and evaluate vascular biomarkers using OCTA to assess structural and functional aspects of retinal microvasculature alterations in MCI and AD subjects. Thus, this research study is designed to provide a proof-of-concept for retinal microvascular changes as an effective screening tool in AD diagnosis. (Table 1).

The majority of these studies are in various stages of their progress or have been completed recently and therefore have not yet posted the results in public domain. The outcomes from at least some of these clinical trials will inform further research in the field including the need to incorporate measurement of retinal changes in various randomised AD drug trials. A relatively smaller study on “Retinal Metabolic Imaging of Alzheimer Patient” is sponsored by Optina Diagnostics (NCT03420807) which has a proposed enrolment of 50 subjects. Optina has developed a metabolic hyperspectral retinal camera (MHRC) and this trial seeks to differentiate MCI, AD and control subjects based on retinal hyperspectral signature using this instrument. This interventional study (Dec 2017–Sep 2020) is aimed to evaluate the feasibility of detection of A $\beta$  using hyperspectral camera and detect specific autofluorescence or reflectance signature in the retina of AD subjects. A key objective of the study is to establish whether spectrally resolved A $\beta$  deposition in the retina of AD subjects correlates with brain A $\beta$  plaques as detected by 18F-florbetaben amyloid PET scanning. Recently published data from this study revealed retinal vascular texture measure differences including higher mean venular tortuosity in 20 cognitively impaired subjects compared to a set of 26 cognitively normal people, in the spectral range of 450–550 nm (Sharafi et al., 2019). Differences in the retinal reflectance signature in AD subjects at around 550 nm were also reported independently in another cross-sectional study in a cohort of 35 participants comprising 15 MCI and 20 control subjects and the MHRC data was shown to correlate with brain amyloid PET scores (Hadoux et al., 2019). More recently, Optina retinal imaging technology has achieved breakthrough device recognition from US FDA to support AD diagnosis and this designation is likely to expedite the development of the concept of hyperspectral imaging to identify specific changes in the retina in AD.

In addition to these ongoing and accomplished studies, there are at least 15 more studies listed in [ClinicalTrials.gov](https://www.clinicaltrials.gov) registry which are

either not yet recruiting or have since been withdrawn. For instance, the five-year longitudinal “Atlas of Retinal Imaging in Alzheimer’s Study” (ARIAS) (NCT03862222) sponsored by University of Rhode Island Red (Dec 2019 to Nov 2024) has a projected recruitment of 330 subjects. This study intends to examine the natural history of retinal imaging biomarkers associated with disease risk, disease burden, and progression in AD. A primary objective of this project is to create a reference database which can serve as gold standard for anatomical and functional imaging of the retina, in order to identify and develop sensitive and reliable markers of AD risk and/or progression. In addition, Moorfields Eye Hospital, UK has recently sponsored a three-year (Sep 2019–Aug 2022) retrospective study “Detecting Dementia in the Retina Using Optical Coherence Tomography” (NCT03631069). The investigators in this study have proposed to analyse repository of around one million OCT retinal scans, performed on patients since 2008, using various computational tools. This data will then be linked with other clinical data to establish whether the subjects were diagnosed with or went on to develop AD. A shortcoming of these clinical studies is that apart from significant heterogeneity amongst populations, different regions and cells of the retina can be affected differently. Therefore, it may not be possible to make a sweeping statement of the applicability of findings to all AD patients. More meaningful data can be generated by the design of longitudinal randomised controlled trials, which will however, require a significant collaborative effort between various vision and AD research groups and industry partners.

## 10. Conclusions, future directions and challenges

Recent research suggests that preclinical or quiescent stages of the disease might provide a critical window to initiate an effective therapy for the disease, which makes it critical to establish an early and reliable biomarker (Frisoni et al., 2017). The concept of early manifestation of AD related changes in the retina has evolved in recent years, which is supported by reports of alterations in AD prototypal proteins and accompanying neuronal injury and cell death in different regions of the retina. The clear optical path of the eye lends itself better for the detection of posterior segment changes at micrometer resolution, through visible and near infrared light-based ocular imaging modalities, and adaptive optics and functional OCT may take this to the next level. This provides a potential opportunity in AD biomarker research to identify and monitor the effects of AD on the retina, should future technologies be able to identify reproducible changes. The degeneration of RGCs and the corresponding axonal thinning of RNFL are key structural differences that have been reported in AD using OCT. Advancements in OCT/OCTA have led to several reports of manifest correlations of retinal structural and vascular differences with the visual and cognitive vulnerability. This emphasizes the great utility of clinical imaging technologies in potentially assessing the subtle, yet discrete changes associated with various stages of AD. As technological advancements continue to gain momentum, we envision that well-designed long term follow up studies will elucidate the clinical utility of monitoring retinal changes in AD patients. The trajectory of changes could then be used either alone or in combination with other measures to reach clinical decisions. For instance, retinal imaging modalities such as OCT may potentially be used in combination with blood

biomarker testing to screen at-risk populations. The positive patients can then be asked to undergo detailed brain imaging or CSF sampling to establish and monitor the disease process.

Pre-clinical research using animal models and human post-mortem studies have unraveled some of the novel mechanisms that underlie the disease process in the retinal tissues. For instance, increased APP levels, in the absence of typical brain-like extracellular A $\beta$  plaque formation, could indicate discrete regulation of amyloidogenic and non-amyloidogenic pathways in the retina compared to the brain. Summarizing, despite the progress, a clear knowledge of the events that occur in the retina in various stages of AD pathophysiological process are lacking. Knowledge of these changes and comparing characteristic manifestations of the disease in brain, will enhance our understanding of AD neuropathology. In this review, we have endeavored to highlight several seminal studies that have enhanced our understanding of various aspects of amyloid and tau aggregation, structural and functional neurodegeneration, vascular changes and other molecular neuropathology of the retinal changes in AD. However, there are also several gaps in the field that impede establishing retinal changes as an AD biomarker and many questions remain unanswered, some of which are listed below:

- ✓ First, what is the extent of amyloid and tau protein aggregation in the retina in various stages of AD? Are these changes localized to specific types of cells or layers of the retina?
- ✓ Why are the retinal protein aggregates morphologically different from the brain deposits? Is it because retinal neural tissue is more resistant to AD pathology compared to the brain? Further, in contrast to the brain tissue, do amyloid and tau protein changes play a neutral, neurotoxic, or protective role in the retina.
- ✓ Determining whether retina is a primary site of AD pathology and establishing the contributions of retrograde degenerative changes in inducing retinal pathology.
- ✓ Although several groups are pursuing molecular imaging of retinal changes in AD using HSI, there is dearth of longitudinal studies in well-defined cohorts, that can establish it as a meaningful clinical tool. Determining what molecular and structural factors may together contribute to these imaging differences remains a challenge.
- ✓ Apart from amyloid and tau, what are the other molecular, structural/vascular alterations that retina undergoes in early and later stages of the disease? This data will provide more comprehensive insights into the disease mechanisms. Whether any of the molecular retinal changes such as inflammation and apoptosis can be imaged in the retina with enough specificity and sensitivity, is an open question.
- ✓ What is the overlap of retinal AD changes with ageing and with other retinal disorders such as AMD and glaucoma? Recognizing the molecular differences, will help address key questions, such as what makes ApoE 4 and 2 genotypes to show opposite behavior in AD and AMD pathologies.
- ✓ Finally, can AD targeting drugs protect the retina against various changes in early and later stages of the disease.

The next few years may provide us exciting outcomes with more clarity on underlying mechanisms and the extent of retinal changes in AD. The field will have to simultaneously work on multiple fronts and correlate mechanistic knowledge from pre-clinical and postmortem studies with the clinical data to reach meaningful conclusions.

Limited availability of human ageing donor retinal tissues that are harvested immediately after death and stored appropriately, remains a challenge. The post-mortem retinal differences may be confounded by several unknown factors such as the existence of co-morbid neurodegenerative and other conditions as well as chronic exposure to therapeutic drugs while the subjects were alive. Thus, there is a need for a collaborative effort to develop a well-defined cohort of post-mortem ocular tissues from AD and pre-clinical AD subjects, that can be correlated with respective brain tissues and data. Further, both retinal

structure and physiology depict considerable similarities between rodents and humans, and there is certain degree of neuropathological and behavioral recapitulation of AD symptoms in transgenic animal models. However, we need to be cognizant that most of the therapies such as semagacestat, solanezumab, verubecestat etc. that worked in AD mice models, ultimately failed to meet the primary endpoints in human trials, indicating fine pathophysiological differences between species (Egan et al., 2019; Gupta et al., 2013; Honig et al., 2018). These examples serve as salient reminders that transgenic animal models may not represent predominant sporadic form of AD pathology, and that establishing more relevant models is desirable. AAV mediated gene therapy is a fast-emerging approach that has the potential to be used in pre-clinical AD models to identify the disease mechanisms. Tissue specific inducible knock-out and overexpression mice models using CRISPR, cre/lox and AAV will provide distinct opportunities to study the roles of AD associated proteins in specific retinal cells. This will also allow performing rescue experiments and study the effects of retrograde/anterograde degenerative changes between the brain and the retina.

Finally, as mentioned above, our ability to image the AD-associated neuropathological remodeling that occurs in the retina and differentiating these changes from normal ageing process and other individual characteristics remains a foremost challenge, and in this regard, HSI appears to be a promising start. The ability to monitor molecular changes will provide a robust tool to explore the disease mechanisms and to monitor responses to interventions. In addition to monitoring amyloid deposition, future research should target the molecular imaging of tau phosphorylation, neuroinflammatory markers and early apoptotic changes in the AD retina for multipronged, tiered approach. Their use as retinal biomarkers in AD will be empowered by determining correlation of their longitudinal changes with neurocognitive and brain imaging pathologies, recognizing that certain ocular biomarkers might work better for diagnosis and others for staging. Correlating retinal changes with brain data will also help normalize inherent variability in longitudinal follow-up studies and establish the reliability of retinal functional and imaging tests in AD subjects. Future research will establish whether the distribution of A $\beta$  build-up in the intracellular and extracellular retinal compartments differs from that observed in brain tissue. Deciphering these mechanisms will unravel the extent to which retinal changes may serve as non-invasive AD biomarkers and will provide information regarding the susceptibility or resilience of specific neuronal populations to amyloid and tau pathology in the retina. In conclusion, our ability to comprehend the impact of AD on the retina will have broad implications in determining whether the eyes should be monitored more closely during AD progression. This will ultimately contribute to improved AD diagnosis and disease management.

#### Author statement

The authors declare that they do not have any known conflicts of interest.

#### Declaration of competing interest

The authors declare that they have no conflicts of interests.

#### Acknowledgements

We acknowledge funding support from National Health and Medical Research Council (NHMRC) of Australia (1136602, 1139560), Perpetual Hilcrest, Ophthalmic Research Institute of Australia (ORIA) and Macquarie University, NSW, Australia. SDA acknowledges the funding support from the CrestOptics-IIT JointLab for Advanced Microscopy, Italy.

## References

- Abbasi, M., Gupta, V., Chitranshi, N., You, Y., Dheer, Y., Mirzaei, M., Graham, S.L., 2018. Regulation of brain-derived neurotrophic factor and growth factor signaling pathways by tyrosine phosphatase Shp2 in the retina: a brief review. *Front. Cell. Neurosci.* 12, 85.
- Abbasi, M., Gupta, V.K., Chitranshi, N., Gupta, V.B., Mirzaei, M., Dheer, Y., Garthwaite, L., Zaw, T., Parton, R.G., You, Y., Graham, S.L., 2020. Caveolin-1 ablation imparts partial protection against inner retinal injury in experimental glaucoma and reduces apoptotic activation. *Mol. Neurobiol.* 57, 3759–3784.
- Aizenstein, H.J., Nebes, R.D., Saxton, J.A., Price, J.C., Mathis, C.A., Tsopelas, N.D., Ziolkowski, S.K., James, J.A., Snitz, B.E., Houck, P.R., Bi, W., Cohen, A.D., Lopresti, B.J., DeKosky, S.T., Halligan, E.M., Klunk, W.E., 2008. Frequent amyloid deposition without significant cognitive impairment among the elderly. *Arch. Neurol.* 65, 1509–1517.
- Alexandrov, P.N., Pogue, A., Bhattacharjee, S., Lukiw, W.J., 2011. Retinal amyloid peptides and complement factor H in transgenic models of Alzheimer's disease. *Neuroreport* 22, 623–627.
- Almasieh, M., Wilson, A.M., Morquette, B., Cueva Vargas, J.L., Di Polo, A., 2012. The molecular basis of retinal ganglion cell death in glaucoma. *Prog. Retin. Eye Res.* 31, 152–181.
- Anders, F., Teister, J., Funke, S., Pfeiffer, N., Grus, F., Solon, T., Prokosch, V., 2017a. Proteomic profiling reveals crucial retinal protein alterations in the early phase of an experimental glaucoma model. *Graefes Arch. Clin. Exp. Ophthalmol.* 255, 1395–1407.
- Anders, F., Teister, J., Liu, A., Funke, S., Grus, F.H., Thanos, S., von Pein, H.D., Pfeiffer, N., Prokosch, V., 2017b. Intravitreal injection of beta-crystallin B2 improves retinal ganglion cell survival in an experimental animal model of glaucoma. *PLoS One* 12, e0175451.
- Andreone, B.J., Przybyla, L., Llapashtica, C., Rana, A., Davis, S.S., van Lengerich, B., Lin, K., Shi, J., Mei, Y., Astarita, G., Di Paolo, G., Sandmann, T., Monroe, K.M., Lewcock, J.W., 2020. Alzheimer's-associated PLCgamma2 is a signaling node required for both TREM2 function and the inflammatory response in human microglia. *Nat. Neurosci.* 23 (8), 927–938. <https://doi.org/10.1038/s41593-020-0650-6>.
- Ascaso, F.J., Cruz, N., Modrego, P.J., Lopez-Anton, R., Santabarbara, J., Pascual, L.F., Lobo, A., Cristobal, J.A., 2014. Retinal alterations in mild cognitive impairment and Alzheimer's disease: an optical coherence tomography study. *J. Neurol.* 261, 1522–1530.
- Aso, E., Lomoio, S., Lopez-Gonzalez, I., Joda, L., Carmona, M., Fernandez-Yague, N., Moreno, J., Juves, S., Pujol, A., Pamplona, R., Portero-Otin, M., Martin, V., Diaz, M., Ferrer, I., 2012. Amyloid generation and dysfunctional immunoproteasome activation with disease progression in animal model of familial Alzheimer's disease. *Brain Pathol.* 22, 636–653.
- Aytan, N., Choi, J.K., Carreras, I., Brinkmann, V., Kowall, N.W., Jenkins, B.G., Dedeoglu, A., 2016. Fingolimod modulates multiple neuroinflammatory markers in a mouse model of Alzheimer's disease. *Sci. Rep.* 6, 24939.
- Bahmani, P., Schellenberger, E., Klohs, J., Steinbrink, J., Cordell, R., Zille, M., Müller, J., Harhausen, D., Hofstra, L., Reutlingsperger, C., Farr, T.D., Dirnagl, U., Wunder, A., 2011. Visualization of cell death in MICE with focal cerebral ischemia using fluorescent annexin A5, propidium iodide, and tunel staining. *J. Cerebr. Blood Flow Metab.* 31, 1311–1320.
- Bai, B., Hales, C.M., Chen, P.C., Gozal, Y., Dammer, E.B., Fritz, J.J., Wang, X., Xia, Q., Duong, D.M., Street, C., Cantero, G., Cheng, D., Jones, D.R., Wu, Z., Li, Y., Diner, I., Heilman, C.J., Rees, H.D., Wu, H., Lin, L., Szulwach, K.E., Gearing, M., Mufson, E.J., Bennett, D.A., Montine, T.J., Seyfried, N.T., Wingo, T.S., Sun, Y.E., Jin, P., Hanfelt, J., Willcock, D.M., Levey, A., Lah, J.J., Peng, J., 2013. U1 small nuclear ribonucleoprotein complex and RNA splicing alterations in Alzheimer's disease. *Proc. Natl. Acad. Sci. U. S. A.* 110, 16562–16567.
- Bai, B., Wang, X., Li, Y., Chen, P.C., Yu, K., Dey, K.K., Yarbro, J.M., Han, X., Lutz, B.M., Rao, S., Jiao, Y., Sifford, J.M., Han, J., Wang, M., Tan, H., Shaw, T.L., Cho, J.H., Zhou, S., Wang, H., Niu, M., Mancieri, A., Messler, K.A., Sun, X., Wu, Z., Pagala, V., High, A.A., Bi, W., Zhang, H., Chi, H., Haroutunian, V., Zhang, B., Beach, T.G., Yu, G., Peng, J., 2020. Deep multilayer brain proteomics identifies molecular networks in Alzheimer's disease progression. *Neuron* 105, 975–991 e977.
- Bayer, A.U., Ferrari, F., Erb, C., 2002. High occurrence rate of glaucoma among patients with Alzheimer's disease. *Eur. Neurol.* 47, 165–168.
- Bell, R.D., Zlokovic, B.V., 2009. Neurovascular mechanisms and blood-brain barrier disorder in Alzheimer's disease. *Acta Neuropathol.* 118, 103–113.
- Benilova, I., Karran, E., De Strooper, B., 2012. The toxic Abeta oligomer and Alzheimer's disease: an emperor in need of clothes. *Nat. Neurosci.* 15, 349–357.
- Berisha, F., Feke, G.T., Trempe, C.L., McMeel, J.W., Schepens, C.L., 2007. Retinal abnormalities in early Alzheimer's disease. *Invest. Ophthalmol. Vis. Sci.* 48, 2285–2289.
- Blanks, J.C., Hinton, D.R., Sadun, A.A., Miller, C.A., 1989. Retinal ganglion cell degeneration in Alzheimer's disease. *Brain Res.* 501, 364–372.
- Blanks, J.C., Schmidt, S.Y., Torigoe, Y., Porrello, K.V., Hinton, D.R., Blanks, R.H., 1996a. Retinal pathology in Alzheimer's disease. II. Regional neuron loss and glial changes in GCL. *Neurobiol. Aging* 17, 385–395.
- Blanks, J.C., Torigoe, Y., Hinton, D.R., Blanks, R.H., 1996b. Retinal pathology in Alzheimer's disease. I. Ganglion cell loss in foveal/parafoveal retina. *Neurobiol. Aging* 17, 377–384.
- Blennow, K., Dubois, B., Fagan, A.M., Lewczuk, P., de Leon, M.J., Hampel, H., 2015. Clinical utility of cerebrospinal fluid biomarkers in the diagnosis of early Alzheimer's disease. *Alzheimers Dement* 11, 58–69.
- Bosco, A., Anderson, S.R., Breen, K.T., Romero, C.O., Steele, M.R., Chiodo, V.A., Boye, S.L., Hauswirth, W.W., Tomlinson, S., Vetter, M.L., 2018. Complement C3-targeted gene therapy restricts onset and progression of neurodegeneration in chronic mouse glaucoma. *Mol. Ther.* 26, 2379–2396.
- Braak, H., Braak, E., 1991. Neuropathological staging of Alzheimer-related changes. *Acta Neuropathol.* 82, 239–259.
- Brettschneider, J., Del Tredici, K., Lee, V.M., Trojanowski, J.Q., 2015. Spreading of pathology in neurodegenerative diseases: a focus on human studies. *Nat. Rev. Neurosci.* 16, 109–120.
- Bruban, J., Glotin, A.L., Dinet, V., Chalour, N., Sennlaub, F., Jonet, L., An, N., Faussat, A.M., Mascarelli, F., 2009. Amyloid-beta(1-42) alters structure and function of retinal pigmented epithelial cells. *Aging Cell* 8, 162–177.
- Bu, X.L., Xiang, Y., Jin, W.S., Wang, J., Shen, L.L., Huang, Z.L., Zhang, K., Liu, Y.H., Zeng, F., Liu, J.H., Sun, H.L., Zhuang, Z.Q., Chen, S.H., Yao, X.Q., Giunta, B., Shan, Y.C., Tan, J., Chen, X.W., Dong, Z.F., Zhou, H.D., Zhou, X.F., Song, W., Wang, Y.J., 2018. Blood-derived amyloid-beta protein induces Alzheimer's disease pathologies. *Mol. Psychiatry* 23, 1948–1956.
- Bui, B.V., Fortune, B., 2004. Ganglion cell contributions to the rat full-field electroretinogram. *J. Physiol.* 555, 153–173.
- Bulut, M., Kurtulus, F., Gozkaya, O., Erol, M.K., Cengiz, A., Akidan, M., Yaman, A., 2018. Evaluation of optical coherence tomography angiographic findings in Alzheimer's type dementia. *Br. J. Ophthalmol.* 102, 233–237.
- Bustos, F.J., Ampuero, E., Jury, N., Aguilar, R., Falahi, F., Toledo, J., Ahumada, J., Lata, J., Cubillos, P., Henriquez, B., Guerra, M.V., Stehberg, J., Neve, R.L., Inestrosa, N.C., Wyneken, U., Fuenzalida, M., Hartel, S., Sena-Estevés, M., Varela-Nallar, L., Rots, M.G., Montecino, M., van Zundert, B., 2017. Epigenetic editing of the Dlg4/PSD95 gene improves cognition in aged and Alzheimer's disease mice. *Brain* 140, 3252–3268.
- Camino, A., Guo, Y., You, Q., Wang, J., Huang, D., Bailey, S.T., Jia, Y., 2019. Detecting and measuring areas of choriocapillaris low perfusion in intermediate, non-neovascular age-related macular degeneration. *Neurophotonics* 6, 041108.
- Casson, R.J., Chidlow, G., Crowston, J.G., Williams, P.A., Wood, J.P.M., 2020. Retinal energy metabolism in health and glaucoma. *Prog. Retin. Eye Res.* 100881. <https://doi.org/10.1016/j.preteyeres.2020.100881>.
- Cenini, G., Rub, C., Bruderek, M., Voos, W., 2016. Amyloid beta-peptides interfere with mitochondrial preprotein import competence by a coaggregation process. *Mol. Biol. Cell* 27, 3257–3272.
- Cha, M.Y., Han, S.H., Son, S.M., Hong, H.S., Choi, Y.J., Byun, J., Mook-Jung, I., 2012. Mitochondria-specific accumulation of amyloid beta induces mitochondrial dysfunction leading to apoptotic cell death. *PLoS One* 7, e34929.
- Chan, V.T.T., Sun, Z., Tang, S., Chen, L.J., Wong, A., Tham, C.C., Wong, T.Y., Chen, C., Ikram, M.K., Whitson, H.E., Lad, E.M., Mok, V.C.T., Cheung, C.Y., 2019. Spectral-domain OCT measurements in Alzheimer's disease: a systematic review and meta-analysis. *Ophthalmology* 126, 497–510.
- Chang, L.Y., Lowe, J., Ardiles, A., Lim, J., Grey, A.C., Robertson, K., Danesh-Meyer, H., Palacios, A.G., Acosta, M.L., 2014. Alzheimer's disease in the human eye. Clinical tests that identify ocular and visual information processing deficit as biomarkers. *Alzheimers Dement* 10, 251–261.
- Chang, L.Y., Turuwenua, J., Qu, T.Y., Black, J.M., Acosta, M.L., 2017. Infrared video pupillography coupled with smart phone LED for measurement of pupillary light reflex. *Front. Integr. Neurosci.* 11, 6.
- Charidimou, A., Boulouis, G., Gurol, M.E., Ayata, C., Bacskaï, B.J., Frosch, M.P., Viswanathan, A., Greenberg, S.M., 2017. Emerging concepts in sporadic cerebral amyloid angiopathy. *Brain* 140, 1829–1850.
- Chen, G.F., Xu, T.H., Yan, Y., Zhou, Y.R., Jiang, Y., Melcher, K., Xu, H.E., 2017. Amyloid beta: structure, biology and structure-based therapeutic development. *Acta Pharmacol. Sin.* 38, 1205–1235.
- Cheng, D., Logge, W., Low, J.K., Garner, B., Karl, T., 2013. Novel behavioural characteristics of the APP(Swe)/PS1DeltaE9 transgenic mouse model of Alzheimer's disease. *Behav. Brain Res.* 245, 120–127.
- Cheung, C.Y., Ong, Y.T., Ikram, M.K., Ong, S.Y., Li, X., Hilal, S., Catindig, J.A., Venkatasubramanian, N., Yap, P., Seow, D., Chen, C.P., Wong, T.Y., 2014. Microvascular network alterations in the retina of patients with Alzheimer's disease. *Alzheimers Dement* 10, 135–142.
- Cheung, C.Y., Ong, Y.T., Hilal, S., Ikram, M.K., Low, S., Ong, Y.L., Venkatasubramanian, N., Yap, P., Seow, D., Chen, C.L., Wong, T.Y., 2015. Retinal ganglion cell analysis using high-definition optical coherence tomography in patients with mild cognitive impairment and Alzheimer's disease. *J. Alzheimers Dis.* 45, 45–56.
- Cheung, C.Y., Ikram, M.K., Chen, C., Wong, T.Y., 2017. Imaging retina to study dementia and stroke. *Prog. Retin. Eye Res.* 57, 89–107. <https://doi.org/10.1016/j.preteyeres.2017.01.001>.
- Chiasseu, M., Alarcon-Martinez, L., Belforte, N., Quintero, H., Dotigny, F., Destroisaisons, L., Vande Velde, C., Panayi, F., Louis, C., Di Polo, A., 2017. Tau accumulation in the retina promotes early neuronal dysfunction and precedes brain pathology in a mouse model of Alzheimer's disease. *Mol. Neurodegener.* 12, 58.
- Chitranshi, N., Dheer, Y., Gupta, V., Abbasi, M., Mirzaei, M., You, Y., Chung, R., Graham, S.L., Gupta, V., 2017. PTPN11 induces endoplasmic stress and apoptosis in SH-SY5Y cells. *Neuroscience* 364, 175–189.
- Chitranshi, N., Dheer, Y., Abbasi, M., You, Y., Graham, S.L., Gupta, V., 2018. Glaucoma pathogenesis and neurotrophins: focus on the molecular and genetic basis for therapeutic prospects. *Curr. Neuropharmacol.* 16, 1018–1035.
- Chitranshi, N., Dheer, Y., Kumar, S., Graham, S.L., Gupta, V., 2019. Molecular docking, dynamics, and pharmacology studies on bexarotene as an agonist of ligand-activated transcription factors, retinoid X receptors. *J. Cell. Biochem.* <https://doi.org/10.1002/jcb.28455>.

- Chitranshi, N., Dheer, Y., Mirzaei, M., Wu, Y., Salekdeh, G.H., Abbasi, M., Gupta, V., Vander Wall, R., You, Y., Graham, S.L., Gupta, V., 2019b. Loss of Shp2 rescues BDNF/TrkB signaling and contributes to improved retinal ganglion cell neuroprotection. *Mol. Ther.* 27, 424–441.
- Chiu, K., Chan, T.F., Wu, A., Leung, I.Y., So, K.F., Chang, R.C., 2012. Neurodegeneration of the retina in mouse models of Alzheimer's disease: what can we learn from the retina? *Age (Dordr)* 34, 633–649.
- Chu, J., Lauretti, E., Pratico, D., 2017. Caspase-3-dependent cleavage of Akt modulates tau phosphorylation via GSK3beta kinase: implications for Alzheimer's disease. *Mol. Psychiatr.* 22, 1002–1008.
- Cogan, D.G., 1985. Visual disturbances with focal progressive dementing disease. *Am. J. Ophthalmol.* 100, 68–72.
- Collaborators, G.B.D.D., 2019. Global, regional, and national burden of Alzheimer's disease and other dementias, 1990–2016: a systematic analysis for the Global Burden of Disease Study 2016. *Lancet Neurol.* 18, 88–106.
- Cordeiro, M.F., Guo, L., Luong, V., Harding, G., Wang, W., Jones, H.E., Moss, S.E., Sillito, A.M., Fitzke, F.W., 2004. Real-time imaging of single nerve cell apoptosis in retinal neurodegeneration. *Proc. Natl. Acad. Sci. U. S. A.* 101, 13352–13356.
- Cordeiro, M., Guo, L., Coxon, K.M., Duggan, J., Nizari, S., Normando, E.M., Sensi, S.L., Sillito, A.M., Fitzke, F.W., Salt, T.E., Moss, S.E., 2010. Imaging multiple phases of neurodegeneration: a novel approach to assessing cell death in vivo. *Cell Death Dis.* 1.
- Cordeiro, M.F., Normando, E.M., Cardoso, M.J., Miodragovic, S., Jeylani, S., Davis, B.M., Guo, L., Ourselin, S., A'Hern, R., Bloom, P.A., 2017. Real-time imaging of single neuronal cell apoptosis in patients with glaucoma. *Brain* 140, 1757–1767.
- Corrada, M.M., Brookmeyer, R., Paganini-Hill, A., Berlau, D., Kawas, C.H., 2010. Dementia incidence continues to increase with age in the oldest old: the 90+ study. *Ann. Neurol.* 67, 114–121.
- Cox, K.H., Pipingas, A., Scholey, A.B., 2015. Investigation of the effects of solid lipid curcumin on cognition and mood in a healthy older population. *J. Psychopharmacol.* 29, 642–651.
- Crawford, T.J., Devereaux, A., Higham, S., Kelly, C., 2015. The disengagement of visual attention in Alzheimer's disease: a longitudinal eye-tracking study. *Front. Aging Neurosci.* 7, 118.
- Cronin-Golomb, A., Dementias, O., 2011. Visuospatial Function in Alzheimer's Disease and Related Disorders, p. 457.
- Crutch, S.J., Schott, J.M., Rabinovici, G.D., Murray, M., Snowden, J.S., van der Flier, W. M., Dickerson, B.C., Vandenberghe, R., Ahmed, S., Bak, T.H., Boeve, B.F., Butler, C., Cappa, S.F., Ceccaldi, M., de Souza, L.C., Dubois, B., Felician, O., Galasko, D., Graff-Radford, J., Graff-Radford, N.R., Hof, P.R., Krolak-Salmon, P., Lehmann, M., Magnin, E., Mendez, M.F., Nestor, P.J., Onyike, C.U., Pelak, V.S., Pijnenburg, Y., Primativo, S., Rossor, M.N., Ryan, N.S., Scheltens, P., Shakespeare, T.J., Suarez Gonzalez, A., Tang-Wai, D.F., Yong, K.X.X., Carrillo, M., Fox, N.C., Alzheimer's Association, I.A.A.S.D., Associated Syndromes Professional Interest, A., 2017. Consensus classification of posterior cortical atrophy. *Alzheimers Dement* 13, 870–884.
- Cummings, J., 2012. Alzheimer's disease diagnostic criteria: practical applications. *Alzheimer's Res. Ther.* 4, 35.
- Cunha, J.P., Moura-Coelho, N., Proenca, R.P., Dias-Santos, A., Ferreira, J., Louro, C., Castanheira-Dinis, A., 2016a. Alzheimer's disease: a review of its visual system neuropathology. Optical coherence tomography-a potential role as a study tool in vivo. *Graefes Arch. Clin. Exp. Ophthalmol.* 254, 2079–2092.
- Cunha, J.P., Lopes, L.C., Costa-Cunha, L.V., Costa, C.F., Pires, L.A., Almeida, A.L., Monteiro, M.L., 2016b. Macular thickness measurements with frequency domain-OCT for quantification of retinal neural loss and its correlation with cognitive impairment in Alzheimer's disease. *PLoS One* 11, e0153830.
- Cunha, J.P., Proenca, R., Dias-Santos, A., Almeida, R., Aguas, H., Alves, M., Papoila, A.L., Louro, C., Castanheira-Dinis, A., 2017a. OCT in Alzheimer's disease: thinning of the RNFL and superior hemiretina. *Graefes Arch. Clin. Exp. Ophthalmol.* 255, 1827–1835.
- Cunha, J.P., Proenca, R., Dias-Santos, A., Melancia, D., Almeida, R., Aguas, H., Santos, B. O., Alves, M., Ferreira, J., Papoila, A.L., Louro, C., Castanheira-Dinis, A., 2017b. Choroidal thinning: Alzheimer's disease and aging. *Alzheimers Dement (Amst)* 8, 11–17.
- Curcio, C.A., 2018. Soft drusen in age-related macular degeneration: biology and targeting via the oil spill strategies. *Invest. Ophthalmol. Vis. Sci.* 59, AMD160–AMD181.
- Danesh-Meyer, H.V., Birch, H., Ku, J.Y., Carroll, S., Gamble, G., 2006. Reduction of optic nerve fibers in patients with Alzheimer disease identified by laser imaging. *Neurology* 67, 1852–1854.
- de Jong, F.J., Schrijvers, E.M., Ikram, M.K., Koudstaal, P.J., de Jong, P.T., Hofman, A., Vingerling, J.R., Breteler, M.M., 2011. Retinal vascular caliber and risk of dementia: the Rotterdam study. *Neurology* 76, 816–821.
- Deane, R., Bell, R.D., Sagare, A., Zlokovic, B.V., 2009. Clearance of amyloid-beta peptide across the blood-brain barrier: implication for therapies in Alzheimer's disease. *CNS Neurol. Disord. - Drug Targets* 8, 16–30.
- Dejanovic, B., Huntley, M.A., De Maziere, A., Meilandt, W.J., Wu, T., Srinivasan, K., Jiang, Z., Gandham, V., Friedman, B.A., Ngu, H., Foreman, O., Carano, R.A.D., Chih, B., Klumperman, J., Bakalarski, C., Hanson, J.E., Sheng, M., 2018. Changes in the synaptic proteome in tauopathy and rescue of tau-induced synapse loss by Clq antibodies. *Neuron* 100, 1322–1336 e1327.
- den Haan, J., Verbraak, F.D., Visser, P.J., Bouwman, F.H., 2017. Retinal thickness in Alzheimer's disease: a systematic review and meta-analysis. *Alzheimers Dement (Amst)* 6, 162–170.
- den Haan, J., Janssen, S.F., van de Kreeke, J.A., Scheltens, P., Verbraak, F.D., Bouwman, F.H., 2018a. Retinal thickness correlates with parietal cortical atrophy in early-onset Alzheimer's disease and controls. *Alzheimers Dement (Amst)* 10, 49–55.
- den Haan, J., Morrema, T.H.J., Rozemuller, A.J., Bouwman, F.H., Hoozemans, J.J.M., 2018b. Different curcumin forms selectively bind fibrillar amyloid beta in post mortem Alzheimer's disease brains: implications for in-vivo diagnostics. *Acta Neuropathol. Commun.* 6, 75.
- den Haan, J., Morrema, T.H.J., Verbraak, F.D., de Boer, J.F., Scheltens, P., Rozemuller, A. J., Bergen, A.A.B., Bouwman, F.H., Hoozemans, J.J., 2018c. Amyloid-beta and phosphorylated tau in post-mortem Alzheimer's disease retinas. *Acta Neuropathol. Commun.* 6, 147.
- den Haan, J., Csinscik, L., Parker, T., Paterson, R.W., Slattery, C.F., Foulkes, A., Bouwman, F.H., Verbraak, F.D., Scheltens, P., Peto, T., Lengyel, I., Schott, J.M., Crutch, S.J., Shakespeare, T.J., Yong, K.X.X., 2019. Retinal thickness as potential biomarker in posterior cortical atrophy and typical Alzheimer's disease. *Alzheimer's Res. Ther.* 11, 62.
- Deng, L., Pushpitha, K., Joseph, C., Gupta, V., Rajput, R., Chitranshi, N., Dheer, Y., Amirkhani, A., Kamath, K., Pascovici, D., Wu, J.X., Salekdeh, G.H., Haynes, P.A., Graham, S.L., Gupta, V.K., Mirzaei, M., 2019. Amyloid beta induces early changes in the ribosomal machinery, cytoskeletal organization and oxidative phosphorylation in retinal photoreceptor cells. *Front. Mol. Neurosci.* 12, 24.
- Dheer, Y., Chitranshi, N., Gupta, V., Abbasi, M., Mirzaei, M., You, Y., Chung, R., Graham, S.L., Gupta, V., 2018. Bexarotene modulates retinoid-X-receptor expression and is protective against neurotoxic endoplasmic reticulum stress response and apoptotic pathway activation. *Mol. Neurobiol.* 55, 9043–9056.
- Dheer, Y., Chitranshi, N., Gupta, V., Sharma, S., Pushpitha, K., Abbasi, M., Mirzaei, M., You, Y., Graham, S.L., Gupta, V., 2019. Retinoid x receptor modulation protects against ER stress response and rescues glaucoma phenotypes in adult mice. *Exp. Neurol.* 314, 111–125.
- Ding, J.D., Johnson, L.V., Herrmann, R., Farsiu, S., Smith, S.G., Groelle, M., Mace, B.E., Sullivan, P., Jamison, J.A., Kelly, U., Harrabi, O., Bollini, S.S., Dilley, J., Kobayashi, D., Kuang, B., Li, W., Pons, J., Lin, J.C., Bowes Rickman, C., 2011. Anti-amyloid therapy protects against retinal pigmented epithelium damage and vision loss in a model of age-related macular degeneration. *Proc. Natl. Acad. Sci. U. S. A.* 108, E279–E287.
- Dong, Z.Z., Li, J., Gan, Y.F., Sun, X.R., Leng, Y.X., Ge, J., 2018. Amyloid beta deposition related retinal pigment epithelium cell impairment and subretinal microglia activation in aged APPswePS1 transgenic mice. *Int. J. Ophthalmol.* 11, 747–755.
- Doustar, J., Torbati, T., Black, K.L., Koronyo, Y., Koronyo-Hamaoui, M., 2017. Optical coherence tomography in Alzheimer's disease and other neurodegenerative diseases. *Front. Neurol.* 8, 701.
- Du, L.Y., Chang, L.Y., Ardiles, A.O., Tapia-Rojas, C., Araya, J., Inestrosa, N.C., Palacios, A.G., Acosta, M.L., 2015. Alzheimer's disease-related protein expression in the retina of Octodon degus. *PLoS One* 10, e0135499.
- Dubois, B., Feldman, H.H., Jacova, C., Dekosky, S.T., Barberger-Gateau, P., Cummings, J., Delacourte, A., Galasko, D., Gauthier, S., Jicha, G., Meguro, K., O'Brien, J., Pasquier, F., Robert, P., Rossor, M., Salloway, S., Stern, Y., Visser, P.J., Scheltens, P., 2007. Research criteria for the diagnosis of Alzheimer's disease: revising the NINCDS-ADRDA criteria. *Lancet Neurol.* 6, 734–746.
- Dutescu, R.M., Li, Q.X., Crowston, J., Masters, C.L., Baird, P.N., Culvenor, J.G., 2009. Amyloid precursor protein processing and retinal pathology in mouse models of Alzheimer's disease. *Graefes Arch. Clin. Exp. Ophthalmol.* 247, 1213–1221.
- Ecroyd, H., Carver, J.A., 2009. Crystallin proteins and amyloid fibrils. *Cell. Mol. Life Sci.* 66, 62–81.
- Egan, M.F., Kost, J., Voss, T., Mukai, Y., Aisen, P.S., Cummings, J.L., Tariot, P.N., Vellas, B., van Dyck, C.H., Boada, M., Zhang, Y., Li, W., Furtek, C., Mahoney, E., Harper Mozley, L., Mo, Y., Sur, C., Michelson, D., 2019. Randomized trial of verubecestat for prodromal Alzheimer's disease. *N. Engl. J. Med.* 380, 1408–1420.
- Eimer, W.A., Vassar, R., 2013. Neuron loss in the 5XFAD mouse model of Alzheimer's disease correlates with intraneuronal Abeta42 accumulation and Caspase-3 activation. *Mol. Neurodegener.* 8, 2.
- Embury, C.M., Dyavarshetty, B., Lu, Y., Wiedner, J.L., Ciborowski, P., Gendelman, H.E., Kiyota, T., 2017. Cathepsin B improves ss-amyloidosis and learning and memory in models of Alzheimer's disease. *J. Neuroimmune Pharmacol.* 12, 340–352.
- Erskine, L., Herrera, E., 2014. Connecting the retina to the brain. *ASN Neuro.* 6.
- Feke, G.T., Hyman, B.T., Stern, R.A., Pasquale, L.R., 2015. Retinal blood flow in mild cognitive impairment and Alzheimer's disease. *Alzheimers Dement (Amst)* 1, 144–151.
- Ferrari, L., Huang, S.C., Magnani, G., Ambrosi, A., Comi, G., Leocani, L., 2017. Optical coherence tomography reveals retinal neuroaxonal thinning in frontotemporal dementia as in Alzheimer's disease. *J. Alzheimers Dis.* 56, 1101–1107.
- Fonseca, M.I., Chu, S.H., Berci, A.M., Benoit, M.E., Peters, D.G., Kimura, Y., Tenner, A.J., 2011. Contribution of complement activation pathways to neuropathology differs among mouse models of Alzheimer's disease. *J. Neuroinflammation* 8, 4.
- Fotiou, D.F., Brozou, C.G., Haidich, A.B., Tsipstios, D., Nakou, M., Kabitsi, A., Giantselidis, C., Fotiou, F., 2007. Pupil reaction to light in Alzheimer's disease: evaluation of pupil size changes and mobility. *Aging Clin. Exp. Res.* 19, 364–371.
- Frishman, L.J., Shen, F.F., Du, L., Robson, J.G., Harwerth, R.S., Smith 3rd, E.L., Carter-Dawson, L., Crawford, M.L., 1996. The scotopic electroretinogram of macaque after retinal ganglion cell loss from experimental glaucoma. *Invest. Ophthalmol. Vis. Sci.* 37, 125–141.
- Frisoni, G.B., Boccardi, M., Barkhof, F., Blennow, K., Cappa, S., Chiotis, K., Demonet, J. F., Garibotto, V., Giannakopoulos, P., Gietl, A., Hansson, O., Herholz, K., Jack Jr., C. R., Nobili, F., Nordberg, A., Snyder, H.M., Ten Kate, M., Varrone, A., Albanese, E., Becker, S., Bossuyt, P., Carrillo, M.C., Cerami, C., Dubois, B., Gallo, V., Giacobini, E., Gold, G., Hurst, S., Lonnberg, A., Lovblad, K.O., Mattsson, N., Molinuevo, J.L.,

- Monsch, A.U., Mosimann, U., Padovani, A., Picco, A., Porter, C., Ratib, O., Saint-Aubert, L., Scerri, C., Scheltens, P., Schott, J.M., Sonni, I., Teipel, S., Vineis, P., Visser, P.J., Yasui, Y., Winblad, B., 2017. Strategic roadmap for an early diagnosis of Alzheimer's disease based on biomarkers. *Lancet Neurol.* 16, 661–676.
- Gadhve, K., Bolshette, N., Ahire, A., Pardeshi, R., Thakur, K., Trandafir, C., Istrate, A., Ahmed, S., Lahkar, M., Muresanu, D.F., Balea, M., 2016. The ubiquitin proteasomal system: a potential target for the management of Alzheimer's disease. *J. Cell Mol. Med.* 20, 1392–1407.
- Gangoda, S.V.S., Avadhanam, B., Jufri, N.F., Sohn, E.H., Butlin, M., Gupta, V., Chung, R., Angler, S., Hamilton, A., Holscher, C., 2010. Synaptic plasticity in the hippocampus of an APP/PS1 mouse model of Alzheimer's disease is impaired in old but not young mice. *PLoS One* 5, e9764.
- Gibbons, G.S., Lee, V.M.Y., Trojanowski, J.Q., 2019. Mechanisms of cell-to-cell transmission of pathological tau: a review. *JAMA Neurol.* 76, 101–108.
- Goldstein, L.E., Muffat, J.A., Cherny, R.A., Moir, R.D., Ericsson, M.H., Huang, X., Mavros, C., Coccia, J.A., Faget, K.Y., Fitch, K.A., Masters, C.L., Tanzi, R.E., Chylack Jr., L.T., Bush, A.I., 2003. Cytosolic beta-amyloid deposition and supranuclear cataracts in lenses from people with Alzheimer's disease. *Lancet* 361, 1258–1265.
- Golzan, S.M., Goozee, K., Georgevsky, D., Avolio, A., Chatterjee, P., Shen, K., Gupta, V., Chung, R., Savage, G., Orr, C.F., Martins, R.N., Graham, S.L., 2017. Retinal vascular and structural changes are associated with amyloid burden in the elderly: ophthalmic biomarkers of preclinical Alzheimer's disease. *Alzheimer's Res. Ther.* 9, 13.
- Gordon, B.A., Friedrichsen, K., Brier, M., Blazey, T., Su, Y., Christensen, J., Aldea, P., McConathy, J., Holtzman, D.M., Cairns, N.J., Morris, J.C., Fagan, A.M., Ances, B.M., Benzinger, T.L., 2016. The relationship between cerebrospinal fluid markers of Alzheimer pathology and positron emission tomography tau imaging. *Brain* 139, 2249–2260.
- Griebel, G., Stemmelin, J., Lopez-Grancha, M., Boulay, D., Boquet, G., Slowinski, F., Pichat, P., Beeske, S., Tanaka, S., Mori, A., Fujimura, M., Eguchi, J., 2019. The selective GSK3 inhibitor, SAR502250, displays neuroprotective activity and attenuates behavioral impairments in models of neuropsychiatric symptoms of Alzheimer's disease in rodents. *Sci. Rep.* 9, 18045.
- Grimaldi, A., Brighi, C., Peruzzi, G., Ragozzino, D., Bonanni, V., Limatola, C., Ruocco, G., Di Angelantonio, S., 2018. Inflammation, neurodegeneration and protein aggregation in the retina as ocular biomarkers for Alzheimer's disease in the 3xTg-AD mouse model. *Cell Death Dis.* 9, 685.
- Grimaldi, A., Pediconi, N., Oieni, F., Pizzarelli, R., Rosito, M., Giubettini, M., Santini, T., Limatola, C., Ruocco, G., Ragozzino, D., Di Angelantonio, S., 2019. Neuroinflammatory processes, A1 astrocyte activation and protein aggregation in the retina of Alzheimer's disease patients, possible biomarkers for early diagnosis. *Front. Neurosci.* 13, 925.
- Guo, W., Qian, L., Zhang, J., Zhang, W., Morrison, A., Hayes, P., Wilson, S., Chen, T., Zhao, J., 2011. Sirt1 overexpression in neurons promotes neurite outgrowth and cell survival through inhibition of the mTOR signaling. *J. Neurosci. Res.* 89, 1723–1736.
- Gupta, V.B., Anitha, S., Hegde, M.L., Zecca, L., Garruto, R.M., Ravid, R., Shankar, S.K., Stein, R., Shanmugavelu, P., Jagannatha Rao, K.S., 2005. Aluminium in Alzheimer's disease: are we still at a crossroad? *Cell. Mol. Life Sci.* 62, 143–158.
- Gupta, N., Fong, J., Ang, L.C., Yucl, Y.H., 2008. Retinal tau pathology in human glaucomas. *Can. J. Ophthalmol.* 43, 53–60.
- Gupta, V.B., Laws, S.M., Villemagne, V.L., Ames, D., Bush, A.I., Ellis, K.A., Lui, J.K., Masters, C., Rowe, C.C., Szecke, C., Taddei, K., Martins, R.N., Group, A.R., 2011. Plasma apolipoprotein E and Alzheimer disease risk: the AIBL study of aging. *Neurology* 76, 1091–1098.
- Gupta, V.K., You, Y., Klistorner, A., Graham, S.L., 2012. Shp-2 regulates the TrkB receptor activity in the retinal ganglion cells under glaucomatous stress. *Biochim. Biophys. Acta* 1822, 1643–1649.
- Gupta, V.B., Gupta, V.K., Martins, R., 2013. Semagacestat for treatment of Alzheimer's disease. *N. Engl. J. Med.* 369, 1660–1661.
- Gupta, V., Chitranshi, N., You, Y., Gupta, V., Klistorner, A., Graham, S., 2014a. Brain derived neurotrophic factor is involved in the regulation of glycogen synthase kinase 3beta (GSK3beta) signalling. *Biochem. Biophys. Res. Commun.* 454, 381–386.
- Gupta, V., You, Y., Li, J., Gupta, V., Golzan, M., Klistorner, A., van den Buuse, M., Graham, S., 2014b. BDNF impairment is associated with age-related changes in the inner retina and exacerbates experimental glaucoma. *Biochim. Biophys. Acta* 1842, 1567–1578.
- Gupta, V., Gupta, V.B., Chitranshi, N., Gangoda, S., Vander Wall, R., Abbasi, M., Golzan, M., Dheer, Y., Shah, T., Avolio, A., Chung, R., Martins, R., Graham, S., 2016a. One protein, multiple pathologies: multifaceted involvement of amyloid beta in neurodegenerative disorders of the brain and retina. *Cell. Mol. Life Sci.* 73, 4279–4297.
- Gupta, V.K., Chitranshi, N., Gupta, V.B., Golzan, M., Dheer, Y., Wall, R.V., Georgevsky, D., King, A.E., Vickers, J.C., Chung, R., Graham, S., 2016b. Amyloid beta accumulation and inner retinal degenerative changes in Alzheimer's disease transgenic mouse. *Neurosci. Lett.* 623, 52–56.
- Gupta, V., Mirzaei, M., Gupta, V.B., Chitranshi, N., Dheer, Y., Vander Wall, R., Abbasi, M., You, Y., Chung, R., Graham, S., 2017. Glaucoma is associated with plasmin proteolytic activation mediated through oxidative inactivation of neuroserpin. *Sci. Rep.* 7, 8412.
- Haan, J.D., van de Kreeke, J.A., Konijnenberg, E., Kate, M.T., Braber, A.D., Barkhof, F., van Berckel, B.N., Teunissen, C.E., Scheltens, P., Visser, P.J., Verbraak, F.D., Bouwman, F.H., 2019a. Retinal thickness as a potential biomarker in patients with amyloid-proven early- and late-onset Alzheimer's disease. *Alzheimers Dement (Amst)* 11, 463–471.
- Haan, J.D., van de Kreeke, J.A., van Berckel, B.N., Barkhof, F., Teunissen, C.E., Scheltens, P., Verbraak, F.D., Bouwman, F.H., 2019b. Is retinal vasculature a biomarker in amyloid proven Alzheimer's disease? *Alzheimers Dement (Amst)* 11, 383–391.
- Habiba, U., 2020. Age-specific retinal and cerebral immunodetection of beta amyloid plaques and oligomers in a rodent model of Alzheimer's disease. *J. Alzheim. Dis.* 10, 3233/JAD-191346.
- Hadoux, X., Hui, F., Lim, J.K.H., Masters, C.L., Peabay, A., Chevalier, S., Ha, J., Loi, S., Fowler, C.J., Rowe, C., Villemagne, V.L., Taylor, E.N., Fluke, C., Soucy, J.P., Lesage, F., Sylvestre, J.P., Rosa-Neto, P., Mathoaraarachchi, S., Gauthier, S., Nasreddine, Z.S., Arbour, J.D., Rheume, M.A., Beaulieu, S., Dirani, M., Nguyen, C.T. O., Bui, B.V., Williamson, R., Crowston, J.G., van Wijngaarden, P., 2019. Non-invasive in vivo hyperspectral imaging of the retina for potential biomarker use in Alzheimer's disease. *Nat. Commun.* 10, 4227.
- Hajjar, I., Goldstein, F.C., Martin, G.S., Quyyumi, A.A., 2016. Roles of arterial stiffness and blood pressure in hypertension-associated cognitive decline in healthy adults. *Hypertension* 67, 171–175.
- Hanger, D.P., Byers, H.L., Wray, S., Leung, K.Y., Saxton, M.J., Seereeram, A., Reynolds, C.H., Ward, M.A., Anderton, B.H., 2007. Novel phosphorylation sites in tau from Alzheimer brain support a role for casein kinase 1 in disease pathogenesis. *J. Biol. Chem.* 282, 23645–23654.
- Hanseeuw, B.J., Betensky, R.A., Jacobs, H.L., Schultz, A.P., Sepulcre, J., Becker, J.A., Cosio, D.M.O., Farrell, M., Quiroz, Y.T., Mormino, E.C., Buckley, R.F., Papp, K.V., Amariglio, R.A., Dewachter, I., Ivanou, A., Huijbers, W., Hedden, T., Marshall, G.A., Chhatwal, J.P., Rentz, D.M., Sperling, R.A., Johnson, K., 2019. Association of amyloid and tau with cognition in preclinical Alzheimer disease: a longitudinal study. *JAMA Neurol.* 76 (8), 915–924. <https://doi.org/10.1001/jamaneuro.2019.1424>.
- Haque, M.E., Kim, I.S., Jakaria, M., Akther, M., Choi, D.K., 2018. Importance of GPCR-mediated microglial activation in Alzheimer's disease. *Front. Cell. Neurosci.* 12, 258.
- Heneka, M.T., Carson, M.J., El Khoury, J., Landreth, G.E., Brosseron, F., Feinstein, D.L., Jacobs, A.H., Wyss-Coray, T., Vitorica, J., Ransohoff, R.M., Herrup, K., Frautschy, S. A., Finsen, B., Brown, G.C., Verkhratsky, A., Yamanaka, K., Koistinaho, J., Latz, E., Halle, A., Petzold, G.C., Town, T., Morgan, D., Shinohara, M.L., Perry, V.H., Holmes, C., Bazan, N.G., Brooks, D.J., Hunot, S., Joseph, B., Deigendesch, N., Garaschuk, O., Boddeke, E., Dinarello, C.A., Breitner, J.C., Cole, G.M., Golenbock, D. T., Kummer, M.P., 2015. Neuroinflammation in Alzheimer's disease. *Lancet Neurol.* 14, 388–405.
- Hinton, D.R., Sadun, A.A., Blanks, J.C., Miller, C.A., 1986. Optic-nerve degeneration in Alzheimer's disease. *N. Engl. J. Med.* 315, 485–487.
- Ho, C.Y., Troncoso, J.C., Knox, D., Stark, W., Eberhart, C.G., 2014. Beta-amyloid, phospho-tau and alpha-synuclein deposits similar to those in the brain are not identified in the eyes of Alzheimer's and Parkinson's disease patients. *Brain Pathol.* 24, 25–32.
- Hoh Kam, J., Lenassi, E., Jeffery, G., 2010. Viewing ageing eyes: diverse sites of amyloid Beta accumulation in the ageing mouse retina and the up-regulation of macrophages. *PLoS One* 5.
- Hong, Y.K., Chen, C., 2011. Wiring and rewiring of the retinogeniculate synapse. *Curr. Opin. Neurobiol.* 21, 228–237.
- Honig, L.S., Vellas, B., Woodward, M., Boada, M., Bullock, R., Borrie, M., Hager, K., Andreason, N., Scarpini, E., Liu-Seifert, H., Case, M., Dean, R.A., Hake, A., Sundell, K., Poole Hoffmann, V., Carlson, C., Khanna, R., Mintun, M., DeMattos, R., Selzler, K.J., Siemers, E., 2018. Trial of solanezumab for mild dementia due to Alzheimer's disease. *N. Engl. J. Med.* 378, 321–330.
- Ida, H., Ishibashi, K., Reiser, K., Hjelmeland, L.M., Handa, J.T., 2004. Ultrastructural aging of the RPE-Bruch's membrane-choriocapillaris complex in the D-galactose-treated mouse. *Invest. Ophthalmol. Vis. Sci.* 45, 2348–2354.
- Iseri, P.K., Altinas, O., Tokay, T., Yuksel, N., 2006. Relationship between cognitive impairment and retinal morphological and visual functional abnormalities in Alzheimer disease. *J. Neuro Ophthalmol.* 26, 18–24.
- Ismail, Z., Smith, E.E., Geda, Y., Sultzer, D., Brodaty, H., Smith, G., Aguera-Ortiz, L., Sweet, R., Miller, D., Lyketsos, C.G., Area, I.N.S.P.I., 2016. Neuropsychiatric symptoms as early manifestations of emergent dementia: provisional diagnostic criteria for mild behavioral impairment. *Alzheimers Dement* 12, 195–202.
- Itagaki, S., McGeer, P.L., Akiyama, H., Zhu, S., Selkoe, D., 1989. Relationship of microglia and astrocytes to amyloid deposits of Alzheimer disease. *J. Neuroimmunol.* 24, 173–182.
- Ittner, L.M., Gotz, J., 2011. Amyloid-beta and tau—a toxic pas de deux in Alzheimer's disease. *Nat. Rev. Neurosci.* 12, 65–72.
- Jack Jr., C.R., Albert, M.S., Knopman, D.S., McKhann, G.M., Sperling, R.A., Carrillo, M. C., Thies, B., Phelps, C.H., 2011. Introduction to the recommendations from the National Institute on Aging-Alzheimer's Association workgroups on diagnostic guidelines for Alzheimer's disease. *Alzheimers Dement* 7, 257–262.
- Jack Jr., C.R., Bennett, D.A., Blennow, K., Carrillo, M.C., Dunn, B., Haerlein, S.B., Holtzman, D.M., Jagust, W., Jessen, F., Karlawish, J., Liu, E., Molinuevo, J.L., Montine, T., Phelps, C., Rankin, K.P., Rowe, C.C., Scheltens, P., Siemers, E., Snyder, H.M., Sperling, R., Contributors, 2018. NIA-AA Research Framework:



- toward a biological definition of Alzheimer's disease. *Alzheimers Dement* 14, 535–562.
- Janelidze, S., Mattsson, N., Palmqvist, S., Smith, R., Beach, T.G., Serrano, G.E., Chai, X., Proctor, N.K., Eichenlaub, U., Zetterberg, H., Blennow, K., Reiman, E.M., Stomrud, E., Dage, J.L., Hansson, O., 2020. Plasma P-tau181 in Alzheimer's disease: relationship to other biomarkers, differential diagnosis, neuropathology and longitudinal progression to Alzheimer's dementia. *Nat. Med.* 26, 379–386.
- Johnson, E.C.B., Dammer, E.B., Duong, D.M., Ping, L., Zhou, M., Yin, L., Higginbotham, L.A., Guajardo, A., White, B., Troncoso, J.C., Thambisetty, M., Montine, T.J., Lee, E.B., Trojanowski, J.Q., Beach, T.G., Reiman, E.M., Haroutunian, V., Wang, M., Schadt, E., Zhang, B., Dickson, D.W., Ertekin-Taner, N., Golde, T.E., Petyuk, V.A., De Jager, P.L., Bennett, D.A., Wingo, T.S., Rangaraju, S., Hajjar, I., Shulman, J.M., Lah, J.J., Levey, A.I., Seyfried, N.T., 2020. Large-scale proteomic analysis of Alzheimer's disease brain and cerebrospinal fluid reveals early changes in energy metabolism associated with microglia and astrocyte activation. *Nat. Med.* 26 (5), 769–780.
- Ju, Y.E., McLeland, J.S., Toedebusch, C.D., Xiong, C., Fagan, A.M., Duntley, S.P., Morris, J.C., Holtzman, D.M., 2013. Sleep quality and preclinical Alzheimer disease. *JAMA Neurol.* 70, 587–593.
- Jung, N.Y., Han, J.C., Ong, Y.T., Cheung, C.Y., Chen, C.P., Wong, T.Y., Kim, H.J., Kim, Y. J., Lee, J., Lee, J.S., Jang, Y.K., Kee, C., Lee, K.H., Kim, E.J., Seo, S.W., Na, D.L., 2019. Retinal microvasculature changes in amyloid-negative subcortical vascular cognitive impairment compared to amyloid-positive Alzheimer's disease. *J. Neurol. Sci.* 396, 94–101.
- Kanay, Y., Matsumoto, H., Song, H., Sokolov, M., Anderson, R.E., Rajala, R.V., 2010. Serine/threonine kinase akt activation regulates the activity of retinal serine/threonine phosphatases, PHLPP and PHLPL. *J. Neurochem.* 113, 477–488.
- Katz, B., Rimmer, S., Iragui, V., Katzman, R., 1989. Abnormal pattern electroretinogram in Alzheimer's disease: evidence for retinal ganglion cell degeneration? *Ann. Neurol.* 26, 221–225.
- Kayabasi, U., Sergott, R., Rispoli, M., 2014. Retinal examination for the diagnosis of Alzheimer's disease. *Int. J. Ophthalmic Pract.* 3.
- Kerbage, C., Sadowsky, C.H., Tariot, P.N., Agronin, M., Alva, G., Turner, F.D., Nilan, D., Cameron, A., Cagle, G.D., Hartung, P.D., 2015. Detection of amyloid beta signature in the lens and its correlation in the brain to aid in the diagnosis of Alzheimer's disease. *Am. J. Alzheimers Dis. Dement.* 30, 738–745.
- Kesler, A., Vakhapova, V., Korczyn, A.D., Naftaliev, E., Neudorfer, M., 2011. Retinal thickness in patients with mild cognitive impairment and Alzheimer's disease. *Clin. Neurol. Neurosurg.* 113, 523–526.
- Kim, K.Y., Perkins, G.A., Shim, M.S., Bushong, E., Alcasid, N., Ju, S., Ellisman, M.H., Weinreb, R.N., Ju, W.K., 2015. DRP1 inhibition rescues retinal ganglion cells and their axons by preserving mitochondrial integrity in a mouse model of glaucoma. *Cell Death Dis.* 6, e1839.
- Kinney, J.W., Bemiller, S.M., Murtishaw, A.S., Leisgang, A.M., Salazar, A.M., Lamb, B.T., 2018. Inflammation as a central mechanism in Alzheimer's disease. *Alzheimers Dement (N Y)* 4, 575–590.
- Kiper-Kauer, A., McKinnon, S.J., Frueh, B.E., Goldblum, D., 2010. Distribution of amyloid precursor protein and amyloid-beta in ocular hypertensive C57BL/6 mouse eyes. *Curr. Eye Res.* 35, 828–834.
- Klistorner, A., Graham, E.C., Yiannikas, C., Barnett, M., Parratt, J., Garrick, R., Wang, C., You, Y., Graham, S.L., 2017. Progression of retinal ganglion cell loss in multiple sclerosis is associated with new lesions in the optic radiations. *Eur. J. Neurol.* 24, 1392–1398.
- Knoll, B., Simonett, J., Volpe, N.J., Farsiou, S., Ward, M., Rademaker, A., Weintraub, S., Fawzi, A.A., 2016. Retinal nerve fiber layer thickness in amnesic mild cognitive impairment: case-control study and meta-analysis. *Alzheimers Dement (Amst)* 4, 85–93.
- Ko, F., Muthy, Z.A., Gallacher, J., Sudlow, C., Rees, G., Yang, Q., Keane, P.A., Petzold, A., Khaw, P.T., Reisman, C., Strouthidis, N.G., Foster, P.J., Patel, P.J., Eye, U.K.B., Vision, C., 2018. Association of retinal nerve fiber layer thinning with current and future cognitive decline: a study using optical coherence tomography. *JAMA Neurol.* 75, 1198–1205.
- Koronyo, Y., Salumbides, B.C., Black, K.L., Koronyo-Hamaoui, M., 2012. Alzheimer's disease in the retina: imaging retinal abeta plaques for early diagnosis and therapy assessment. *Neurodegener. Dis.* 10, 285–293.
- Koronyo, Y., Biggs, D., Barron, E., Boyer, D.S., Pearlman, J.A., Au, W.J., Kile, S.J., Blanco, A., Fuchs, D.T., Ashfaq, A., Frautschy, S., Cole, G.M., Miller, C.A., Hinton, D. R., Verdooner, S.R., Black, K.L., Koronyo-Hamaoui, M., 2017. Retinal amyloid pathology and proof-of-concept imaging trial in Alzheimer's disease. *JCI Insight* 2.
- Koronyo-Hamaoui, M., Koronyo, Y., Ljubimov, A.V., Miller, C.A., Ko, M.K., Black, K.L., Schwartz, M., Farkas, D.L., 2011. Identification of amyloid plaques in retinas from Alzheimer's patients and noninvasive in vivo optical imaging of retinal plaques in a mouse model. *Neuroimage* 54 (Suppl. 1), S204–217.
- Korth, M., Nguyen, N.X., Horn, F., Martus, P., 1994. Scotopic threshold response and scotopic PII in glaucoma. *Invest. Ophthalmol. Vis. Sci.* 35, 619–625.
- Krasodomska, K., Lubinski, W., Potemkowski, A., Honczarenko, K., 2010. Pattern electroretinogram (PERG) and pattern visual evoked potential (PVEP) in the early stages of Alzheimer's disease. *Doc. Ophthalmol. Vis. Sci.* 121, 111–121.
- Kwong, J.M.K., Hoang, C., Dukes, R.T., Yee, R.W., Gray, B.D., Pak, K.Y., Caprioli, J., 2014. Bis(Zinc-Dipicolylamine), Zn-DPA, a new marker for apoptosis. *Invest. Ophthalmol. Vis. Sci.* 55, 4913–4921.
- La Morgia, C., Ross-Cisneros, F.N., Koronyo, Y., Hannibal, J., Gallassi, R., Cantalupo, G., Sambati, L., Pan, B.X., Tozer, K.R., Barboni, P., Provini, F., Avanzini, P., Carbonelli, M., Pelosi, A., Chui, H., Liguori, R., Baruzzi, A., Koronyo-Hamaoui, M., Sadun, A.A., Carelli, V., 2016. Melanopsin retinal ganglion cell loss in Alzheimer disease. *Ann. Neurol.* 79, 90–109.
- Lacovich, V., Espindola, S.L., Alloati, M., Pozo Devoto, V., Cromberg, L.E., Carna, M.E., Forte, G., Gallo, J.M., Bruno, L., Stokin, G.B., Avale, M.E., Falzone, T.L., 2017. Tau isoforms imbalance impairs the axonal transport of the amyloid precursor protein in human neurons. *J. Neurosci.* 37, 58–69.
- Lathuiliere, A., Valdes, P., Papin, S., Cacquevel, M., Maclachlan, C., Knott, G.W., Muhs, A., Paganetti, P., Schneider, B.L., 2017. Motifs in the tau protein that control binding to microtubules and aggregation determine pathological effects. *Sci. Rep.* 7, 13556.
- Laurent, C., Buee, L., Blum, D., 2018. Tau and neuroinflammation: what impact for Alzheimer's disease and tauopathies? *Biomed. J.* 41, 21–33.
- Lee, C.Y.D., Daggett, A., Gu, X., Jiang, L.L., Langfelder, P., Li, X., Wang, N., Zhao, Y., Park, C.S., Cooper, Y., Ferando, I., Mody, I., Coppola, G., Xu, H., Yang, X.W., 2018. Elevated TREM2 gene dosage reprograms microglia reactivity and ameliorates pathological phenotypes in Alzheimer's disease models. *Neuron* 97, 1032–1048 e1035.
- Lee, C.S., Larson, E.B., Gibbons, L.E., Lee, A.Y., McCurry, S.M., Bowen, J.D., McCormick, W.C., Crane, P.K., 2019. Associations between recent and established ophthalmic conditions and risk of Alzheimer's disease. *Alzheimers Dement* 15, 34–41.
- Lesage, S.R., Mosley, T.H., Wong, T.Y., Szklo, M., Knopman, D., Catellier, D.J., Cole, S.R., Klein, R., Coresh, J., Coker, L.H., Sharrett, A.R., 2009. Retinal microvascular abnormalities and cognitive decline: the ARIC 14-year follow-up study. *Neurology* 73, 862–868.
- Levy, O., Lavalette, S., Hu, S.J., Housset, M., Raoul, W., Eandi, C., Sahel, J.A., Sullivan, P. M., Guilloneau, X., Sennlaub, F., 2015. APOE isoforms control pathogenic subretinal inflammation in age-related macular degeneration. *J. Neurosci.* 35, 13568–13576.
- Lim, J.K., Li, Q.X., He, Z., Vingrys, A.J., Wong, V.H., Currier, N., Mullen, J., Bui, B.V., Nguyen, C.T., 2016. The eye as a biomarker for Alzheimer's disease. *Front. Neurosci.* 10, 536.
- Litvinchuk, A., Wan, Y.W., Swartzlander, D.B., Chen, F., Cole, A., Propson, N.E., Wang, Q., Zhang, B., Liu, Z., Zheng, H., 2018. Complement C3aR inactivation attenuates tau pathology and reverses an immune network deregulated in tauopathy models and Alzheimer's disease. *Neuron* 100, 1337–1353 e1335.
- Liu, B., Rasool, S., Yang, Z., Glabe, C.G., Schreiber, S.S., Ge, J., Tan, Z., 2009. Amyloid-peptide vaccinations reduce (beta)-amyloid plaques but exacerbate vascular deposition and inflammation in the retina of Alzheimer's transgenic mice. *Am. J. Pathol.* 175, 2099–2110.
- Liu, C.C., Liu, C.C., Kanekiyo, T., Xu, H., Bu, G., 2013. Apolipoprotein E and Alzheimer disease: risk, mechanisms and therapy. *Nat. Rev. Neurol.* 9, 106–118.
- Liu, D., Zhang, L., Li, Z., Zhang, X., Wu, Y., Yang, H., Min, B., Zhang, X., Ma, D., Lu, Y., 2015. Thinner changes of the retinal nerve fiber layer in patients with mild cognitive impairment and Alzheimer's disease. *BMC Neurol.* 15, 14.
- Liu, Y.L., Hsieh, Y.T., Chen, T.F., Chiou, J.M., Tsai, M.K., Chen, J.H., Chen, Y.C., 2019. Retinal ganglion cell-inner plexiform layer thickness is nonlinearly associated with cognitive impairment in the community-dwelling elderly. *Alzheimers Dement (Amst)* 11, 19–27.
- London, A., Benhar, I., Schwartz, M., 2013. The retina as a window to the brain—from eye research to CNS disorders. *Nat. Rev. Neurol.* 9, 44–53.
- Lopez-de-Eguileta, A., Lage, C., Lopez-Garcia, S., Pozueta, A., Garcia-Martinez, M., Kazmierczak, M., Bravo, M., de Arcocha-Torres, M., Banzo, I., Jimenez-Bonilla, J., Cervero, A., Rodriguez-Rodriguez, E., Sanchez-Juan, P., Casado, A., 2019. Ganglion cell layer thinning in prodromal Alzheimer's disease defined by amyloid PET. *Alzheimers Dement (N Y)* 5, 570–578.
- Lu, J., 2019. PET Imaging, Imaging of CNS Infections and Neuroimmunology. Springer, pp. 11–13.
- Lu, Y., Li, Z., Zhang, X., Ming, B., Jia, J., Wang, R., Ma, D., 2010. Retinal nerve fiber layer structure abnormalities in early Alzheimer's disease: evidence in optical coherence tomography. *Neurosci. Lett.* 480, 69–72.
- Lv, J.N., Zhou, G.H., Chen, X., Chen, H., Wu, K.C., Xiang, L., Lei, X.L., Zhang, X., Wu, R. H., Jin, Z.B., 2017. Targeted RP9 ablation and mutagenesis in mouse photoreceptor cells by CRISPR-Cas9. *Sci. Rep.* 7, 43062.
- Marsden, I.T., Minamide, L.S., Bamberg, J.R., 2011. Amyloid-beta-induced amyloid-beta secretion: a possible feed-forward mechanism in Alzheimer's Disease. *J. Alzheimers Dis.* 24, 681–691.
- Martin, L., Latypova, X., Wilson, C.M., Magnaudeix, A., Perrin, M.L., Yardin, C., Terro, F., 2013. Tau protein kinases: involvement in Alzheimer's disease. *Ageing Res. Rev.* 12, 289–309.
- Mazzoni, F., Müller, C., DeAssis, J., Deborah Lew, W., Leevy, M., Finnemann, S.C., 2019. Non-invasive in vivo fluorescence imaging of apoptotic retinal photoreceptors. *Sci. Rep.* 9.
- McAleese, K.E., Alafuzoff, I., Charidimou, A., De Reuck, J., Grinberg, L.T., Hainsworth, A. H., Hortobagyi, T., Ince, P., Jellinger, K., Gao, J., Kalaria, R.N., Kovacs, G.G., Kovari, E., Love, S., Popovic, M., Skrobot, O., Taipa, R., Thal, D.R., Werring, D., Wharton, S.B., Attems, J., 2016. Post-mortem assessment in vascular dementia: advances and aspirations. *BMC Med.* 14, 129.
- McGrory, S., Cameron, J.R., Pellegrini, E., Warren, C., Doubal, F.N., Deary, I.J., Dhillion, B., Wardlaw, J.M., Trucco, E., MacGillivray, T.J., 2017. The application of retinal fundus camera imaging in dementia: a systematic review. *Alzheimers Dement (Amst)* 6, 91–107.
- McKhann, G.M., Knopman, D.S., Chertkow, H., Hyman, B.T., Jack Jr., C.R., Kawas, C.H., Klunk, W.E., Koroshetz, W.J., Manly, J.J., Mayeux, R., Mohs, R.C., Morris, J.C., Rossor, M.N., Scheltens, P., Carrillo, M.C., Thies, B., Weintraub, S., Phelps, C.H., 2011. The diagnosis of dementia due to Alzheimer's disease: recommendations from the National Institute on Aging-Alzheimer's Association workgroups on diagnostic guidelines for Alzheimer's disease. *Alzheimers Dement* 7, 263–269.

- Meli, G., Lecci, A., Manca, A., Krako, N., Albertini, V., Benussi, L., Ghidoni, R., Cattaneo, A., 2014. Conformational targeting of intracellular Aβ oligomers demonstrates their pathological oligomerization inside the endoplasmic reticulum. *Nat. Commun.* 5, 3867.
- Michaelson, D.M., 2014. APOE ε4: the most prevalent yet understudied risk factor for Alzheimer's disease. *Alzheimers Dement* 10, 861–868.
- Mirzaei, M., Gupta, V.B., Chick, J.M., Greco, T.M., Wu, Y., Chitranshi, N., Wall, R.V., Hone, E., Deng, L., Dheer, Y., Abbasi, M., Rezaeian, M., Braid, N., You, Y., Salekdeh, G.H., Haynes, P.A., Molloy, M.P., Martins, R., Cristea, I.M., Gygi, S.P., Graham, S.L., Gupta, V.K., 2017. Age-related neurodegenerative disease associated pathways identified in retinal and vitreous proteome from human glaucoma eyes. *Sci. Rep.* 7, 12685.
- Mirzaei, M., Pushpitha, K., Deng, L., Chitranshi, N., Gupta, V., Rajput, R., Mangani, A.B., Dheer, Y., Godinez, A., McKay, M.J., Kamath, K., Pascovici, D., Wu, J.X., Salekdeh, G.H., Karl, T., Haynes, P.A., Graham, S.L., Gupta, V.K., 2019. Upregulation of proteolytic pathways and altered protein biosynthesis underlie retinal pathology in a mouse model of Alzheimer's disease. *Mol. Neurobiol.* 56 (9), 6017–6034.
- Mirzaei, M., Gupta, V.K., Chitranshi, N., Deng, L., Pushpitha, K., Abbasi, M., Chick, J.M., Rajput, R., Wu, Y., McKay, M.J., Salekdeh, G.H., Gupta, V.B., Haynes, P.A., Graham, S.L., 2020. Retinal proteomics of experimental glaucoma model reveal intraocular pressure-induced mediators of neurodegenerative changes. *J. Cell. Biochem.* <https://doi.org/10.1002/jcb.29822>.
- Mirzaei, M., Pushpitha, K., Deng, L., Chitranshi, N., Gupta, V., Rajput, R., Mangani, A.B., Dheer, Y., Godinez, A., McKay, M.J., Kamath, K., Pascovici, D., Wu, J.X., Salekdeh, G.H., Karl, T., Haynes, P.A., Graham, S.L., Gupta, V.K., 2019b. Upregulation of proteolytic pathways and altered protein biosynthesis underlie retinal pathology in a mouse model of Alzheimer's disease. *Mol. Neurobiol.* 56, 6017–6034.
- Mirzaei, M., Deng, L., Gupta, V.B., Graham, S., Gupta, V., 2020a. Complement pathway in Alzheimer's pathology and retinal neurodegenerative disorders - the road ahead. *Neural. Regen. Res.* 15, 257–258.
- Mojtaba Golzan, S., Goozee, K., Dana, Georgevsky, Alberto, Avolio, Chatterjee, Prathishtha, Shen, Kaikai, Gupta, Vivek, Chung, Roger, Savage, Greg, Orr, Carolyn, Martins, Ralph N., Graham, Stuart, 2017. Retinal vascular and structural changes are associated with amyloid burden in the elderly: ophthalmic biomarkers of preclinical Alzheimer's disease. *Alz Res Ther.* <https://doi.org/10.1186/s13195-017-0239-9>.
- Moncaster, J.A., Pineda, R., Moir, R.D., Lu, S., Burton, M.A., Ghosh, J.G., Ericsson, M., Socia, S.J., Mocofanescu, A., Folkler, R.D., Robb, R.M., Kuzak, J.R., Clark, J.L., Tanzi, R.E., Hunter, D.G., Goldstein, L.E., 2010. Alzheimer's disease amyloid-beta links lens and brain pathology in Down syndrome. *PLoS One* 5, e10659.
- More, S.S., Vince, R., 2015. Hyperspectral imaging signatures detect amyloidopathy in Alzheimer's mouse retina well before onset of cognitive decline. *ACS Chem. Neurosci.* 6, 306–315.
- Moreira, P.I., Carvalho, C., Zhu, X., Smith, M.A., Perry, G., 2010. Mitochondrial dysfunction is a trigger of Alzheimer's disease pathophysiology. *Biochim. Biophys. Acta* 2–10, 1802.
- Moreno-Ramos, T., Benito-Leon, J., Villarejo, A., Bermejo-Pareja, F., 2013. Retinal nerve fiber layer thinning in dementia associated with Parkinson's disease, dementia with Lewy bodies, and Alzheimer's disease. *J. Alzheimers Dis.* 34, 659–664.
- Mutsuga, M., Chambers, J.K., Uchida, K., Tei, M., Makibuchi, T., Mizorogi, T., Takashima, A., Nakayama, H., 2012. Binding of curcumin to senile plaques and cerebral amyloid angiopathy in the aged brain of various animals and to neurofibrillary tangles in Alzheimer's brain. *J. Vet. Med. Sci.* 74, 51–57.
- Mysona, B.A., Zhao, J., Bollinger, K.E., 2017. Role of BDNF/TrkB pathway in the visual system: therapeutic implications for glaucoma. *Expert Rev. Ophthalmol.* 12, 69–81.
- Ng, D.S., Chiang, P.P., Tan, G., Cheung, C.G., Cheng, C.Y., Cheung, C.Y., Wong, T.Y., Lamoureux, E.L., Ikram, M.K., 2016. Retinal ganglion cell neuronal damage in diabetes and diabetic retinopathy. *Clin. Exp. Ophthalmol.* 44, 243–250.
- Nguyen, C.T.O., Hui, F., Charn, J., Velaedan, S., van Koeveden, A.K., Lim, J.K.H., He, Z., Wong, V.H.Y., Vingrys, A.J., Bui, B.V., Ivarsson, M., 2017. Retinal biomarkers provide "insight" into cortical pharmacology and disease. *Pharmacol. Ther.* 175, 151–177.
- Ning, A., Cui, J., To, E., Ashe, K.H., Matsubara, J., 2008. Amyloid-beta deposits lead to retinal degeneration in a mouse model of Alzheimer disease. *Invest. Ophthalmol. Vis. Sci.* 49, 5136–5143.
- Nuzzo, D., Inguiglia, L., Walters, J., Picone, P., Di Carlo, M., 2017. A shotgun proteomics approach reveals a new toxic role for Alzheimer's disease Aβ peptide: spliceosome impairment. *J. Proteome Res.* 16, 1526–1541.
- O'Bryhim, B.E., Apte, R.S., Kung, N., Coble, D., Van Stavern, G.P., 2018. Association of preclinical Alzheimer disease with optical coherence tomographic angiography findings. *JAMA Ophthalmol.* 136, 1242–1248.
- Ohno-Matsui, K., 2011. Parallel findings in age-related macular degeneration and Alzheimer's disease. *Prog. Retin. Eye Res.* 30, 217–238.
- Oktem, E.O., Derle, E., Kibaroglu, S., Oktem, C., Akkoyun, I., Can, U., 2015. The relationship between the degree of cognitive impairment and retinal nerve fiber layer thickness. *Neural. Sci.* 36, 1141–1146.
- Olafsdottir, O.B., Saevarsdottir, H.S., Hardarson, S.H., Hannesdottir, K.H., Traustadottir, V.D., Karlsson, R.A., Einarsdottir, A.B., Jonsdottir, K.D., Stefansson, E., Snaedal, J., 2018. Retinal oxygen metabolism in patients with mild cognitive impairment. *Alzheimers Dement (Amst)* 10, 340–345.
- Parisi, V., Restuccia, R., Fattapposta, F., Mina, C., Bucci, M.G., Pierelli, F., 2001. Morphological and functional retinal impairment in Alzheimer's disease patients. *Clin. Neurophysiol.* 112, 1860–1867.
- Patton, N., Aslam, T., Macgillivray, T., Pattie, A., Deary, I.J., Dhillo, B., 2005. Retinal vascular image analysis as a potential screening tool for cerebrovascular disease: a rationale based on homology between cerebral and retinal microvasculatures. *J. Anat.* 206, 319–348.
- Perez, S.E., Lumayag, S., Kovacs, B., Mufson, E.J., Xu, S., 2009. Beta-amyloid deposition and functional impairment in the retina of the APPsw/PS1DeltaE9 transgenic mouse model of Alzheimer's disease. *Invest. Ophthalmol. Vis. Sci.* 50, 793–800.
- Piri, N., Kwong, J.M., Caprioli, J., 2013. Crystallins in retinal ganglion cell survival and regeneration. *Mol. Neurobiol.* 48, 819–828.
- Polanco, J.C., Li, C., Bodea, L.G., Martinez-Marmol, R., Meunier, F.A., Gotz, J., 2018. Amyloid-beta and tau complexity - towards improved biomarkers and targeted therapies. *Nat. Rev. Neurol.* 14, 22–39.
- Polo, V., Rodrigo, M.J., Garcia-Martin, E., Otin, S., Larrosa, J.M., Fuentes, M.I., Bambo, M.P., Pablo, L.E., Satue, M., 2017. Visual dysfunction and its correlation with retinal changes in patients with Alzheimer's disease. *Eye* 31, 1034–1041.
- Prakash, A., Kumar, A., 2014. Role of nuclear receptor on regulation of BDNF and neuroinflammation in hippocampus of beta-amyloid animal model of Alzheimer's disease. *Neurotox. Res.* 25, 335–347.
- Prpar Mihevc, S., Majdic, G., 2019. Canine cognitive dysfunction and Alzheimer's disease - two facets of the same disease? *Front. Neurosci.* 13, 604.
- Querques, G., Borrelli, E., Sacconi, R., De Vitis, L., Leocani, L., Santangelo, R., Magnani, G., Comi, G., Bandello, F., 2019. Functional and morphological changes of the retinal vessels in Alzheimer's disease and mild cognitive impairment. *Sci. Rep.* 9, 63.
- Radde, R., Bolmont, T., Kaeser, S.A., Coomaraswamy, J., Lindau, D., Stoltze, L., Calhoun, M.E., Jaggi, F., Wolburg, H., Gengler, S., Haass, C., Ghetti, B., Czech, C., Holscher, C., Mathews, P.M., Jucker, M., 2006. Aβ42-driven cerebral amyloidosis in transgenic mice reveals early and robust pathology. *EMBO Rep.* 7, 940–946.
- Ramirez, A.I., de Hoz, R., Salobrar-Garcia, E., Salazar, J.J., Rojas, B., Ajoy, D., Lopez-Cuenca, I., Rojas, P., Trivino, A., Ramirez, J.M., 2017. The role of microglia in retinal neurodegeneration: Alzheimer's disease, Parkinson, and glaucoma. *Front. Aging Neurosci.* 9, 214.
- Reed, B.T., Behar-Cohen, F., Krantic, S., 2017. Seeing early signs of Alzheimer's disease through the lens of the eye. *Curr. Alzheimer Res.* 14, 6–17.
- Rentsendorj, A., Sheyn, J., Fuchs, D.T., Daley, D., Salumbides, B.C., Schubloom, H.E., Hart, N.J., Li, S., Hayden, E.Y., Teplow, D.B., Black, K.L., Koronyo, Y., Koronyo-Hamaoui, M., 2018. A novel role for osteopontin in macrophage-mediated amyloid-beta clearance in Alzheimer's models. *Brain Behav. Immun.* 67, 163–180.
- Risacher, S.L., Wudunn, D., Pepin, S.M., MaGe, T.R., McDonald, B.C., Flashman, L.A., Wishart, H.A., Pixley, H.S., Rabin, L.A., Pare, N., Englert, J.J., Schwartz, E., Curtain, J.R., West, J.D., O'Neill, D.P., Santulli, R.B., Newman, R.W., Saykin, A.J., 2013. Visual contrast sensitivity in Alzheimer's disease, mild cognitive impairment, and older adults with cognitive complaints. *Neurobiol. Aging* 34, 1133–1144.
- Rosenzweig, N., Dvir-Szternfeld, R., Tsitsou-Kampeli, A., Keren-Shaul, H., Ben-Yehuda, H., Weill-Raynal, P., Cahalon, L., Kertser, A., Baruch, K., Amit, I., Weiner, A., Schwartz, M., 2019. PD-1/PD-L1 checkpoint blockade harnesses monocyte-derived macrophages to combat cognitive impairment in a tauopathy mouse model. *Nat. Commun.* 10, 465.
- Roziog, M.P., Durhuus, J.A., Krogh Nielsen, M., Subhi, Y., Kirkwood, T.B., Westendorp, R.G., Sorensen, T.L., 2020. Age-related macular degeneration: a two-level model hypothesis. *Prog. Retin. Eye Res.* 76, 100825.
- Ruzickova, S., Stanek, D., 2017. Mutations in spliceosomal proteins and retina degeneration. *RNA Biol.* 14, 544–552.
- Sadowski, M., Pankiewicz, J., Scholtzova, H., Ji, Y., Quartermain, D., Jensen, C.H., Duff, K., Nixon, R.A., Gruen, R.J., Wisniewski, T., 2004. Amyloid-beta deposition is associated with decreased hippocampal glucose metabolism and spatial memory impairment in APP/PS1 mice. *J. Neuropathol. Exp. Neurol.* 63, 418–428.
- Sadun, A.A., Bassi, C.J., 1990. Optic nerve damage in Alzheimer's disease. *Ophthalmology* 97, 9–17.
- Sadun, A.A., Borchert, M., DeVita, E., Hinton, D.R., Bassi, C.J., 1987. Assessment of visual impairment in patients with Alzheimer's disease. *Am. J. Ophthalmol.* 104, 113–120.
- Sagare, A.P., Bell, R.D., Zhao, Z., Ma, Q., Winkler, E.A., Ramanathan, A., Zlokovic, B.V., 2013. Pericyte loss influences Alzheimer-like neurodegeneration in mice. *Nat. Commun.* 4, 2932.
- Sanchez, D., Castilla-Marti, M., Rodriguez-Gomez, O., Valero, S., Piferrer, A., Martinez, G., Martinez, J., Serra, J., Moreno-Grau, S., Hernandez-Olasagarre, B., De Rojas, I., Hernandez, I., Abdelnour, C., Rosende-Roca, M., Vargas, L., Mauleon, A., Santos-Santos, M.A., Alegret, M., Ortega, G., Espinosa, A., Perez-Cordon, A., Sanabria, A., Ciudad, A., Simo, R., Hernandez, C., Villoslada, P., Ruiz, A., Tarraga, L., Boada, M., 2018. Usefulness of peripapillary nerve fiber layer thickness assessed by optical coherence tomography as a biomarker for Alzheimer's disease. *Sci. Rep.* 8, 16345.
- Sanchez, D., Castilla-Marti, M., Marquie, M., Valero, S., Moreno-Grau, S., Rodriguez-Gomez, O., Piferrer, A., Martinez, G., Martinez, J., Rojas, I., Hernandez, I., Abdelnour, C., Rosende-Roca, M., Vargas, L., Mauleon, A., Gil, S., Alegret, M., Ortega, G., Espinosa, A., Perez-Cordon, A., Sanabria, A., Roberto, N., Ciudad, A., Simo, R., Hernandez, C., Tarraga, L., Boada, M., Ruiz, A., 2020. Evaluation of macular thickness and volume tested by optical coherence tomography as biomarkers for Alzheimer's disease in a memory clinic. *Sci. Rep.* 10, 1580.
- Sasaguri, H., Nilsson, P., Hashimoto, S., Nagata, K., Saito, T., De Strooper, B., Hardy, J., Vassar, R., Winblad, B., Saido, T.C., 2017. APP mouse models for Alzheimer's disease preclinical studies. *EMBO J.* 36, 2473–2487.
- Sayyad, Z., Sirohi, K., Radha, V., Swarup, G., 2017. 661W is a retinal ganglion precursor-like cell line in which glaucoma-associated optineurin mutants induce cell death selectively. *Sci. Rep.* 7, 16855.
- Schneider, L., 2020. A resurrection of aducanumab for Alzheimer's disease. *Lancet Neurol.* 19, 111–112.

- Schon, C., Hoffmann, N.A., Ochs, S.M., Burgold, S., Filser, S., Steinbach, S., Seeliger, M. W., Arzberger, T., Goedert, M., Kretschmar, H.A., Schmidt, B., Herms, J., 2012. Long-term in vivo imaging of fibrillar tau in the retina of P301S transgenic mice. *PLoS One* 7, e53547.
- Selkoe, 2011. Resolving controversies on the path to Alzheimer's therapeutics. *Nat Med* 17 (9), 1060–1065. <https://doi.org/10.1038/nm.2460>.
- Selkoe, D.J., Hardy, J., 2016. The amyloid hypothesis of Alzheimer's disease at 25 years. *EMBO Mol. Med.* 8, 595–608.
- Sesele, K., Thanopoulou, K., Paouri, E., Tsefou, E., Klinakis, A., Georgopoulos, S., 2013. Conditional inactivation of nicastrin restricts amyloid deposition in an Alzheimer's disease mouse model. *Aging Cell* 12, 1032–1040.
- Sharafi, S.M., Sylvestre, J.P., Chevrefils, C., Soucy, J.P., Beaulieu, S., Pascoal, T.A., Arbut, J.D., Rheume, M.A., Robillard, A., Chayer, C., Rosa-Neto, P., Mathotaarachchi, S.S., Nasreddine, Z.S., Gauthier, S., Lesage, F., 2019. Vascular retinal biomarkers improves the detection of the likely cerebral amyloid status from hyperspectral retinal images. *Alzheimers Dement (N Y)* 5, 610–617.
- Shen, Y., Liu, L., Cheng, Y., Feng, W., Shi, Z., Zhu, Y., Wu, W., Li, C., 2014. Retinal nerve fiber layer thickness is associated with episodic memory deficit in mild cognitive impairment patients. *Curr. Alzheimer Res.* 11, 259–266.
- Shen, T., You, Y., Joseph, C., Mirzaei, M., Klistorner, A., Graham, S.L., Gupta, V., 2018. BDNF polymorphism: a review of its diagnostic and clinical relevance in neurodegenerative disorders. *Aging Dis.* 9, 523–536.
- Shi, H., Koronyo, V., Rentsendorj, A., Regis, G.C., Sheyn, J., Fuchs, D.T., Kramerov, A.A., Ljubimov, A.V., Dumitrascu, O.M., Rodriguez, A.R., Barron, E., Hinton, D.R., Black, K.L., Miller, C.A., Mirzaei, N., Koronyo-Hamaoui, M., 2020. Identification of early pericyte loss and vascular amyloidosis in Alzheimer's disease retina. *Acta Neuropathol.* 139, 813–836.
- Sims, R., van der Lee, S.J., Naj, A.C., Bellenguez, C., Badarinarayan, N., Jakobsdottir, J., Kunkle, B.W., Boland, A., Raybould, R., Bis, J.C., Martin, E.R., Grenier-Boley, B., Heilmann-Heimbach, S., Chouraki, V., Kuzma, A.B., Sleegers, K., Vronskaya, M., Ruiz, A., Graham, R.R., Oloso, R., Hoffmann, P., Grove, M.L., Vardarajan, B.N., Hiltunen, M., Nothen, M.M., White, C.C., Hamilton-Nelson, K.L., Epelbaum, J., Maier, W., Choi, S.H., Beecham, G.W., Dulary, C., Herms, S., Smith, A.V., Funk, C.C., DeBois, C., Forstner, A.J., Ahmad, S., Li, H., Bacq, D., Harold, D., Satizabal, C.L., Valladares, O., Squassina, A., Thomas, R., Brody, J.A., Qu, L., Sanchez-Juan, P., Morgan, T., Wolters, F.J., Zhao, Y., Garcia, F.S., Denning, N., Fornage, M., Malamon, J., Naranjo, M.C.D., Majounie, E., Mosley, T.H., Dombroski, B., Wallon, D., Lupton, M.K., Dupuis, J., Whitehead, P., Fratiglioni, L., Medway, C., Jian, X., Mukherjee, S., Keller, L., Brown, K., Lin, H., Cantwell, L.B., Panza, F., McGuinness, B., Moreno-Grau, S., Burgess, J.D., Solfrizzi, V., Proitsi, P., Adams, H. H., Allen, M., Seripa, D., Pastor, P., Cupples, L.A., Price, N.D., Hannequin, D., Frank-Garcia, A., Levy, D., Chakrabarty, P., Caffarra, P., Giegling, I., Beiser, A.S., Giedraitis, V., Hampel, M.H., Garcia, M.E., Wang, X., Lannfelt, L., Mecocci, P., Eiriksdottir, G., Crane, P.K., Pasquier, F., Boccardi, V., Henandez, I., Barber, R.C., Scherer, M., Tarraga, L., Adams, P.M., Leber, M., Chen, Y., Albert, M.S., Riedel-Heller, S., Emilsson, V., Beekly, D., Braae, A., Schmidt, R., Blacker, D., Masullo, C., Schmidt, H., Doody, R.S., Spalletta, G., Longstreth Jr., W.T., Fairchild, T.J., Bossu, P., Lopez, O.L., Frosch, M.P., Sacchinnelli, E., Ghetti, B., Yang, Q., Huebinger, R.M., Jessen, F., Li, S., Kamboh, M.I., Morris, J., Sotolongo-Grau, O., Katz, M.J., Corcoran, C., Dunstan, M., Braddell, A., Thomas, C., Meggy, A., Marshall, R., Gerrish, A., Chapman, J., Aguiar, M., Taylor, S., Hill, M., Fairen, M.D., Hodges, A., Vellas, B., Soininen, H., Kloszewska, I., Daniilidou, M., Uphill, J., Patel, Y., Hughes, J.T., Lord, J., Turton, J., Hartmann, A.M., Cecchetti, R., Fenoglio, C., Serpente, M., Arcaio, M., Caltagirone, C., Orfei, M.D., Ciaramella, A., Pichler, S., Mayhaus, M., Gu, W., Lleo, A., Fortea, J., Blesa, R., Barber, I.S., Brookes, K., Cupidi, C., Maletta, R.G., Carrell, D., Sorbi, S., Moebus, S., Urbano, M., Pilotto, A., Kornhuber, J., Bosco, P., Todd, S., Craig, D., Johnston, J., Gill, M., Lawlor, B., Lynch, A., Fox, N.C., Hardy, J., Consortium, A., Albin, R.L., Apostolova, L.G., Arnold, S.E., Asthana, S., Atwood, C.S., Baldwin, C.T., Barnes, L.L., Barral, S., Beach, T.G., Becker, J.T., Bigio, E.H., Bird, T.D., Boeve, B.F., Bowen, J.D., Boxer, A., Burke, J.R., Burns, J.M., Buxbaum, J.D., Cairns, N.J., Cao, C., Carlson, C.S., Carlsson, C.M., Carney, R.M., Carrasquillo, M.M., Carroll, S.L., Diaz, C.C., Chui, H.C., Clark, D.G., Cribbs, D.H., Crocco, E.A., DeCarli, C., Dick, M., Duara, R., Evans, D.A., Faber, K.M., Fallon, K.B., Fardo, D.W., Farlow, M.R., Ferris, S., Foroud, T.M., Galasko, D.R., Gearing, M., Geschwind, D.H., Gilbert, J.R., Graff-Radford, N.R., Green, R.C., Growdon, J.H., Hamilton, R.L., Harrell, L.E., Honig, L.S., Huentelman, M.J., Hulette, C.M., Hyman, B.T., Jarvik, G.P., Abner, E., Jin, L.W., Jun, G., Karydas, A., Kaye, J.A., Kim, R., Kowall, N.W., Kramer, J.H., LaFerla, F.M., Lah, J.J., Leverenz, J.B., Levey, A.I., Li, G., Lieberman, A.P., Lunetta, K.L., Lyketsos, C.G., Marson, D.C., Martiniuk, F., Mash, D.C., Masliah, E., McCormick, W. C., McCurry, S.M., McDavid, A.N., McKeel, A.C., Mesulam, M., Miller, B.L., Miller, C. A., Miller, J.W., Morris, J.C., Murrell, J.R., Myers, A.J., O'Bryant, S., Olchney, J.M., Pankratz, V.S., Parisi, J.E., Paulson, H.L., Perry, W., Peskind, E., Pierce, A., Poon, W. W., Potter, H., Quinn, J.F., Raj, A., Raskind, M., Reisberg, B., Reitz, C., Ringman, J. M., Roberson, E.D., Rogava, E., Rosen, H.J., Rosenberg, R.N., Sager, M.A., Saykin, A.J., Schneider, J.A., Schneider, L.S., Seeley, W.W., Smith, A.G., Sonnen, J. A., Spina, S., Stern, R.A., Swardlow, R.H., Tanzi, R.E., Thornton-Wells, T.A., Trojanowski, J.Q., Troncoso, J.C., Van Deerlin, V.M., Van Eldik, L.J., Vinters, H.V., Vonsattel, J.P., Weintraub, S., Welsh-Bohmer, K.A., Wilhelmsen, K.C., Williamson, J., Wingo, T.S., Wolter, R.L., Wright, C.B., Yu, C.E., Yu, L., Garzia, F., Golamally, F., Septier, G., Engelborghs, S., Vandenberghe, R., De Deyn, P.P., Fernandez, C.M., Benito, Y.A., Thonberg, H., Forsell, C., Lilius, L., Kinhult-Stahlbom, A., Kilander, L., Brundin, R., Concari, L., Helisalmi, S., Koivisto, A.M., Haapasalo, A., Dermecourt, V., Fievet, N., Hanon, O., Dufouil, C., Brice, A., Ritchie, K., Dubois, B., Himali, J.J., Keene, C.D., Tschanz, J., Fitzpatrick, A.L., Kukull, W.A., Norton, M., Aspelund, T., Larson, E.B., Munger, R., Rotter, J.I., Lipton, R.B., Bullido, M.J., Hofman, A., Montine, T.J., Coto, E., Boerwinkle, E., Petersen, R.C., Alvarez, V., Rivadeneira, F., Reiman, E.M., Gallo, M., O'Donnell, C.J., Reisch, J.S., Bruni, A.C., Royall, D.R., Dichgans, M., Sano, M., Galimberti, D., St George-Hyslop, P., Scarpini, E., Tsuang, D.W., Mancuso, M., Bonuccelli, U., Winslow, A.R., Daniele, A., Wu, C.K., Gerad/Perades, C.A.E., Peters, O., Nacmias, B., Riemenschneider, M., Heun, R., Brayne, C., Rubinsztein, D.C., Bras, J., Guerreiro, R., Al-Chalabi, A., Shaw, C.E., Collinge, J., Mann, D., Tzolaki, M., Clarimon, J., Sussams, R., Lovestone, S., O'Donovan, M.C., Owen, M.J., Behrens, T.W., Mead, S., Goate, A.M., Uitterlinden, A.G., Holmes, C., Cruchaga, C., Ingelsson, M., Bennett, D. A., Powell, J., Golde, T.E., Graff, C., De Jager, P.L., Morgan, K., Ertekin-Taner, N., Combarros, O., Psaty, B.M., Passmore, P., Younkin, S.G., Berr, C., Gudnason, V., Rujescu, D., Dickson, D.W., Dartigues, J.F., DeStefano, A.L., Ortega-Cubero, S., Hakonarson, H., Campion, D., Boada, M., Kawue, J.K., Farrer, L.A., Van Broeckhoven, C., Ikram, M.A., Jones, L., Haines, J.L., Tzourio, C., Launer, L.J., Escott-Price, V., Mayeux, R., Deluze, J.F., Amin, N., Holmans, P.A., Pericak-Vance, M.A., Amouyel, P., van Duijn, C.M., Ramirez, A., Wang, L.S., Lambert, J.C., Seshadri, S., Williams, J., Schellenberg, G.D., 2017. Rare coding variants in PLOG2, ABI3, and TREM2 implicate microglial-mediated innate immunity in Alzheimer's disease. *Nat. Genet.* 49, 1373–1384.
- Sivak, J.M., 2013. The aging eye: common degenerative mechanisms between the Alzheimer's brain and retinal disease. *Invest. Ophthalmol. Vis. Sci.* 54, 871–880.
- Snyder, P.J., Johnson, L.N., Lim, Y.Y., Santos, C.Y., Alber, J., Maruff, P., Fernandez, B., 2016. Nonvascular retinal imaging markers of preclinical Alzheimer's disease. *Alzheimers Dement (Amst)* 4, 169–178.
- Spangenberg, E.E., Lee, R.J., Najafi, A.R., Rice, R.A., Elmore, M.R., Blurton-Jones, M., West, B.L., Green, K.N., 2016. Eliminating microglia in Alzheimer's mice prevents neuronal loss without modulating amyloid-beta pathology. *Brain* 139, 1265–1281.
- Sperling, R.A., Aisen, P.S., Beckett, L.A., Bennett, D.A., Craft, S., Fagan, A.M., Iwatsubo, T., Jack Jr., C.R., Kaye, J., Montine, T.J., Park, D.C., Reiman, E.M., Rowe, C.C., Siemers, E., Stern, Y., Yaffe, K., Carrillo, M.C., Thies, B., Morrison-Bogorad, M., Wagster, M.V., Phelps, C.H., 2011. Toward defining the preclinical stages of Alzheimer's disease: recommendations from the National Institute on Aging-Alzheimer's Association workgroups on diagnostic guidelines for Alzheimer's disease. *Alzheimers Dement* 7, 280–292.
- Spire-Jones, T.L., Hyman, B.T.J.N., 2014. The intersection of amyloid beta and tau at synapses in Alzheimer's disease, 82, 756–771.
- Sumirtanurdin, R., Thalib, A.Y., Cantona, K., Abdulah, R., 2019. Effect of genetic polymorphisms on Alzheimer's disease treatment outcomes: an update. *Clin. Interv. Aging* 14, 631–642.
- Tanifum, E.A., Starosolski, Z.A., Fowler, S.W., Jankowsky, J.L., Annapragada, A.V., 2014. Cerebral vascular leak in a mouse model of amyloid neuropathology. *J. Cerebr. Blood Flow Metabol.* 34, 1646–1654.
- Thientunyakit, T., Sethanandha, C., Muangpaisan, W., Chawalparit, O., Arunrungvichian, K., Siriprapa, T., Vichianin, Y., Kamal, S., Suppasilp, C., Thongprapant, T., Chanachai, R., Gelovani, J.G., 2020. Relationships between amyloid levels, glucose metabolism, morphologic changes in the brain and clinical status of patients with Alzheimer's disease. *Ann. Nucl. Med.* 34, 337–348.
- Thijssen, E.H., La Joie, R., Wolf, A., Strom, A., Wang, P., Iaccarino, L., Bourakova, V., Cobigo, Y., Heuer, H., Spina, S., VandeVrede, L., Chai, X., Proctor, N.K., Airey, D.C., Scherbinin, S., Duggan Evans, C., Sims, J.R., Zetterberg, H., Blennow, K., Karydas, A.M., Teunissen, C.E., Kramer, J.H., Grinberg, L.T., Seeley, W.W., Rosen, H., Boeve, B.F., Miller, B.L., Rabinovici, G.D., Dage, J.L., Rojas, J.C., Boxer, A. L., Advancing, R., Treatment for Frontotemporal Lobar Degeneration, i., 2020. Diagnostic value of plasma phosphorylated tau181 in Alzheimer's disease and frontotemporal lobar degeneration. *Nat. Med.* 26, 387–397.
- Toodyan, N., 2016. Professor alois alzheimer (1864-1915): lest we forget. *J. Clin. Neurosci.* 31, 47–55.
- Trebbastoni, A., D'Antonio, F., Bruscolini, A., Marcelli, M., Cecere, M., Campanelli, A., Imbriano, L., de Lena, C., Gharbiya, M., 2016. Retinal nerve fibre layer thickness changes in Alzheimer's disease: results from a 12-month prospective case series. *Neurosci. Lett.* 629, 165–170.
- Tucker, H.M., Kihiko, M., Caldwell, J.N., Wright, S., Kawarabayashi, T., Price, D., Walker, D., Scheff, S., McGillis, J.P., Rydel, R.E., Estus, S., 2000. The plasmin system is induced by and degrades amyloid-beta aggregates. *J. Neurosci.* 20, 3937–3946.
- Tzekov, R., Mullan, M., 2014. Vision function abnormalities in Alzheimer disease. *Surv. Ophthalmol.* 59, 414–433.
- van de Kreeke, J.A., Nguyen, H.T., Konijnenberg, E., Tomassen, J., den Braber, A., Ten Kate, M., Yaqub, M., van Berckel, B., Lammertsma, A.A., Boomsma, D.I., Tan, S.H., Verbraak, F., Visser, P.J., 2020. Optical coherence tomography angiography in preclinical Alzheimer's disease. *Br. J. Ophthalmol.* 104, 157–161.
- van der Flier, W.M., Skoog, I., Schneider, J.A., Pantoni, L., Mok, V., Chen, C.L.H., Scheltens, P., 2018. Vascular cognitive impairment. *Nat. Rev. Dis. Primers* 4, 18003.
- Villemagne, V.L., Dore, V., Burnham, S.C., Masters, C.L., Rowe, C.C., 2018. Imaging tau and amyloid-beta proteinopathies in Alzheimer disease and other conditions. *Nat. Rev. Neurol.* 14, 225–236.
- Viswanathan, A., Greenberg, S.M., 2011. Cerebral amyloid angiopathy in the elderly. *Ann. Neurol.* 70, 871–880.
- Wang, C.A., McInnis, H., Brien, D.C., Pari, G., Munoz, D.P., 2016. Disruption of pupil size modulation correlates with voluntary motor preparation deficits in Parkinson's disease. *Neuropsychologia* 80, 176–184.
- Wang, W.W., Wang, H.Z., Liu, J.R., Zhang, X.F., Li, M., Huo, Y.J., Yang, X.G., 2018. Diagnostic ability of ganglion cell complex thickness to detect glaucoma in high myopia eyes by Fourier domain optical coherence tomography. *Int. J. Ophthalmol.* 11, 791–796.
- Williams, P.A., Thirgood, R.A., Oliphant, H., Frizzati, A., Littlewood, E., Votruba, M., Good, M.A., Williams, J., Morgan, J.E., 2013. Retinal ganglion cell dendritic

- degeneration in a mouse model of Alzheimer's disease. *Neurobiol. Aging* 34, 1799–1806.
- Williams, M.A., McGowan, A.J., Cardwell, C.R., Cheung, C.Y., Craig, D., Passmore, P., Silvestri, G., Maxwell, A.P., McKay, G.J., 2015. Retinal microvascular network attenuation in Alzheimer's disease. *Alzheimers Dement (Amst)* 1, 229–235.
- Williams, P.A., Tribble, J.R., Pepper, K.W., Cross, S.D., Morgan, B.P., Morgan, J.E., John, S.W., Howell, G.R., 2016. Inhibition of the classical pathway of the complement cascade prevents early dendritic and synaptic degeneration in glaucoma. *Mol. Neurodegener.* 11, 26.
- Williams, E.A., McGuone, D., Frosch, M.P., Hyman, B.T., Laver, N., Stemmer-Rachamimov, A., 2017. Absence of alzheimer disease neuropathologic changes in eyes of subjects with alzheimer disease. *J. Neuropathol. Exp. Neurol.* 76, 376–383.
- Wong, I.Y., Koizumi, H., Lai, W.W., 2011. Enhanced depth imaging optical coherence tomography. *Ophthalmic Surg. Laser. Imag.* 42 (Suppl. 1), S75–S84.
- Xiying, M., Wenbo, W., Wangyi, F., Qinghui, L., 2017. Association of apolipoprotein E polymorphisms with age-related macular degeneration subtypes: an updated systematic review and meta-analysis. *Arch. Med. Res.* 48, 370–377.
- Yehoshua, Z., de Amorim Garcia Filho, C.A., Nunes, R.P., Gregori, G., Penha, F.M., Moshfeghi, A.A., Zhang, K., Sadda, S., Feuer, W., Rosenfeld, P.J., 2014. Systemic complement inhibition with eculizumab for geographic atrophy in age-related macular degeneration: the COMPLETE study. *Ophthalmology* 121, 693–701.
- Yin, J., Han, P., Song, M., Nielsen, M., Beach, T.G., Serrano, G.E., Liang, W.S., Caselli, R. J., Shi, J., 2018. Amyloid-beta increases tau by mediating sirtuin 3 in Alzheimer's disease. *Mol. Neurobiol.* 55, 8592–8601.
- Yoon, S.P., Grewal, D.S., Thompson, A.C., Polascik, B.W., Dunn, C., Burke, J.R., Fekrat, S., 2019. Retinal microvascular and neurodegenerative changes in Alzheimer's disease and mild cognitive impairment compared with control participants. *Ophthalmol. Retina* 3, 489–499.
- You, Y., Gupta, V.K., Li, J.C., Al-Adawy, N., Klistorner, A., Graham, S.L., 2014. FTY720 protects retinal ganglion cells in experimental glaucoma. *Invest. Ophthalmol. Vis. Sci.* 55, 3060–3066.
- You, Y., Graham, E.C., Shen, T., Yiannikas, C., Parratt, J., Gupta, V., Barton, J., Dwyer, M., Barnett, M.H., Fraser, C.L., Graham, S.L., Klistorner, A., 2018. Progressive inner nuclear layer dysfunction in non-optic neuritis eyes in MS. *Neuro. Neuroimmunol. Neuroinflamm.* 5, e427.
- You, Y., Joseph, C., Wang, C., Gupta, V., Liu, S., Yiannikas, C., Chua, B.E., Chitranshi, N., Shen, T., Dheer, Y., Invernizzi, A., Borotkanics, R., Barnett, M., Graham, S.L., Klistorner, A., 2019. Demyelination precedes axonal loss in the transneuronal spread of human neurodegenerative disease. *Brain* 142, 426–442.
- You, Y., Thie, J., Klistorner, A., Gupta, V.K., Graham, S.L., 2012. Normalization of visual evoked potentials using underlying electroencephalogram levels improves amplitude reproducibility in rats. *Investig. Ophthalmol. Vis. Sci.* 53 (3), 1473–1478.
- Yucel, Y.H., Zhang, Q., Weinreb, R.N., Kaufman, P.L., Gupta, N., 2003. Effects of retinal ganglion cell loss on magno-, parvo-, koniocellular pathways in the lateral geniculate nucleus and visual cortex in glaucoma. *Prog. Retin. Eye Res.* 22, 465–481.
- Yue, N., Huang, H., Zhu, X., Han, Q., Wang, Y., Li, B., Liu, Q., Wu, G., Zhang, Y., Yu, J., 2017. Activation of P2X7 receptor and NLRP3 inflammasome assembly in hippocampal glial cells mediates chronic stress-induced depressive-like behaviors. *J. Neuroinflammation* 14, 102.
- Zeki Al Hazzouri, A., Newman, A.B., Simonsick, E., Sink, K.M., Sutton Tyrrell, K., Watson, N., Satterfield, S., Harris, T., Yaffe, K., Health, A.B.C.S., 2013. Pulse wave velocity and cognitive decline in elders: the Health, Aging, and Body Composition study. *Stroke* 44, 388–393.
- Zempel, H., Mandelkow, E.M., 2012. Linking amyloid-beta and tau: amyloid-beta induced synaptic dysfunction via local wreckage of the neuronal cytoskeleton. *Neurodegener. Dis.* 10, 64–72.
- Zhao, H., Chang, R., Che, H., Wang, J., Yang, L., Fang, W., Xia, Y., Li, N., Ma, Q., Wang, X., 2013. Hyperphosphorylation of tau protein by calpain regulation in retina of Alzheimer's disease transgenic mouse. *Neurosci. Lett.* 551, 12–16.
- Zhao, Y., Bhattacharjee, S., Jones, B.M., Hill, J.M., Clement, C., Sambamurti, K., Dua, P., Lukiw, W.J., 2015. Beta-amyloid precursor protein (betaAPP) processing in Alzheimer's disease (AD) and age-related macular degeneration (AMD). *Mol. Neurobiol.* 52, 533–544.
- Zhou, J.P., Feng, Z.G., Yuan, B.L., Yu, S.Z., Li, Q., Qu, H.Y., Sun, M.J., 2008. Transduced PTD-BDNF fusion protein protects against beta amyloid peptide-induced learning and memory deficits in mice. *Brain Res.* 1191, 12–19.
- Zhou, L., Gao, Q., Nie, M., Gu, J.L., Hao, W., Wang, L., Cao, J.M., 2016. Degeneration and energy shortage in the suprachiasmatic nucleus underlies the circadian rhythm disturbance in ApoE(-/-) mice: implications for Alzheimer's disease. *Sci. Rep.* 6, 36335.