




CLINICAL REPORT

Heterozygous nonsense *ARX* mutation in a family highlights the complexity of clinical and molecular diagnosis in case of chromosomal and single gene disorder co-inheritance

Alice Traversa¹ | Enrica Marchionni² | Agnese Giovannetti¹ | Maria L. Genovesi² | Noemi Panzironi² | Katia Margiotti³  | Giulia Napoli² | Francesca Picci Sparascio^{2,4} | Alessandro De Luca⁴ | Francesco Petrizzelli^{2,5} | Massimo Carella⁶ | Francesco Cardona⁷ | Silvia Bernardo^{2,8}  | Lucia Manganaro⁸ | Tommaso Mazza⁵ | Antonio Pizzuti^{2,1} | Viviana Caputo² 

¹Laboratory of Clinical Genomics, Fondazione IRCCS Casa Sollievo della Sofferenza, San Giovanni Rotondo (FG), Italy

²Department of Experimental Medicine, Sapienza University of Rome, Rome, Italy

³Laboratorio di Genetica Medica, ALTAMEDICA, Rome, Italy

⁴UOS Diagnosi Genetica Molecolare, Fondazione IRCCS Casa Sollievo della Sofferenza, San Giovanni Rotondo (FG), Italy

⁵Laboratory of Bioinformatics, Fondazione IRCCS Casa Sollievo della Sofferenza, San Giovanni Rotondo (FG), Italy

⁶Laboratory of Medical Genetics, Fondazione IRCCS Casa Sollievo della Sofferenza, San Giovanni Rotondo (FG), Italy

⁷Department of Human Neurosciences, Sapienza University of Rome, Rome, Italy

⁸Department of Radiological, Oncological, and Pathological Anatomy Sciences, Sapienza University of Rome, Rome, Italy

Correspondence

Viviana Caputo, Department of Experimental Medicine, Sapienza University of Rome, Rome, Italy.
Email: viviana.caputo@uniroma1.it

Funding information

This work was supported by the Italian Ministry of Health [RC1903MX33, 2019].

Abstract

Background: Corpus callosum agenesis (ACC) is one of the most frequent Central Nervous System (CNS) malformations. However, genetics underlying isolated forms is still poorly recognized. Here, we report on two female familial cases with partial ACC. The proband shows isolated partial ACC and a mild neurodevelopmental phenotype. A fetus from a previous interrupted pregnancy exhibited a complex phenotype including partial ACC and the occurrence of a *de novo* 17q12 microduplication, which was interpreted as probably disease-causing.

Methods: A trio-based clinical exome sequencing (CES) was performed.

Results: Clinical exome sequencing data analysis led to identifying a heterozygous nonsense variant (NM_139058.3:c.922G>T; NP_620689.1:p.Glu308Ter) in the aristaless related homeobox gene (*ARX*) in the proband, with a putative *de novo* occurrence, producing a hypothetical protein lacking two essential domains. Sanger analysis confirmed the wild-type status of both parents in different tissues, and disclosed the occurrence of the nonsense variant in the fetus of the interrupted

Alice Traversa and Enrica Marchionni have equally contributed to the work.

This is an open access article under the terms of the Creative Commons Attribution-NonCommercial License, which permits use, distribution and reproduction in any medium, provided the original work is properly cited and is not used for commercial purposes.

© 2020 The Authors. *Molecular Genetics & Genomic Medicine* published by Wiley Periodicals LLC

pregnancy, suggesting a formerly unrecognized contribution of the *ARX* mutation to the fetus' phenotype and gonadal or gonadosomatic mosaicism in one of the parents.

Conclusion: This study describes the phenotype associated with a heterozygous loss of function variant in *ARX*. Moreover, it highlights the importance of investigating both chromosomal and genetic contributions in cases of complex syndromic phenotypes involving CNS.

KEYWORDS

17q12 duplication syndrome, array-CGH, *ARX*, clinical exome sequencing, corpus callosum, dual diagnosis

1 | INTRODUCTION

Agenesis of the corpus callosum (ACC) is one of the most frequent Central Nervous System (CNS) malformations, with an estimated prevalence of 2.56 per 10,000 births (Stoll, Dott, & Roth, 2019). ACC, which can be complete or partial, is frequently associated with other cerebral or extra-cerebral malformations (*e.g.*, in musculoskeletal, urogenital, cardiovascular and digestive systems [Stoll et al., 2019]) and present in recognized syndromes. In these cases, the prognosis is often unfavorable, especially when additional cerebral malformations are observed (Sotiriadis & Makrydimas, 2012). Differently, isolated ACC usually has a more favorable outcome, as a normal neurological development is described in more than 70% of cases (D'Antonio et al., 2016). However, the remaining patients manifest a highly heterogeneous phenotype, which includes different levels of neurodevelopmental and/or cognitive disabilities and/or behavioral problems (D'Antonio et al., 2016). Chromosomal rearrangements and point mutations in genes with pleiotropic effect have been identified as causative of severe phenotypes including ACC. Instead, the molecular bases of isolated ACC still lack elucidation. To date, only very few genes have been reported as causative of isolated ACC. Monoallelic incompletely penetrant mutations in *DCC* (*DCC* netrin 1 receptor, MIM 120470) have been associated with isolated ACC and/or mirror movements in several families with variable expressivity (Marsh et al., 2017, 2018; Sagi-Dain et al., 2020). Moreover, hypomorphic biallelic missense variants in a second gene, *CDK5RAP2* (*CDK5* regulatory subunit associated protein 2, MIM 608201), were described in three siblings presenting ACC (Jouan et al., 2016). The paucity of genetic bases characterization is predictably due to clinical heterogeneity of isolated ACC and the remarkable number of asymptomatic subjects. Moreover, the frequently moderate to mild neurodevelopmental manifestations and the limited number of long-term postnatal follow-up studies make this condition clinically under-characterized. Here, we describe the phenotype and the underlying genetics of two female familial cases,

a fetus from an interrupted pregnancy and a 19-month-old child, with partial ACC. The application of a trio-based clinical exome sequencing (CES) and array-CGH permitted to shed light on the complexity in achieving an accurate genetic diagnosis and appropriate counseling in cases of isolated and syndromic conditions including ACC.

2 | CASE STUDY

The proband (II:3) was a 19-month-old female, born from healthy nonconsanguineous parents. She was referred to the Clinical Genetics and Neuropsychiatric Units of Polyclinic Umberto I Hospital for the follow-up of a prenatal diagnosis of partial ACC, made at 25 weeks of gestation (GW) by fetal magnetic resonance imaging (MRI) (Figure 1). Biological samples and clinical information were collected after written informed consent and in accordance with the principles of the Declaration of Helsinki.

Prenatal standard karyotype and array-CGH analysis (8x60K platform; Agilent) resulted normal and fetal MRI scans at 32 GW did not evidence any further anomaly (Figure 1B). After the caesarian section at 39 GW, Apgar score of the newborn was 9/10, birth weight 3.200 kg (M), birth height 49 cm (M) and OFC 34 cm (M). MRI at 1 month confirmed the isolated partial ACC with a slight enlargement of posterior horns of the lateral ventricles (Figure 1B). Abdominal ultrasound (US) and electroencephalogram (EEG) at 2 months were normal. At 5 months, neurological and neuropsychomotor evaluations detected a mild functional asymmetry (left > right) and an incomplete truncus control with repetitive overextensions. Muscular tonus resulted in the normal range, except for a hypertonus of scapular girdle, which limited prehension above the ocular line. A neuropsychomotor rehabilitation, started at 2 months, was carried out weekly. At 6 months, episodes of repetitive head movements during the day were reported, especially upon awakening; sleep and standard EEG recording resulted normal. Follow-up at 12 months evidenced a normal development.

At 22 months, the proband showed global attention difficulties, especially in the expressive language domain (dyslalia). Griffith's Mental Developmental Scale (GMDS-R) showed a total QI of 86. Follow-up at 3 years showed good social

contact and personal autonomy, but language was still limited. Movement Assessment Battery for Children-Second Edition (MABC-2) scale showed mild difficulties in some coordination and balance tasks and more difficulties in fine

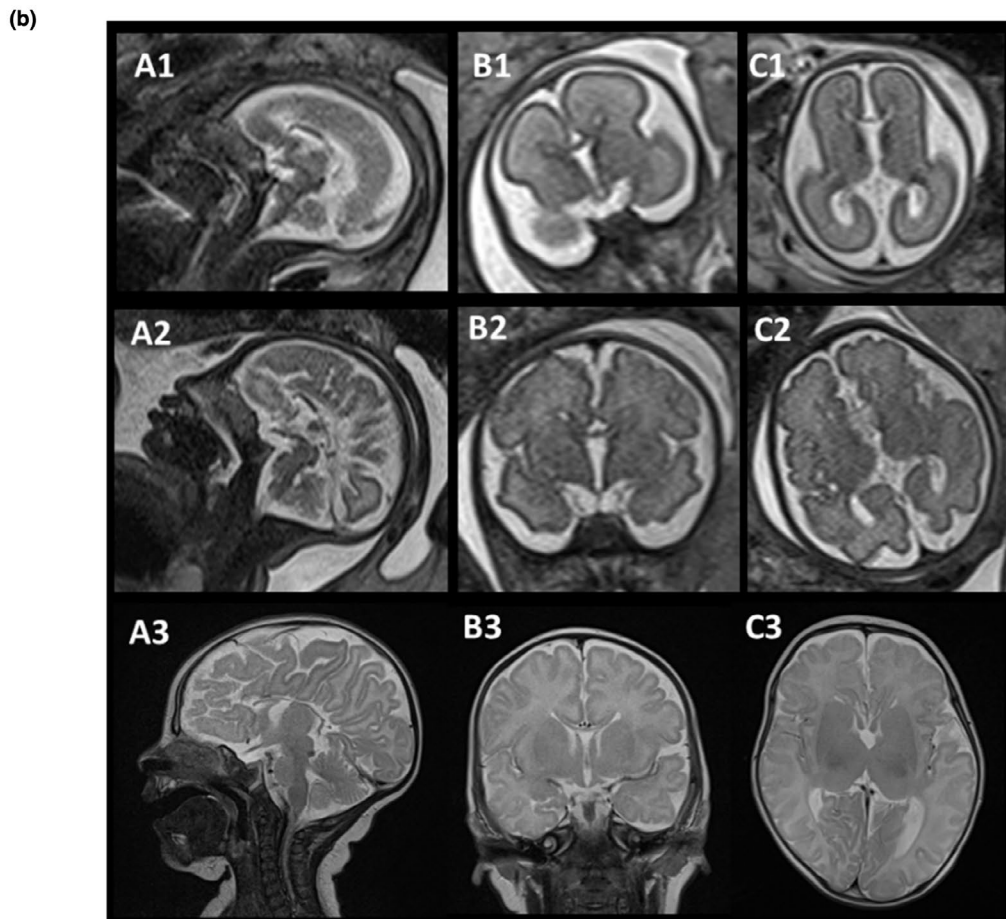
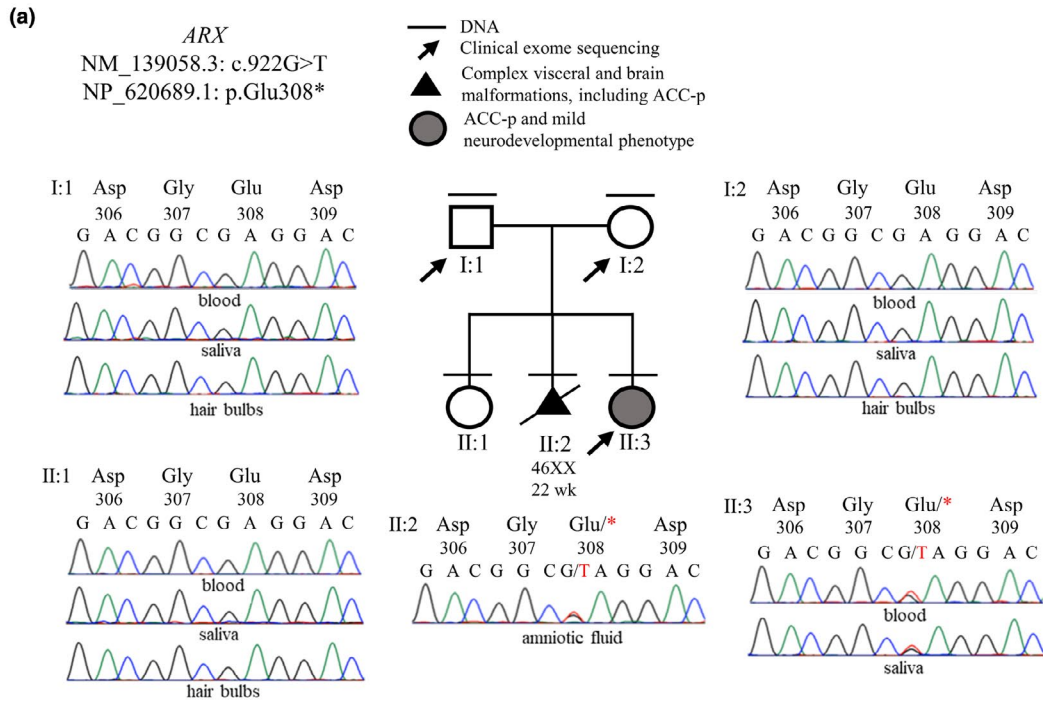


FIGURE 1 (A) Pedigree of the family and *ARX* chromatograms. Black lines at the top indicate available DNAs. Black arrows indicate the individuals who underwent clinical exome sequencing (I:1, I:2, II:3). Clinical diagnosis of the fetus (II:2) and proband (II:3) is shown. ACC-p: partial agenesis of the corpus callosum. Sanger analysis confirmed the presence of the heterozygous *ARX* mutation (NM_139058.3:c.922G>T; NP_620689.1:p.Glu308Ter) in proband's DNA from blood and saliva, and in DNA from amniocytes of II:2, and the wild-type status of both parents and sister (tested tissues: blood, saliva, hair bulbs). (B) Fetal MRI at 25 GW (A1, B1, C1) and 32 GW (A2, B2, C2). Postnatal MRI (A3, B3, C3) at 1 month (subject II:3). Sagittal planes (A1, A2, A3) showing partial agenesis of the corpus callosum, with thickening of the anterior part of the CC in the prenatal MRI (A1, A2), not visible in the postnatal MRI (A3). Coronal planes (B1, B2, B3) and axial planes (C1, C2, C3) showing thin pons fibers and fornix hypertrophy. No signal anomalies of the white matter neither cortical anomalies were identified in the prenatal and postnatal MRI. The gyration was in accordance with the gestational age and the postnatal age (1 month). MRI, magnetic resonance imaging

motor skills. The last examination at 4 years and 3 months showed global improvement in language abilities and in fine motor skills. Proband's parents had an older healthy daughter (II:1) without any abnormal neurological signs and reported of a previous female fetus pregnancy interrupted at 22 GW, following a diagnosis of multiple visceral and cerebral malformations (II:2, Figure 1A). Consistently, fetopsy had evidenced partial ACC (presence of a thin rostral portion), along with other severe brain abnormalities, urogenital anomalies, and some dysmorphic features (Table S1). A prenatal array-CGH (CytoChip microarrays oligo, 4x180K platform, BlueGnome) had disclosed the occurrence of a *de novo* 17q12 microduplication [arr 17q12(31,635,490–33,323,002)x3 (NCBI36/hg18)] in the fetus (Table S2), classified as having “uncertain; likely pathogenic” clinical significance following ACMG guidelines.

In order to investigate the molecular causes of partial ACC phenotype in the proband, a trio-based CES was performed using the TruSight One enrichment kit and a MiSeq platform (Illumina). Genomic DNA of the trio and unaffected sister (Figure 1A) was extracted from circulating leukocytes, hair bulbs and saliva using the Gentra Puregene Blood Kit (Qiagen).

Reads alignment to the reference genome (GRCh17/hg19), variant calling and annotation were performed with Burrows-Wheeler Aligner (BWA-MEM V.0.7.17), GATK's HaplotypeCaller (V3.7), ANNOVAR (July 2017 release) and dbNSFP (V.3.5a), respectively. Coverage was 95.9% (I:1), 95.6% (I:2), and 96.8% (II:3) at 20X. A total of 42,062 high-quality variants was identified in the subjects, 28,526 of them occurring in the proband. Filtering variants by only retaining those located in the coding sequence and splice site regions (± 10 bp) identified 4,317 variants. A further filtering step based on the allelic frequency of variants (MAF $\leq 3\%$) in a population database (gnomAD v2.1.1) identified 552 variants. Different inheritance patterns were considered. A heterozygous variant in *ARX* gene (aristaless related homeobox, MIM 300382), mapping on the X chromosome, was identified with a putative *de novo* occurrence. The nucleotide change (NM_139058.3:c.922G>T; NP_620689.1:p.Glu308Ter) introduces a stop codon in the second exon, producing a predicted protein of 307 amino acids, lacking 255 amino acids. The variant is predicted to have a high deleterious impact

(CADD score 36) and is not annotated in gnomAD, while it is reported in dbSNP153 (rs1556055108) without any allelic frequency information. The nonsense mutation is annotated on ClinVar database (ID: 522170) as “pathogenic” and classified as “pathogenic” by InterVar (Li & Wang, 2017), using default parameters.

Sanger sequencing (ABI BigDye Terminator Sequencing Kit V.3.1, ABI Prism 3130XL Genetic Analyzer, Applied Biosystem) confirmed the variant in the proband in all available tissues (*i.e.*, blood and saliva, Figure 1A). The nonsense variant was detected neither through Sanger sequencing on genomic DNA of parents (in all available tissues) nor through manual inspection of reads alignment, using the Integrative Genomics Viewer (IGV).

Sanger sequencing excluded the presence of the variant in the unaffected sister (Figure 1A). Given the recurrence phenotype of partial ACC, the *ARX* variant was also screened on DNA from amniocytes of the interrupted pregnancy. Sequencing analysis disclosed the occurrence of the nonsense variant also in the fetus (II:2, Figure 1A).

X chromosome inactivation levels were evaluated in DNA from leukocytes of patient II:3 through an Androgen Receptor assay (Allen, Zoghbi, Moseley, Rosenblatt, & Belmont, 1992), with minor protocol changes. PCR products' dilutions were subjected to capillary electrophoresis on an ABI Prism 3130XL Genetic Analyzer and analyzed with GeneMapper V4.0 software (Applied Biosystem). Peaks analysis as previously described (Bittel et al., 2008), disclosed no evidence of skewed X inactivation (43:57).

3 | DISCUSSION

Here we report on two female familial cases with a recurrence of partial ACC. The first pregnancy (II:2, Figure 1A) was interrupted due to a severe phenotype, counting several cerebral and extracerebral anomalies. Prenatal array-CGH detected a *de novo* 17q12 microduplication (1.7 Mb), which was interpreted as the likely cause of the phenotype. In the second pregnancy (II:3, Figure 1A), the prenatal diagnosis of apparently isolated partial ACC (Figure 1B) and the exclusion of the recurrence of the duplication, led parents to bring the pregnancy to full term. Postnatal

MRI confirmed the isolated partial ACC (Figure 1B) and neurological and psychiatric monitoring disclosed mild neuropsychomotor problems. The application of a trio-based CES led to identifying a truncating mutation in *ARX* (NM_139058.3:c.922G>T; NP_620689.1:p.Glu308Ter) in the proband, with predicted *de novo* occurrence. This gene encodes for a neuronal transcription factor essential for CNS and genital development (Kitamura et al., 2002). The same variant was subsequently detected through Sanger sequencing on the retrieved DNA of the fetus (II:2). The variant was not identified in any tested parental tissues, pointing out gonadal mosaicism as the most plausible event (Figure 1A). However, gonadosomatic mosaicism is not excludable. Unfortunately, given the distance larger than 1 Mb of this mutation from the most closed informative polymorphisms of the proband available from CES data, we were not able to identify the parental haplotype of occurrence. Accordingly to these observations, the recurrence risk for the couple rises to 28.6% for a subsequent pregnancy (van der Meulen, van der Meulen, & te Meerman, 1995). The high probability of transmission makes genetic counseling even more challenging if we consider the devastating effect that this mutation would produce in a male fetus.

Hemizygous mutations in *ARX* cause a range of phenotypes, spanning from severe forms with genital and CNS anomalies such as lissencephaly (XLAG/HYDAG, MIM 300,215) or ACC (Proud syndrome, MIM 300004), to early infantile epileptic encephalopathy (EIEE1, MIM 308350), and different forms of intellectual disability with or without seizures (Partington Syndrome, MIM 309510; MRXARX, MIM 300419). XLAG phenotype is caused by mutations with loss of function effect on *ARX* transcriptionally relevant domains: the homeobox domain, which binds DNA and has transcriptional repression activity, and the OAR domain, which has been suggested to collaborate in *ARX* transcriptional activation (Mattiske et al., 2018; Shoubridge, Tan, Seiboth, & Géczy, 2012). A milder phenotype has been recently delineated in females with heterozygous XLAG mutations, with 31 affected carriers reported (Mattiske et al., 2017), which is additionally influenced by skewed X-inactivation, at least in brain (Marsh et al., 2009, 2016). Clinical manifestations mainly include ID and/or developmental delay (around half of the heterozygous female patients), partial or total ACC (around 73% of patients who underwent MRI), epilepsy (around 35%), and movement disorders (hypotonia/dystonia/ataxia, around 26%) (Mattiske et al., 2017). Behavioral disturbances and psychiatric features are also reported, such as autistic behavior, depression and anxiety. The nonsense variant here reported introduces a stop codon in the second exon of *ARX*, producing a hypothetical protein lacking 255 amino acids

and both the homeobox and the OAR domains, presumably causing a complete loss of function effect. Nonsense-mediated mRNA decay (NMD) could not be excluded, even if other reported truncating mutations have been demonstrated to cause a reduced level of transcript and protein (Kato et al., 2004; Moey et al., 2016). To date, the proband displays isolated partial ACC and mild difficulties in fine motor skills and global attention, especially in the expressive language domain. No sign of epilepsy was detected at the time of the last follow-up (4 years and 3 months), but this could not exclude a possible later onset.

In addition to the *ARX* variant, the fetus of the interrupted pregnancy (II:2) carried a *de novo* 17q12 microduplication (1.7Mb; Table S2). This rearrangement includes the 1.4 Mb 17q12 duplication region, which has been associated with an incompletely penetrant contiguous gene syndrome (MIM 614526) characterized by variable features including developmental delay and dysmorphisms. In a few cases, brain MRI evidenced abnormalities such as focal cortical dysplasia, ACC, and periventricular leukomalacia (Mitchell et al., 2015). It could be supposed that the duplication can explain at least in part the phenotype of the fetus and that both the genomic and the *ARX* nonsense mutations could exert a role in the delineation of its severe clinical picture that can be more likely considered as the result of two distinct and concurrent molecular causes (Table S2). Moreover, we cannot exclude that a possible skewed X-inactivation in the fetus could have worsened the effect of the *ARX* variant, as previously demonstrated in *Arx* knockout mouse model (Marsh et al., 2016).

In conclusion, our study describes a phenotype in a female associated with a loss of function variant in *ARX* and suggests the possible role of this variant in a previously interrupted pregnancy, where a concurring *de novo* microduplication predictably contributes to causing a more severe and complex phenotype. This report highlights the importance of investigating additional single-gene mutations potentially contributing to the phenotype when interpreting CNVs with variable penetrance and scarcely recognizable clinical features, even occurring *de novo*. Moreover, this case suggests *ARX* as a potential cause of the disease in female patients with mild neurodevelopmental signs and no seizures. The identification of the *ARX* variant in the interrupted pregnancy, pointing to probable gonadal mosaicism, changed risk recurrence for the couple, with a direct impact on counseling. The introduction of whole genome sequencing in clinical practice, enabling to investigate both point mutations and CNVs in a single experiment, will permit a more efficient and comprehensive identification of molecular bases in cases of genetic and genomic mutations co-inheritance, allowing a more accurate genotype-phenotype correlation.

ACKNOWLEDGMENTS

We thank the family that participated in this study for its valuable effort and cooperation.

CONFLICT OF INTEREST

The authors have no conflict of interest to declare.

AUTHOR'S CONTRIBUTION

A. T. and E. M. contributed to acquisition, analysis and interpretation of data, and drafted the manuscript. M.L. G., N. P., K. M., G. N., and F. P. S. contributed to acquisition and interpretation of data, and critically revised the manuscript. A. D. L. and M. C. contributed to interpretation of data and critically revised the manuscript. F. C., S. B., and L. M. contributed to acquisition and analysis of data and critically revised the manuscript. A. G., F. P., and T.M. contributed to analysis and interpretation of data, and critically revised the manuscript. A.P. and V. C. contributed to conception, design, analysis, interpretation of data, and critically revised the manuscript. All authors approved the final version to be published.

DATA AVAILABILITY STATEMENT

The data that support the findings of this study are available on request from the corresponding author.

ORCID

Katia Margiotti  <https://orcid.org/0000-0003-0432-1525>

Silvia Bernardo  <https://orcid.org/0000-0002-0902-3757>

Viviana Caputo  <https://orcid.org/0000-0001-6753-1234>

REFERENCES

- Allen, R. C., Zoghbi, H. Y., Moseley, A. B., Rosenblatt, H. M., & Belmont, J. W. (1992). Methylation of HpaII and HhaI sites near the polymorphic CAG repeat in the human androgen-receptor gene correlates with X chromosome inactivation. *American Journal of Human Genetics*, *51*(6), 1229–1239.
- Bittel, D. C., Theodoro, M. F., Kibiryeva, N., Fischer, W., Talebizadeh, Z., & Butler, M. G. (2008). Comparison of X-chromosome inactivation patterns in multiple tissues from human females. *Journal of Medical Genetics*, *45*(5), 309–313. <https://doi.org/10.1136/jmg.2007.055244>
- D'Antonio, F., Pagani, G., Familiari, A., Khalil, A., Sagies, T.-L., Malinger, G., ... Prefumo, F. (2016). Outcomes associated with isolated agenesis of the corpus callosum: A meta-analysis. *Pediatrics*, *138*(3), e20160445. <https://doi.org/10.1542/peds.2016-0445>
- Jouan, L., Ouled Amar Bencheikh, B., Daoud, H., Dionne-Laporte, A., Dobrzaniecka, S., Spiegelman, D., ... Rouleau, G. A. (2016). Exome sequencing identifies recessive CDK5RAP2 variants in patients with isolated agenesis of corpus callosum. *European Journal of Human Genetics*, *24*(4), 607–610. <https://doi.org/10.1038/ejhg.2015.156>
- Kato, M., Das, S., Petras, K., Kitamura, K., Morohashi, K.-I., Abuelo, D. N., ... Dobyns, W. B. (2004). Mutations of ARX are associated with striking pleiotropy and consistent genotype-phenotype correlation. *Human Mutation*, *23*(2), 147–159. <https://doi.org/10.1002/humu.10310>
- Kitamura, K., Yanazawa, M., Sugiyama, N., Miura, H., Iizuka-Kogo, A., Kusaka, M., ... Morohashi, K.-I. (2002). Mutation of ARX causes abnormal development of forebrain and testes in mice and X-linked lissencephaly with abnormal genitalia in humans. *Nature Genetics*, *32*(3), 359–369. <https://doi.org/10.1038/ng1009>
- Li, Q., & Wang, K. (2017). InterVar: Clinical interpretation of genetic variants by the 2015 ACMG-AMP guidelines. *American Journal of Human Genetics*, *100*(2), 267–280. <https://doi.org/10.1016/j.ajhg.2017.01.004>
- Marsh, A. P. L., Edwards, T. J., Galea, C., Cooper, H. M., Engle, E. C., Jamuar, S. S., ... Lockhart, P. J. (2018). DCC mutation update: Congenital mirror movements, isolated agenesis of the corpus callosum, and developmental split brain syndrome. *Human Mutation*, *39*(1), 23–39. <https://doi.org/10.1002/humu.23361>
- Marsh, A. P. L., Heron, D., Edwards, T. J., Quartier, A., Galea, C., Nava, C., ... Depienne, C. (2017). Mutations in DCC cause isolated agenesis of the corpus callosum with incomplete penetrance. *Nature Genetics*, *49*(4), 511–514. <https://doi.org/10.1038/ng.3794>
- Marsh, E., Fulp, C., Gomez, E., Nasrallah, I., Minarcik, J., Sudi, J., ... Golden, J. A. (2009). Targeted loss of Arx results in a developmental epilepsy mouse model and recapitulates the human phenotype in heterozygous females. *Brain*, *132*(Pt 6), 1563–1576. <https://doi.org/10.1093/brain/awp107>
- Marsh, E. D., Nasrallah, M. P., Walsh, C., Murray, K. A., Nicole Sunnen, C., McCoy, A., & Golden, J. A. (2016). Developmental interneuron subtype deficits after targeted loss of Arx. *BMC Neuroscience*, *17*(1), 35. <https://doi.org/10.1186/s12868-016-0265-8>
- Mattiske, T., Moey, C., Vissers, L. E., Thorne, N., Georgeson, P., Bakshi, M., & Shoubridge, C. (2017). An emerging female phenotype with loss-of-function mutations in the aristaleless-related homeodomain transcription factor ARX. *Human Mutation*, *38*(5), 548–555. <https://doi.org/10.1002/humu.23190>
- Mattiske, T., Tan, M. H., Dearsley, O., Cloosterman, D., Hii, C. S., Géczy, J., & Shoubridge, C. (2018). Regulating transcriptional activity by phosphorylation: A new mechanism for the ARX homeodomain transcription factor. *PLoS One*, *13*(11), e0206914. <https://doi.org/10.1371/journal.pone.0206914>
- Mitchell, E., Douglas, A., Kjaegaard, S., Callewaert, B., Vanlander, A., Janssens, S., ... Mefford, H. C. (2015). Recurrent duplications of 17q12 associated with variable phenotypes. *American Journal of Medical Genetics Part A*, *167A*(12), 3038–3045. <https://doi.org/10.1002/ajmg.a.37351>
- Moey, C., Topper, S., Karn, M., Johnson, A. K., Das, S., Vidaurre, J., & Shoubridge, C. (2016). Reinitiation of mRNA translation in a patient with X-linked infantile spasms with a protein-truncating variant in ARX. *European Journal of Human Genetics*, *24*(5), 681–689. <https://doi.org/10.1038/ejhg.2015.176>
- Sagi-Dain, L., Kurolap, A., Ilivitzki, A., Mory, A., Paperna, T., Center, R. G., ... Baris Feldman, H. (2020). A novel heterozygous loss-of-function DCC Netrin 1 receptor variant in prenatal agenesis of corpus callosum and review of the literature. *American Journal of Medical Genetics Part A*, *182*(1), 205–212. <https://doi.org/10.1002/ajmg.a.61404>
- Shoubridge, C., Tan, M. H., Seiboth, G., & Géczy, J. (2012). ARX homeodomain mutations abolish DNA binding and lead to a loss

- of transcriptional repression. *Human Molecular Genetics*, 21(7), 1639–1647. <https://doi.org/10.1093/hmg/ddr601>
- Sotiriadis, A., & Makrydimas, G. (2012). Neurodevelopment after prenatal diagnosis of isolated agenesis of the corpus callosum: An integrative review. *American Journal of Obstetrics & Gynecology*, 206(4), 337.e1–337.e5. <https://doi.org/10.1016/j.ajog.2011.12.024>
- Stoll, C., Dott, B., & Roth, M. P. (2019). Associated anomalies in cases with agenesis of the corpus callosum. *American Journal of Medical Genetics Part A*, 179(10), 2101–2111. <https://doi.org/10.1002/ajmg.a.61330>
- van der Meulen, M. A., van der Meulen, M. J., & te Meerman, G. J. (1995). Recurrence risk for germinal mosaics revisited. *Journal of Medical Genetics*, 32(2), 102–104. <https://doi.org/10.1136/jmg.32.2.102>

SUPPORTING INFORMATION

Additional supporting information may be found online in the Supporting Information section.

How to cite this article: TraversaA, Marchionni E, Giovannetti A, et al. Heterozygous nonsense *ARX* mutation in a family highlights the complexity of clinical and molecular diagnosis in case of chromosomal and single gene disorder co-inheritance. *Mol Genet Genomic Med*. 2020;00:e1336. <https://doi.org/10.1002/mgg3.1336>