

## Accepted Manuscript

Title: Elastic intramedullary nailing of the femur fracture in patients affected by osteogenesis imperfecta type 3: Indications, limits and pitfalls

Authors: Pietro Persiani, Lorena Martini, Filippo Maria Ranaldi, Anna Zambrano, Mauro Celli, Luca Celli, Patrizia D'Eufemia, Ciro Villani



PII: S0020-1383(19)30045-2  
DOI: <https://doi.org/10.1016/j.injury.2019.01.045>  
Reference: JINJ 8045

To appear in: *Injury, Int. J. Care Injured*

Please cite this article as: Persiani P, Martini L, Ranaldi FM, Zambrano A, Celli M, Celli L, D'Eufemia P, Villani C, Elastic intramedullary nailing of the femur fracture in patients affected by osteogenesis imperfecta type 3: Indications, limits and pitfalls, *Injury* (2019), <https://doi.org/10.1016/j.injury.2019.01.045>

This is a PDF file of an unedited manuscript that has been accepted for publication. As a service to our customers we are providing this early version of the manuscript. The manuscript will undergo copyediting, typesetting, and review of the resulting proof before it is published in its final form. Please note that during the production process errors may be discovered which could affect the content, and all legal disclaimers that apply to the journal pertain.

# ELASTIC INTRAMEDULLARY NAILING OF THE FEMUR FRACTURE IN PATIENTS AFFECTED BY OSTEOGENESIS IMPERFECTA TYPE 3: INDICATIONS, LIMITS AND PITFALLS

Pietro Persiani, MD 1

Lorena Martini ,MD 1

Filippo Maria Ranaldi, MD 1

Anna Zambrano, MD 2

Mauro Celli, MD 2

Luca Celli, MS 2

Patrizia D'Eufemia, MD 2

Ciro Villani, MD 1

<sup>1</sup> Department Of Anatomical, Histological, Forensic Medicine And Orthopaedic Science, Sapienza University Of Rome; Department Of Orthopaedics And Traumatology - Policlinico Umberto I Rome Italy

<sup>2</sup> Centre for Congenital Osteodystrophies, Sapienza University Of Rome; Paediatric Department - Policlinico Umberto I Rome Italy

## CORRESPONDING AUTHOR:

**Pietro Persiani**, Department Of Anatomical, Histological, Forensic Medicine And Orthopaedic Science, Sapienza University Of Rome

Piazzale Aldo Moro, 5 - 00185 Roma

Tel. +39 335497510

Mail. [ppersiani@me.com](mailto:ppersiani@me.com)

## ABSTRACT

**INTRODUCTION.** Patients with Osteogenesis Imperfecta (OI) Type 3 may exhibit both primitive deformities and secondary fracture malunions on a femoral level. The orthopaedic surgeon's objective is to cure the deformities in order to prevent

fractures and to treat the fractures in order to prevent deformities, by using telescopic nails as the gold standard method of fixation. However, the titanium elastic nail (TEN) is indicated as a possible alternative in certain selected cases.

**MATERIALS AND METHODS.** The Centre for Congenital Osteodystrophy of the Sapienza University of Rome follows 485 patients with osteogenesis imperfecta. For the purpose of this study, we selected 36 patients with OI type 3 (15 females and 21 males), aged between 2 and 10 years old, who were surgically treated for femur fractures with Titanium Elastic Nail (TEN) from January 2007 to December 2009. In 12 cases a single TEN was implanted, while 24 of the cases were treated by implanting 2 TENs with the Sliding Nail (SN) technique. A retrospective evaluation was carried out by analysing the data from the medical charts and dossiers related to pain symptoms, knee and hip Range of Motion (ROM), any possible complications that could cause implant revisions (infections, nail slide failure, nail migration, traumatic events following surgery, delayed consolidation, epiphysiodesis).

**RESULTS.** At the 60<sup>th</sup> post-surgical month, the revision rate was 75%, mostly due to migration, osteolysis, nail slide failure and nail fracture. The Kaplan-Meier's survival curve analysis showed a coefficient of 0.25 to 60 months (confidence interval -0.31 and 0.81).

**DISCUSSION.** The percentage of complications and the high rate of revisions recorded in our sample confirm that telescopic nail is the gold standard in the treatment of femoral fractures in patients with OI type 3.

**CONCLUSIONS.** In patients under the age of 4, with narrow medullary canals, low life expectancy, few to nil rehabilitative prospectives or severe comorbidities, the use of TEN may be considered as a less invasive approach compared to telescopic nail surgery, however only temporarily, as it will still most probably require a surgical revision a few years down the line.

**Keywords:** osteogenesis imperfecta, femoral fractures, elastic nailing, indications, limits, pitfalls

## INTRODUCTION

Osteogenesis Imperfecta (OI) is a rare congenital pathology of the connective tissue in which, the osteoblast produces a qualitatively and/or quantitatively abnormal bone matrix, causes an increase in bone remodelling, a decrease in bone mineral density and a consequent distinctive fragility<sup>[1-2]</sup>. The disease is also characterised by a heterogeneous phenotypic expression with associated low stature, hypoacusis, blue sclera, dentinogenesis imperfecta, hyperlaxity and cardiac alterations.<sup>[3-4-5]</sup> According to the classification of Silience and Glorieux<sup>[6-7-8]</sup>, there are currently 7 types of OI.

The long bones of the lower limbs in patients with OI often have deformities that develop as a result of bone deformability or of malunion fractures. A fracture may occur at the apex of deformities, which reinforces a vicious circle in which deformations cause new fractures, which in turn aggravate the deformity. The orthopaedic surgeon's objective is to cure the deformities in order to prevent fractures and to treat the fractures in order to prevent deformities<sup>[9-10-11]</sup>

The pharmacological therapy is based on the use of bisphosphonates<sup>[12-13]</sup>, the growth hormone (GH)<sup>[14]</sup>, the teriparatide<sup>[15-16]</sup>, a recombinant parathyroid hormone, and the denosumab, a monoclonal antibody that blocks the receptor activator of nuclear factor kappa-b ligand<sup>[17]</sup>, which have shown an increase in bone mineral density and a reduction in the number of fractures and pain.

The surgical treatment should take into consideration the quality of bone, the presence of deformities, the presence of concomitant pathologies (which complicate the anaesthesiologic aspect), the bone modifications induced by bisphosphonate therapy (such as an increased cortical thickness and a narrow and often decentralised medullary canal).

Plates and screws are not indicated as the reduced bone quality results in an early mobilisation of osteosynthesis and an osteolysis with the risk a fracture on the plate<sup>[18-19]</sup>. Particularly, in OI types VI and V, the use of plates has been associated with the formation of a hypertrophic callus<sup>[20-21]</sup>.

The gold standard is the telescopic intramedullary nail consisting of two components (male and female) that, anchored to the epiphyses, slides and extends as the bone grows<sup>[22-23-24-25]</sup>.

In cases of canals with very small diameter, patients of very young age or in generally critical conditions, the choice of the means of osteosynthesis falls on small

diameter non-telescopic nails (Rush nails or titanium elastic nails) <sup>[26-27-28]</sup>. [Figure 1A]

With the *sliding nails (SN)* technique, it is possible to obtain the same result as with the telescopic nails, by fastening the device to the epiphyses, thus allowing them to extend in the medullary canal as the bone grows<sup>[29-30-31]</sup>. [Figure 1B]

## **MATERIALS AND METHODS**

The Centre for Congenital Osteodystrophy of the Sapienza University of Rome follows 485 patients with osteogenesis imperfecta. For the purpose of this study, we selected 36 patients with OI type 3 (15 females and 21 males), aged between 2 and 10 years old (average age 7 years old), who were surgically treated for femur fractures with TEN osteosynthesis from January 2007 to December 2009. The follow-up was of 5 years (60 months).

Depending on the age of the patient and the diameter of the medullary canal <sup>[27]</sup>, 24 patients underwent osteosynthesis with 2 TEN's with the sliding nail technique and 12 patients underwent osteosynthesis with one TEN.

At the moment of the fracture, all the patients had been undergoing treatment with Neridronate (dosage 2mg per Kg i.v. every 3 months) for at least 1 year. This treatment was suspended for the 4 months following the surgery in order to avoid delays in consolidation or pseudoarthrosis <sup>[32]</sup>.

After the surgery, all the patients received pain therapy for 5 days with paracetamol (children weighing <25 kg: 250mg x3 per day; children weighing >25 Kg: 500 x3 per day) and an antibiotic prophylaxis with amoxicillin and clavulanic acid for 7 days, (25 mg/3.6 mg oral suspension per kg of bodyweight x2 per day ).

Post-operatively, all the patients were immobilised in a hip-spica cast. After 3 weeks, once the cast was removed, the patients began the joint recovery rehabilitation protocol, both in and out of water. Starting from the fourth week partial load bearing and walking re-education was granted.

The analysis of the clinical records produced data regarding the following issues: pain symptomology, hip/knee ROM, any possible complications that could cause implant revisions (infections, nail slide failure, nail migration, post-surgical traumatic events), delays in consolidation and epiphysiodesis.

Radiological follow up evaluations were performed at 21-days, 2 months, 6 months, a year and subsequently every year for 5 years (60 months).

Ethical approval: All the procedures performed in the study involving human participants were in accordance with the ethical standards of the institutional and/or national research committee and with the 1964 Helsinki Declaration and its subsequent amendments or comparable ethical standards. Informed consent was obtained from all the individual participants included in the study.

## RESULTS

Pain management therapy was needed, on average, for the first 3 days after surgery. No pain was recorded in 70% of patients around 5 weeks after surgery.

The analysis of clinical records showed that a 90° knee and hip ROM was reached within 5 weeks in all the patients treated with 1 TEN nail and in 16 of the 24 patients treated with 2 TEN nails.

No infectious complications were reported.

The **non-traumatic migration of the nail** occurred on an average at 2 months in 1 patients treated with 1 TEN and 6 patients treated with 2 TENs (all of which were due to the retrogradely inserted distal nail).

One consolidation **delays** were reported in 1 patients treated with 1 TEN.

A new fracture, on average 2 years after surgery (6 to 29 months), was reported in 21 patients (18 patients from low energy traumas and 3 from car accidents).

In 11 patients treated with 2 TENs, the presence of the nails initially prevented the displacement of new fracture, though subsequently, 6 months later, in 6 of the cases the TEN stopped sliding.

In 10 patients (7 treated with 1 TEN and 3 treated with 2 TEN's), the fracture resulted in a femoral displacement associated with the deformation of the nails, thus a surgical revision was required. [Figure 2]

Another complication was cortical **osteolysis** in 3 cases treated with 2 TEN's with the device mobilisation at 24 months, all subsequently revised with telescopic nails. [Figure 3]

Finally, 2 patients treated with 2 TEN's presented a knee **epiphysiodesis** with a valgus deviation of 10 ° at 3 years after surgery.

At the end of the follow-up (60 months), we analysed the surgical revision rate and the results showed it was 75%, whether the patients were treated with 1 or 2 TENs nails [Table 1].

In the cases treated with 1 TEN, the revisions were due to 1 case of migration, 1 case of consolidation delay and 7 cases of post-traumatic fracture displacement on the nail.

In the cases treated with 2 TENs, the revisions were due to 6 cases of migration, 3 cases of post-traumatic fracture displacement on the nail, 4 cases of nail slide failure, 3 cases for osteolysis and 2 cases for epiphysiodesis. [Figure 4]

The TEN/age ratio showed that the highest percentage of complications occurred in patients treated with 1 TEN who were older than 5 years of age and patients treated with 2 TENs who were less than 5 years of age.

The Kaplan-Meier analysis curve [Table 2] showed a survival coefficient of 0.25 (with confidence intervals of -0.31 and 0.81) at 60 months.

## DISCUSSION

The surgical treatment of femoral fractures in patients with OI type 3 consists of intramedullary osteosynthesis with non telescoping rods (K-wires, Rush or TEN) or telescopic rods (DB or FD). Although telescopic nails are recognised as the gold standard device<sup>[22-23]</sup>, the use of TEN nails is indicated for younger patients, with very small canals, severe malformations, or major comorbidities that can affect surgical management.<sup>[33]</sup>

In our series, the rate of complications with TEN, single and double with sliding nail technique, was higher than that described, in literature, for telescopic nails.<sup>[34-35-36]</sup>

In cases of subsequent fractures, the femurs treated with 1 TEN were unable to maintain the alignment of the stumps due to the poor stability of the osteosynthesis, resulting in a displacement, while in the femurs treated with 2 TEN's, a non-deformable alignment was maintained due to the more stable assembly resulting from the SN technique. Nonetheless, 36% of these patients underwent revisions due to nail slide failure 6 months after the new fracture.

The osteolysis and TEN migrations observed in our series are probably attributable to the modulus of elasticity of the nails and, thus, to the tension on the corticals, despite the correct pre-tensioning of the means of nail.

With to regard to cases of consolidation delay, these may be correlated to the use of bisphosphonates (which were suspended in all patients, but still presented time-delayed effects)<sup>[35]</sup> and the intrinsic elasticity of the means of osteosynthesis <sup>[33-38]</sup>.

Lastly, the cases of epiphysiodesis and axial deviations are to be attributed to the need to have the nail enter obliquely, thus crossing the nucleus of epiphysial growth, in order for it to become anchored and allow subsequent sliding. This complication is rarely reported in literature when using telescopic nails, as the means of osteosynthesis crosses the physis perpendicularly. <sup>[39-40-41-42]</sup>

## CONCLUSIONS

In our series, the patients with the highest complication rate were those older than 5 years of age treated with 1 TEN and those under 5 years of age treated with 2 TEN's. Considering the high percentage of complications and the device revision rate, we believe that the choice for the means of osteosynthesis should fall on the telescopic nail for patients older than 5 years of age and with a sufficiently wide medullary canal diameter (the minimum diameter of the telescopic nail is 3.2mm and minimum diameter of a single TEN is 1.5mm). The TEN's should be indicated as a temporary approach, always considering possible future revision, only in cases where the patient is less than 4 years of age with a very narrow medullary canal.



## REFERENCES

1. Glorieux F.H. A disease of the osteoblast. *Lancet* 2001;suppl.358:s45.
2. Dalgleish R. The human type I collagen mutation database. *Nucleic acids Res* 1998; 26:253-5.
3. Rauch F, Glorieux FH. Osteogenesis Imperfecta. *Lancet*.2004;363:1377-85.
4. Sillence Do, Senn A, Danks Dm. Genetic Heterogeneity In Osteogenesis Imperfecta. *J Med Genet.* 1979;16:101-16.
5. Sillence D. Osteogenesis imperfecta: an expanding panorama of variants. *Clin Orthop Relat Res.* 1981 Sep;(159):11-25.
6. Glorieux FH, Rauch F, Plotkin H, Ward L, Travers R, Roughley P et al. Type V osteogenesis imperfecta: a new form of brittle bone disease. *J Bone Miner Res.* 2000 Sep;15(9):1650-8.
7. Glorieux FH, Ward LM, Rauch F, Lalic L, Roughley PJ, Travers R. Osteogenesis imperfecta type VI: a form of brittle bone disease with a mineralization defect. *J Bone Miner Res.* 2002 Jan;17(1):30-8.
8. Ward LM, Rauch F, Travers R, Chabot G, Azouz EM, Lalic L et al. Osteogenesis imperfecta type VII: an autosomal recessive form of brittle bone disease. *Bone.* 2002 Jul;31(1):12-8.
9. Villani C, Martini L, Di Domenica M, Ranaldi FM, Zambrano A, Celli M et al. Management of long bones fractures and deformities of lower extremities in patients with osteogenesis imperfecta type I, III AND IV. *Giot* 2014; 40(suppl.3): S115-S124.
10. Sinikumpu JJ, Ojaniemi M, Lehenkari P, Serlo W. Severe osteogenesis imperfecta Type-III and its challenging treatment in newborn and preschool children. A systematic review. *Injury.* 2015 Aug;46(8):1440-6.
11. Azzam KA, Rush ET, Burke BR, Nabower AM, Esposito PW. Mid-term Results of Femoral and Tibial Osteotomies and Fassier-Duval Nailing in Children With Osteogenesis Imperfecta.. *J Pediatr Orthop.* 2016 Jul 2.
12. Rauch F, Plotkin H, Zeitlin L. Bone mass, size and density in children and adolescents with osteogenesis imperfecta. Effect of intravenous pamidronate therapy. *J Bone Miner Res* 2003,18:610-4.
13. Antoniazzi F, Prizzi R, Braga V, Rossini M, Tatò L, Viapiana O et al. Intravenous neridronate in children with osteogenesis imperfecta: a randomized controlled study. *J Bone Miner Res.* 2005 May;20(5):758-63. Epub 2004 Dec 20
14. Antoniazzi F, Monti E, Venturi G, Franceschi R, Doro F, Gatti D et al. GH in combination with bisphosphonate treatment in osteogenesis imperfecta. *Eur J Endocrinol.* 2010 Sep;163(3):479-87. Epub 2010 Jun 30.
15. Orwoll ES, Shapiro J, Veith S et al. Evaluation of teriparatide treatment in adults with osteogenesis imperfecta. *J Clin Invest* 2014;124(2):491-498.
16. Gatti D, Rossini M, Viapiana O et al. Teriparatide treatment in adult patients with osteogenesis imperfecta type I. *Calcif Tissue Int* 2013;93(5):448-452.
17. Hoyer-Kuhn H, Netzer C, Koerber F, Schoenau E, Semler O. Two years' experience with denosumab for children with osteogenesis imperfecta type VI. *Orphanet J Rare Dis* 2014;9:145.
18. Enright WJ, Noonan KJ. Bone plating in patients with type III osteogenesis imperfecta: results and complications. *Iowa Orthop J.* 2006;26:37-40
19. Fassier F, Glorieux FH. Osteogenesis imperfecta. Surgical techniques in orthopaedics and traumatology. Paris: Elsevier; 2003
20. Brizola E, Mattos EP, Ferrari J, Freire PO, Germer R, Llerena JC Jr et al. Clinical and

- Molecular Characterization of Osteogenesis Imperfecta Type V. *Mol Syndromol*. 2015 Oct;6(4):164-72
21. Cheung MS, Glorieux FH, Rauch F. Natural history of hyperplastic callus formation in osteogenesis imperfecta type V. - *J Bone Miner Res*. 2007 Aug;22(8):1181-6
  22. Birke O, Davies N, Latimer M, Little DG, Bellemore M. Experience with the Fassier-Duval telescopic rod: first 24 consecutive cases with a minimum of 1-year follow-up. *J Pediatr Orthop*. 2011 Jun;31(4):458-64
  23. Sterian A, Balanescu R, Barbilian A, Ulici A. Osteosynthesis in Osteogenesis Imperfecta, telescopic versus non-telescopic nailing. *J Med Life*. 2015 Oct-Dec;8(4):563-5.
  24. Bălănescu R1, Ulici A, Rosca D, Topor L, Barbu M. Use of minimally invasive (percutaneous) Fassier-Duval telescopic rod on an 8 year old patient with Lobstein disease. *Chirurgia (Bucur)*. 2013 Jan-Feb;108(1):120-5.
  25. Mazen Abulsaad, Ashraf Abdelrahman. Modified Sofield-Millar operation: less invasive surgery of lower limbs in osteogenesis imperfecta. *International Orthopaedics (SICOT)* (2009) 33:527–532
  26. Joseph B, Rebello G, B CK. The choice of intramedullary devices for the femur and the tibia in osteogenesis imperfecta. *J Pediatr Orthop B*. 2005 Sep;14(5):311-9.
  27. Luhmann SJ, Sheridan JJ, Capelli AM, Schoenecker PL. Management of lower-extremity deformities in osteogenesis imperfecta with extensible intramedullary rod technique: a 20-year experience. *J Pediatr Orthop*. 1998 Jan-Feb;18(1):88-94.
  28. Gamal El-Adl, Mohamed A. Khalil, Ahmed Enan, Mohamed F. Mostafa, Mohamed R. El-Lakkany. Telescoping versus non-telescoping rods in the treatment of osteogenesis imperfecta. *Acta Orthopædica Belgica*, Vol. 75 - 2 - 2009
  29. Boutaud B, Laville JM. Elastic sliding central medullary nailing with osteogenesis imperfecta. Fourteen cases at eight years follow-up. *Rev Chir Orthop Reparatrice Appar Mot*. 2004 Jun;90(4):304-11.
  30. Yukari Imajima, Motohiro Kitano, Takafumi Ueda. Intramedullary Fixation Using Kirschner Wires in Children With Osteogenesis Imperfecta. *J Pediatr Orthop Vol 35*, Number 4, June 2015
  31. Mingazov ER, Popkov AV, Kononovich NA, Aranovich AM, Popkov DA. Results of using transphyseal elastic intramedullary nailing in patients with severe types of osteogenesis imperfecta. *The Ilizarov Journal of Clinical and Experimental Orthopaedics*, 2016. УДК 616.71-007.235-001.5-089.227.84
  32. Munns CF, Rauch F, Zeitlin L, Fassier F, Glorieux FH. Delayed osteotomy but not fracture healing in pediatric osteogenesis imperfecta patients receiving pamidronate. *J Bone Miner Res*. 2004 Nov;19(11):1779-86. Epub 2004 Aug 23
  33. Duparc J, Allieu Y et al. Ostéogénèse imparfaite. Indications thérapeutiques chez l'enfant. *Cahiers d'enseignement de la SOFCOT n° 31*, Expansion Scientifique Francaise, Paris, 1988, 377-345
  34. Boutaud B, Laville JM. Elastic sliding central medullary nailing with osteogenesis imperfecta. Fourteen cases at eight years follow-up. *Rev Chir Orthop Reparatrice Appar Mot*. 2004 Jun;90(4):304-11.
  35. El-Adl G, Khalil MA, Enan A, Mostafa MF, El-Lakkany MR. Telescoping versus non-telescoping rods in the treatment of osteogenesis imperfecta. *Acta Orthop Belg*. 2009 Apr;75(2):200-8.
  36. Sterian A, Balanescu R, Barbilian A, Tevanov I, Carp M, Nahoi C et al. Early telescopic rod osteosynthesis for Osteogenesis Imperfecta patients. *J Med Life*. 2015 Oct-Dec;8(4):544-7
  37. Birke O, Davies N, Latimer M, Little DG, Bellemore M. Experience with the Fassier-Duval telescopic rod: first 24 consecutive cases with a minimum of 1-year follow-up. *J*

- Pediatr Orthop. 2011 Jun;31(4):458-64.
38. Glorieux FH. Osteogenesis imperfecta. Best Pract Res Clin Rheumatol. 2008 Mar; 22(1):85-100.
  39. Bailey RW, Dubow HI. Evolution of the concept of an extensible nail accomodating to normal longitudinal bone growth: clinical considerations and implications. General Orthopaedics section II
  40. Cole WG, Chan D, Chow CW, Rogers JG. Disrupted growth plates and progressive deformities in osteogenesis imperfecta as a result of the substitution of glycine 585 by valine in the alpha 2 (I) chain of type I collagen. J Med Genet. 1996 Nov;33(11):968-71.
  41. Wei-Chun Li, Hsuan-Kai Kao, Wen-E Yang, Chee-Jen Chang, Chia-Hsieh Chang. Femoral Non elongating Rodding in Osteogenesis Imperfecta – The Importance of Purchasing Epiphyseal Plate. Biomed J Vol. 38 No. 2 March - April 2015
  42. Wei-Chun Li, Hsuan-Kai Kao, Wen-E Yang, Chee-Jen Chang, Chia-Hsieh Chang. Femoral Non-elongating Rodding in Osteogenesis Imperfecta The Importance of Purchasing Epiphyseal Plate. Biomed J Vol. 37 No. 4 July - August 2014

## FIGURES LEGEND

FIGURE 1A: femur nailing by 1 TEN nail

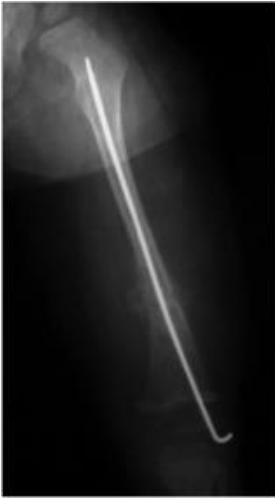

FIGURE 1B: femur nailing by sliding nail technique using 2 TEN nails

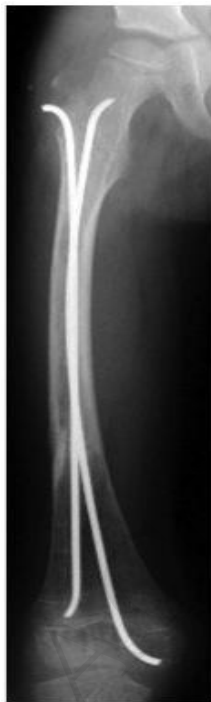

FIGURE 2: case of post trauma displacement fracture and nail bending

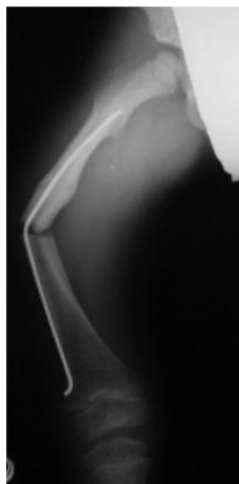


FIGURE 3: case of osteolysis

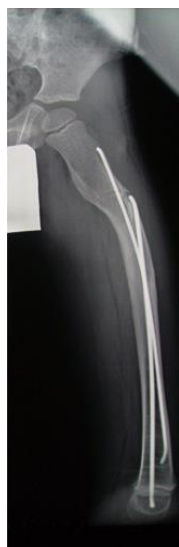
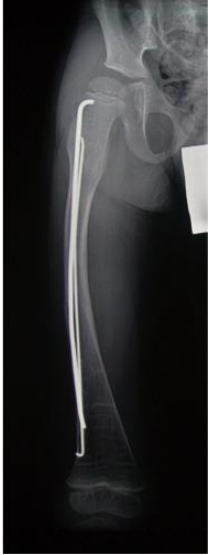
FIGURE 4: case of nails slide failure



ACCEPTED MANUSCRIPT

**Table 1: cause of revisions**

	Patients	Revisions	Migrations	Consolidation Delays	Displacement	NAIL SLIDE Failure	Osteolysis	Epiphysiodesis
<b>2 TEN</b>	24	<b>18</b>	6	0	3 (14 FR)	4	3	2
<b>1 TEN</b>	12	<b>9</b>	1	1	7 (7 FR)	0	0	0
<b>Total</b>	36	<b>27 (75%)</b>	7	1	10	4	3	2

**Table 2: Kaplan-Meier analysis curve: data table and graphic view of survival coefficient of nails**

Months	Revisions	n of patients	Fraction (probability) of survival	Inferior Confidence Interval	Superior Confidence Interval
0	0	36	1	1	1
6	6	30	0.8333333333	0.687243559	0.979423108
12	2	28	0.7777777778	0.6031671	0.952388456
18	1	27	0.75	0.561398912	0.938601088
24	7	20	0.5555555556	0.263376006	0.847735105
30	3	17	0.4722222222	0.126874051	0.817570394
36	4	13	0.3611111111	- 0.073396174	0.795618397
42	3	10	0.2777777778	- 0.248956395	0.804511951
48	1	9	0.25	- 0.315803264	0.815803264
54	0	9	0.25	- 0.315803264	0.815803264
60	0	9	0.25	- 0.315803264	0.815803264