







REVIEW ARTICLE

Clinical presentation, diagnosis and staging of cholangiocarcinoma

Alejandro Forner^{1*}  | Gianpaolo Vidili^{2*}  | Marco Rengo³  | Luis Bujanda⁴  |
Mariano Ponz-Sarvisé⁵  | Angela Lamarca^{6,7} 

¹Liver Unit, Barcelona Clinic Liver Cancer Group, Hospital Clínic Barcelona, August Pi i Sunyer Biomedical Research Institute, CIBERehd, University of Barcelona, Barcelona, Spain

²Department of Medical, Surgical and Experimental Sciences, University of Sassari, Sassari, Italy

³Academic Diagnostic Imaging Division - I.C.O.T. Hospital, University of Rome "Sapienza", Latina, Italy

⁴Department of Gastroenterology, Hospital Donostia/Instituto Biodonostia. Centro de Investigación Biomédica en Red de Enfermedades Hepáticas y Digestivas (CIBERehd), Universidad del País Vasco (UPV/EHU), San Sebastian, Spain

⁵Gastrointestinal Oncology Unit, Clínica Universidad de Navarra, Programa Tumores Sólidos y biomarcadores, CIMA, Universidad de Navarra, Pamplona, Spain

⁶Department of Medical Oncology, The Christie NHS Foundation Trust, Manchester, UK

⁷Division of Cancer Sciences, School of Medical Sciences, Faculty of Biology, Medicine and Health, University of Manchester, Manchester, UK

Correspondence

Angela Lamarca, Department of Medical Oncology, The Christie NHS Foundation Trust/Division of Cancer Sciences, University of Manchester, Manchester, UK.
Email: angela.lamarca@christie.nhs.uk

Funding information

Angela Lamarca received funding from the American Society of Clinical Oncology (ASCO) Conquer Cancer Foundation Young Investigator Award, The Cholangiocarcinoma Foundation Fellowship and The Christie Charity.; The authors of this review article are members of the European Network for the Study of Cholangiocarcinoma (ENS-CCA) and participate in the initiative COST Action EURO-CHOLANGIO-NET granted by the COST Association (CA18122), Grant/Award Number: COST-CA18122

Abstract

Cholangiocarcinoma (CCA) is a heterogeneous group of tumours, derived from cells of the biliary tree, which represent the second most frequent primary liver tumour. According to the most recent classifications, CCA can be subdivided into intrahepatic (iCCA) and extrahepatic (eCCA) which include perihilar (pCCA) and distal (dCCA) CCA. CCA are usually identified at advanced stages, when the primary tumour grows enough to produce a large liver mass or when jaundice has developed because of biliary tree obstruction. The ongoing challenges in the identification of risk factors and definition of a specific population at higher risk of developing CCA are the main challenges for the development of screening programs. Therefore, late diagnosis remains an unresolved issue in CCA. Imaging plays an important role in the detection and characterization of CCA, helping with radiological diagnosis, guiding biopsy procedures and allowing staging of the tumour. This review focuses on clinical presentations and diagnosis and staging techniques of CCA.

KEYWORDS

cholangiocarcinoma, clinical presentation, diagnosis, jaundice, staging

Abbreviations: ¹⁸F-FDG-PET, 18F-fluorodeoxyglucose positron emission tomography; ADC, apparent diffusion coefficient; AJCC, American Joint Committee on Cancer; ARC, American College of Radiology; CCA, cholangiocarcinoma; Ce-CT, contrast enhanced computed tomography; Ce-MRI, contrast enhanced magnetic resonance imaging; CEUS, contrast enhanced ultrasound; dCCA, distal cholangiocarcinoma; DFS, disease-free survival; DWI, diffusion weighted imaging; eCCA, extrahepatic cholangiocarcinoma; EUS, endoscopic ultrasound; GGT, gamma-glutamyl transpeptidase; HCC, hepatocellular carcinoma; iCCA, intrahepatic cholangiocarcinoma; IVIM, intravoxel incoherent motion; LI-RADS, Liver Imaging Reporting Data System; LI-RADS-CEUS, Liver Imaging Reporting Data System for contrast enhanced ultrasound; M, distant metastases; MRCP, MRI cholangiopancreatography; N, regional lymph node infiltration; OS, overall survival; pCCA, perihilar cholangiocarcinoma; PSC, primary sclerosing cholangitis; T, primary tumour.

*Alejandro Forner and Gianpaolo Vidili contributed equally to this work.

1 | INTRODUCTION

Cholangiocarcinoma (CCA) is considered as a heterogeneous group of tumours derived from bile ducts cells. CCA represents the second most frequent malignant liver cancer.¹ Its incidence is globally increasing around the world with 2.1 per 100 000 person per year in Western Countries, reaching higher peaks in the Eastern world, especially in north-west Thailand. CCA is nowadays classified according to the anatomical origin of the lesion and subdivided into intrahepatic cholangiocarcinoma (iCCA) (tumour lesion developed in the liver) and extrahepatic cholangiocarcinoma (eCCA) which includes perihilar (pCCA) and distal subtypes (dCCA).²

In contrast to hepatocellular carcinoma (HCC) which arises in the background of liver cirrhosis; the liver background in which CCA develops encompasses predominantly normal liver. There are, however, occasions where CCA may develop on a background of underlying liver diseases such as primary sclerosing cholangitis (PSC). The pathogenesis of CCA is likely the consequence of a multifactorial process in which host genetics together with environmental factors play a role in the development of this type of tumour. Several risk factors, associated with chronic biliary inflammation and increased cellular turnover, have been linked to higher risk of development of CCA. Cirrhosis, chronic hepatitis B and C, obesity, diabetes and alcohol excess are mainly associated with the development of iCCA. In Asian countries other risk factors involved in CCA include parasitic infection by hepatobiliary flukes (*Opisthorchis viverrini* and *Clonorchis sinensis*), choledochal cystic diseases, such as Caroli's disease and also hepatolithiasis. PSC mainly leads to the development of eCCA.² Other novel risk factors suspected to be involved in the development of CCA are nitrosamine-contaminated food, asbestosis, dioxins and vinyl chlorides.¹

The diagnosis of CCA is based on the combination of clinical and imaging findings which will raise the suspicion of CCA diagnosis. Radiological diagnosis relies mainly on contrast-enhanced ultrasound (CEUS), contrast-enhanced computed tomography (ce-CT) and contrast-enhanced magnetic resonance imaging (ce-MRI). In addition to radiological diagnosis, biopsy/cytology is required in order to get histology confirmation of CCA. Adequate imaging (US/CT) is of huge importance for this step, since it guides the cytology/biopsy-sample acquisition.

Once the diagnosis of CCA is confirmed, staging investigations will assess the degree of extension of tumour outside the liver and the biliary tree. Staging relies, once again, on radiology, mainly ce-CT, but also MRI and ¹⁸F-fluorodeoxyglucose positron emission tomography (¹⁸FDG-PET).³

This review will focus on the clinical presentation of CCA, and will also summarise diagnostic strategies, the role of imaging and the staging process of CCA. All these steps are the cornerstone of adequate treatment planning and thus of huge significance.

2 | CLINICAL PRESENTATION

The most characteristic and common symptom of eCCA is jaundice. In the case of iCCA, jaundice is the initial symptom only in around

Key points

- CCA is usually identified at advanced stages.
- Screening for CCA remains challenging since population at risk is poorly defined.
- Imaging plays an important role in the detection and characterization of CCA.
- Staging of CCA relies on imaging and pathology.
- Staging may require adjustments once natural behaviour of CCA is better understood.

10%-15% of the cases, when biliary obstruction would mainly be related to obstruction of the liver hilum by lymph nodes or migration of detritus and subsequent failure of the correct drainage of the biliary ducts.^{4,5} Diagnosis of iCCA represents an incidental finding in around 20%-25% of patients, especially in early stages,⁶ although in some surgical series, it can be as many as 30%-50% of patients.^{4,5} When CCA patients present with symptoms others than jaundice, they most frequently include abdominal pain, malaise, night sweats, asthenia, nausea and weight loss. The alteration in liver function tests is also a common initial finding in CCA patients, which usually triggers further investigations. Deranged liver function is not specific as it can also be found in a wide range of both benign (hepatitis, PSC) and malignant (HCC) liver diseases.

2.1 | Jaundice, acholia and pruritus: rationale, pathophysiology and differential diagnosis

As stated above, the most common clinical presentation of CCA is jaundice. Jaundice constitutes a common symptom of hepatobiliary diseases that is characterized by the yellowish or greenish pigmentation of the skin and the mucous membranes. About 55% of jaundice cases are related to intrahepatic complications while 45% relates to extrahepatic problems.⁷ Jaundice is clearly detected when the plasma concentration of bilirubin is greater than 2 mg/dL (34 μmol/L). When the bilirubin level is not as high, it may not be visible in the skin and may be better identified by examining the palate and the sclera.

It is important to note that the increase in bilirubin levels may be because of an increase in the unconjugated fraction, the conjugated fraction or both.

Unconjugated bilirubin is fat-soluble, so it deposits within the skin and mucous membranes, but cannot be filtered by the kidney. For this reason, when its plasma concentration is elevated, choluria is not observed. If the elevation is mainly because of an increase in conjugated, water-soluble bilirubin, or has a mixed component, the biliary pigments are eliminated in the urine, giving a dark or black coloration, as in extrahepatic CCA.⁸ Differential diagnosis should include the ingestion of certain foods (oranges, carrots, tomatoes, fava beans, rhubarb or aloe), pigments and medications (antimalarial drugs [chloroquine and primaquine], antibiotics [metronidazole and

nitrofurantoin], laxatives containing cascara or senna and methocarbamol) which can change the colour of the urine.⁹ In addition, muscle injury from extreme exercise can result in kidney injury and produce a dark, brown or pink urine colour. Diseases such as kidney failure or Addison's disease can also trigger a yellowish tone to the skin. However, yellow pigmentation of the sclera is not found in any of these situations.

Conjugated bilirubin does not pass into the duodenum and the bile pigments do not mix with food. Consequently the faeces are white or white-yellowish, producing stools without colour (acholic) or with little colour (pale stools). When abnormal cell growth occurs within the bile ducts (ie CCA), causing biliary tract obstruction, there is an increase in the conjugated bilirubin which will trigger the presence of acholia/pale stools. On the contrary, when the cause of jaundice is intrahepatic (ie hepatocellular damage), acholia does not usually develop, with the exception of the first weeks of acute hepatitis.⁹

There are a variety of diseases during which jaundice, dark urine and acholia may be evident. The most frequent is choledocholithiasis, which implies a mandatory differential diagnosis with CCA.¹⁰ In these cases, it can be associated with an abrupt course, with abdominal pain and fever. On the other hand, when the onset of jaundice is more progressive, associated with a constitutional syndrome (anorexia, weight loss, asthenia) and in the absence of abdominal pain, tumoural processes should be considered first, especially if the patient is above 50 years old. Other less common causes of impaired biliary drainage are parasitic infection, PSC, biliary cysts, duodenal diverticula, haemobilia or, in certain cases, pancreatitis. Other malignancies with similar clinical presentation include pancreatic and ampullary malignancies.

Pruritus is common in cholestatic diseases, although it may also be present in liver diseases with predominantly hepatocellular involvement.¹⁰ Pruritus is a skin sensation that triggers an active scratching motor response. Specialized C-type nerve fibres, keratinocytes and several mediators that stimulate the nerve fibres are among the factors involved in this process. Different systemic diseases are associated with pruritus, and each of them has different mechanisms that explain its origin. Some possible mediators or triggers for pruritus include: bile salts, histamine, serotonin, steroids, endogenous opioids or lysophosphatidic acid.¹¹⁻¹³ There is no correlation between the concentration of salts and the severity of pruritus. Although in most cases it is associated with jaundice, it can also occur in its absence. In 25% of patients with cholestasis, pruritus is the first symptom.¹² The itch is often worse at night and can cause severe sleep deprivation and secondary lassitude, fatigue, depression and suicidal ideation. It is frequently widespread and involves palms and soles of the feet in a characteristic way.

2.2 | Initial investigations

In the presence of the above-mentioned symptoms, it is important to perform a careful physical examination, in which the existence of jaundice should be looked for in both skin and mucous membranes. At this point, signs of a chronic hepatic dysfunction such as the

presence of hepatomegaly, splenomegaly, ascites, abdominal collateral circulation, palmar erythema or spider naevi, telangiectasia, gynecomastia, parotid hypertrophy or Dupuytren's contracture should also be assessed.¹⁰ Hyperpigmentation would suggest haemochromatosis while observation of the Kayser-Fleischer corneal ring would indicate Wilson's disease. Tattoos or puncture sites could guide towards suspicion of viral hepatitis. The Courvoisier-Terrier sign (palpation of the gallbladder without pain) is very characteristic of neoplastic lesions that obstruct the bile duct. The presence of xanthomas and xanthelasmas are produced by the inability to excrete lipids and an alteration of their hepatic synthesis and would suggest chronic cholestasis such as primary biliary cirrhosis. Tuberos xanthomas are located on the extensor surfaces of the extremities, and flat xanthomas on the palms of the hands, on the neck, the trunk and the intermammary cleft. Xanthelasmas are located in the inner corner of both eyelids, and are only observed when the plasma concentration of total lipids exceeds 1300 mg/dL for a prolonged time, generally longer than several months.

Following physical examination, blood tests with full liver function should be performed as a first step and before imaging and further investigations. In serum, an increase in the biliary tract-excreted products such as bile salts, alkaline phosphatase, gamma-glutamyl transpeptidase (GGT), 5'-nucleotidase or cholesterol will be expected. In contrast, hepatocyte enzymes such as serum aminotransferases are expected to be less deranged.

3 | DIAGNOSIS

Early diagnosis of CCA remains a challenge. For patients with known chronic liver disease, ultrasonography is routinely performed as an accepted tool for HCC surveillance and may, if some occasions, identify iCCA at an early stage, when potential curative therapies are feasible.¹⁴ Nevertheless, the majority of iCCA cases occur in the absence of any known risk factors,¹ in this case the only chance for early diagnosis is by cross-sectional imaging performed for other reasons.

Imaging plays a key role in the management of cholangiocarcinoma (CCA) in terms of diagnosis, staging, follow-up and response to therapy. Moreover, there is increasing evidence that the recent introduction of non-morphologic imaging may predict the prognosis of the disease. The imaging modalities involved in the work-up of suspected CCA are US, CEUS, CT, MRI and ¹⁸FDG-PET. Their diagnostic accuracy is influenced by anatomic location and growth patterns of CCA.^{3,15,16}

3.1 | Role of ultrasound for iCCA and eCCA

Unenhanced US shows a high detection rate of iCCA. Even though the presence of segmental ectasia in the upstream biliary branches of the lesion can be suggestive of iCCA (Figures 1 and 2), it is not fully reliable for its characterization owing to the lack of specific features.¹⁷ Other issues are related to the reliability of CEUS for diagnosis of iCCA, particularly in the setting of chronic liver disease. Its use was questioned because of the potential risk of misclassification

FIGURE 1 Role of US and CEUS in iCCA. Panel A shows the presence of a hypoechoic mass located in the left lobe of the liver with the presence of a segmental biliary tree dilatation in a patient with no history of chronic hepatitis. Panel B shows the CEUS aspect. In particular panel B1 shows the hypervascular aspect of the lesion during the arterial phase with a globally hyperenhanced appearance, while panel B2 shows the hypovascular aspect of the lesion, during the portal phase (see the white arrows). Panel C shows the focal liver lesion biopsy with the tip of the needle exactly in the mass (see the white arrow)

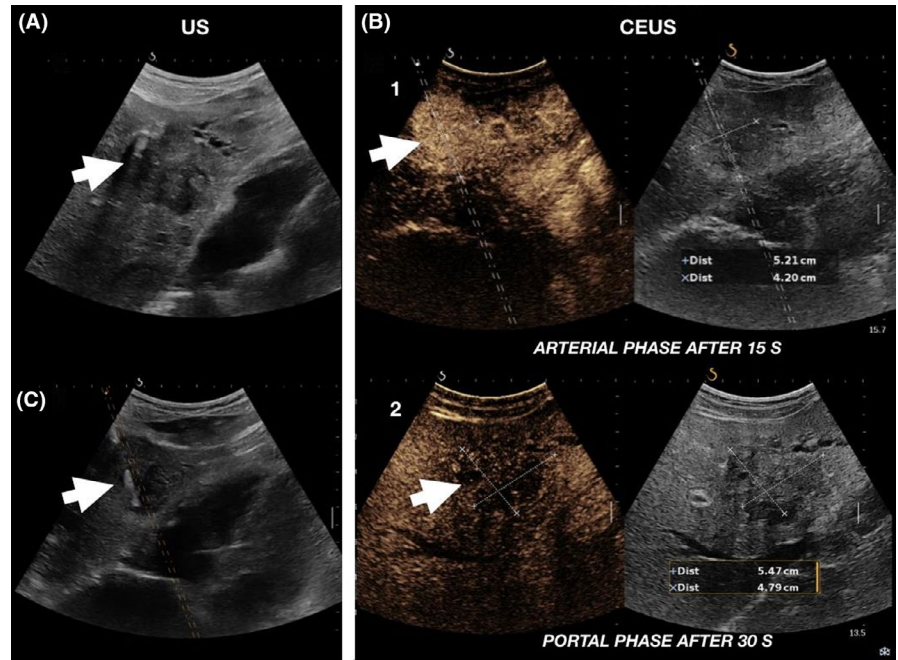
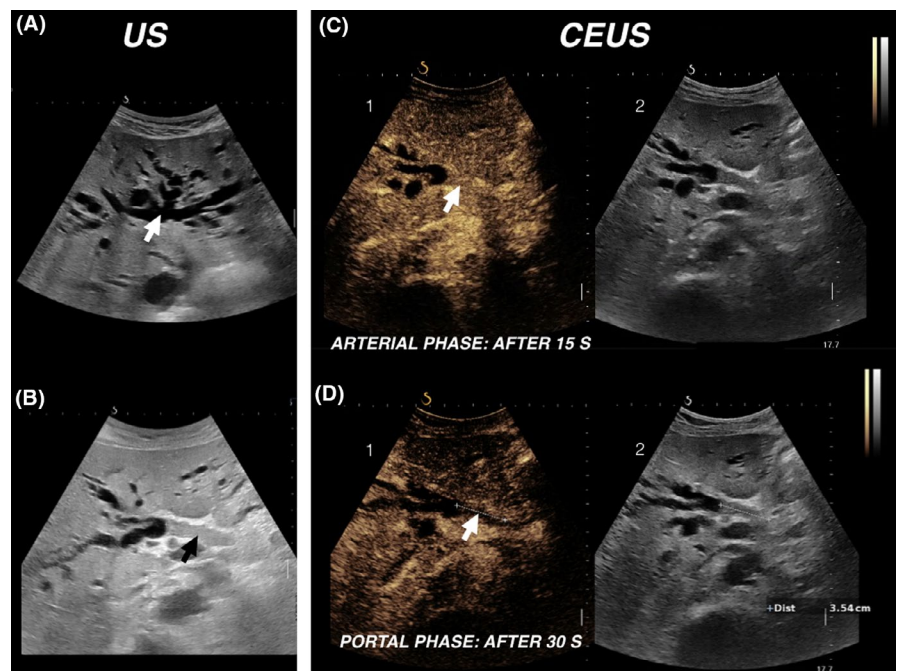


FIGURE 2 Role of US and CEUS in eCCA. Panels A and B show respectively the ultrasound appearance of upstream dilatation of the biliary tree (white arrow) because of the presence of a mass located in the distal tract of the extrahepatic biliary tree (dCCA). Panels C and D demonstrate the appearance of the dCCA mass during CEUS, which is respectively hyperenhanced during the arterial phase (Panel C1 white arrow), followed by washing out in the portal phase (Panel D1 white arrow). During CEUS the screen is split into two parts, the right one for conventional ultrasound (C2; D2) and the left for CEUS (C1; D1)



between iCCA and HCC; owing to the pattern of homogeneous arterial hyperenhancement, instead of the more typical arterial rim aspect, followed by washout at CEUS, which is present in about 50% of iCCA with cirrhosis.^{18,19} However, in a relevant proportion of iCCA cases, the onset of washout takes place earlier than 60 seconds after contrast injection,¹⁸⁻²⁰ while this is rarely observed in HCC, and the intensity of washout in the portal phase is more marked in iCCA than in HCC.²¹ The presence of the rim enhancement, during the arterial phase, together with the early and marked washout, minimizes the potential misdiagnosis between both iCCA and HCC in patients with cirrhosis and corresponds, according to the Liver Imaging Reporting

Data System (LI-RADS) for contrast-enhanced ultrasound (LI-RADS-CEUS), to an established diagnostic category, called LR-M. CEUS LI-RADS is a standardized system for technique, interpretation, reporting and data collection for CEUS, recently introduced in patients at risk of developing HCC, by the American College of Radiology (ACR). LR-M category includes a probably or definitely malignant lesion, developed in a cirrhotic liver with aspects not properly typical for HCC, which could be mainly a cholangiocarcinoma and more rarely a metastatic lesion.²² Although these refinements minimize the potential misdiagnosis between both iCCA and HCC, this pattern is also displayed by liver metastasis (although the incidence of this is

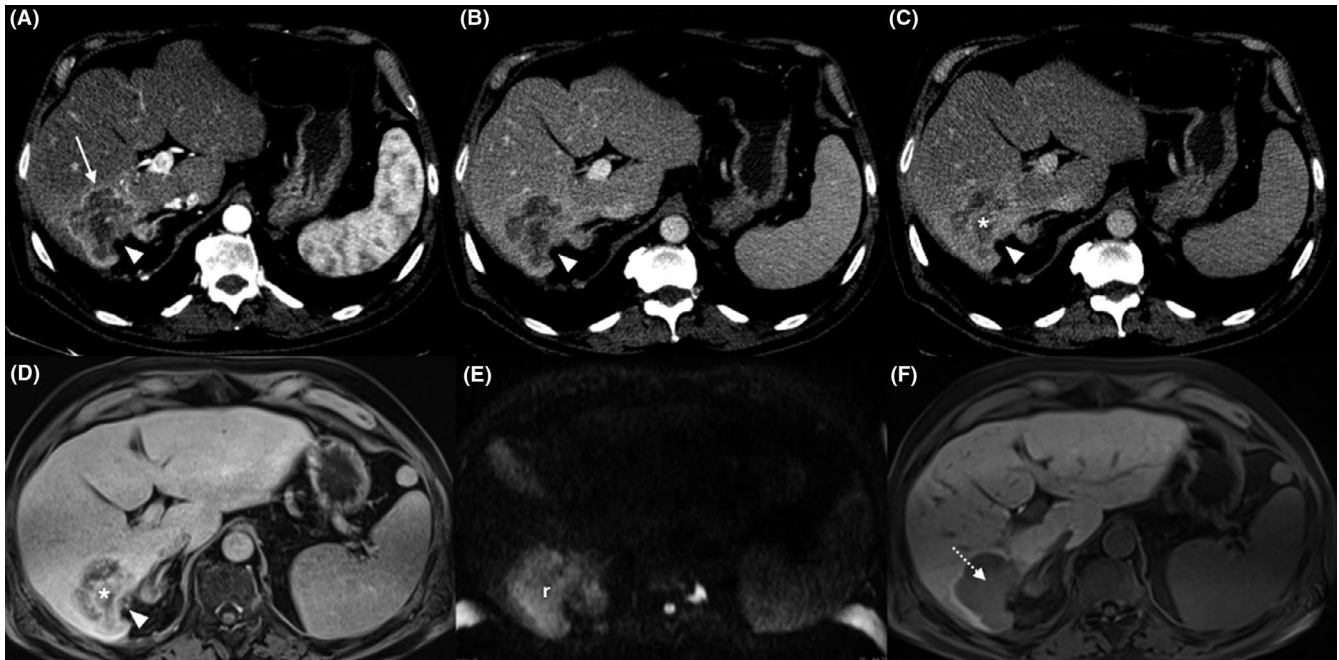


FIGURE 3 Role of CT and MRI imaging in iCCA. The typical vascular behaviour of iCCA can be appreciated on CT images (A, B, C). Peripheral arterial enhancement (arrow), capsular retraction (arrow head) and late enhancement (asterisk) represent typical imaging features of iCCA. MRI images (D, E, F) demonstrate the same vascular features of CT with the added value of diffusion weighted images (E), showing a marked restriction (r) and the hepatospecific phase (F), showing the absence of the uptake of hepatospecific contrast medium (dotted arrow)

very rare, especially in patients with cirrhosis) and thus, CEUS cannot be used as a reliable diagnostic tool of iCCA.

The accuracy of US for the identification of dCCA is around 80%-95% while pCCA are more difficult to identify (Figure 2).^{15,23} US is often the first imaging modality in patients with jaundice and can exclude benign cause of bile duct obstruction; thus, its role is to guide the choice of the best imaging modality to complete the assessment of the tumour.¹⁵ Neither US nor CEUS is considered for the staging of the disease.

The development of novel endoscopic techniques such as SpyGlass® cholangioscopy allows direct visualization of biliary tract.^{24,25} It has been suggested that SpyGlass increases the sensitivity for detecting cholangiocarcinoma over other standard endoscopic techniques. Indications such as evaluation of indeterminate biliary strictures and cancer diagnosis have been explored.^{26,27}

3.2 | Role of computed tomography imaging

Computed tomography is considered the standard imaging modality for the characterization and staging of CCA. The most frequent imaging patterns displayed by iCCA in the cirrhotic liver are an arterial peripheral-rim enhancement with progressive homogeneous contrast uptake until the delayed or stable contrast uptake through the different dynamic phases (Figure 3).^{28,29} Ancillary findings such as delayed enhancement, capsular retraction, vascular invasion or satellite nodules are highly suggestive of iCCA. When a lesion is smaller

than 1 cm or in the presence of cirrhosis or atypical features, the characterization is challenging.²³

CT features can be considered also for the preoperative evaluation of patients' prognosis. Many studies demonstrated that the hypercellular component of iCCA in the histology specimen corresponds to areas of arterial phase hyperenhancement in CT, while the fibrotic component corresponds to areas of delayed phase enhancement in CT. Moreover, it was shown that tumours with a significant hypercellular component have a better prognosis than more fibrotic ones in terms of both overall survival (OS) and disease-free survival (DFS).^{30,31} CT can also estimate resectability of pCCA (sensitivity 95%) since it can evaluate portal vein (sensitivity 89%, specificity 92%), hepatic artery (sensitivity 84%, specificity 93%) and bile ducts (accuracy 86%) involvement.^{32,33} In contrast, the accuracy for the identification of lymph node (sensitivity 61%, specificity 88%) and distant metastases (sensitivity 67%, specificity 94%) is low.³³

3.3 | Role of magnetic resonance and other imaging

Magnetic resonance imaging has similar accuracy of CT for diagnosis and staging of CCA²⁹ with the advantage of the use of hepatospecific contrast media, dedicated sequences to obtain MRI cholangiopancreatography (MRCP) and diffusion weighted imaging (DWI) helpful for the differentiation between HCC and iCCA.³⁴ On MRI, iCCA appears hypointense on T1-weighted and hyperintense on T2-weighted images. Dynamic images show peripheral enhancement in the arterial phase followed by progressive and concentric filling-in of

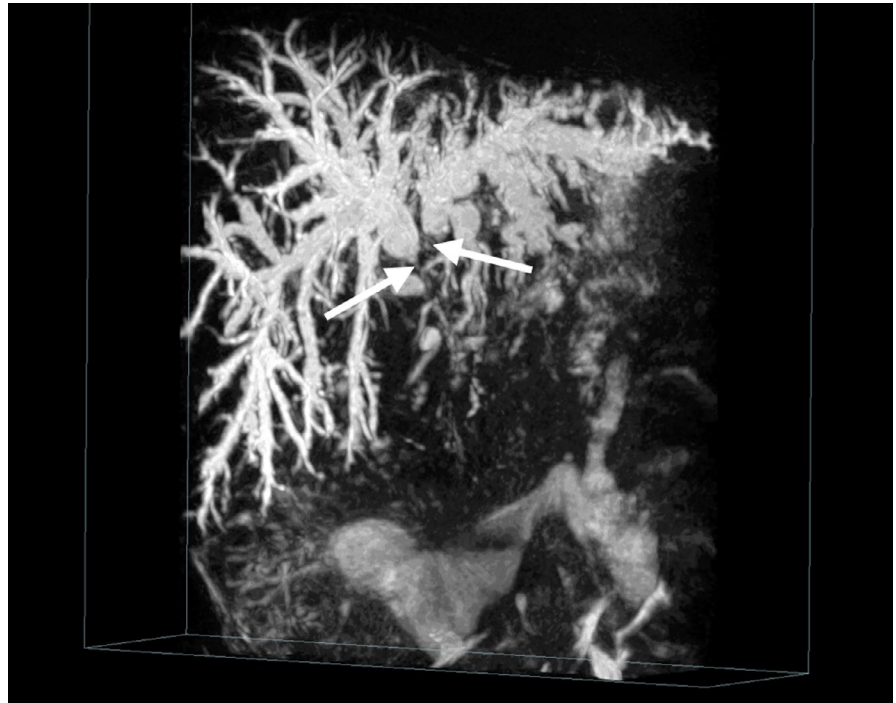


FIGURE 4 Role of MRI in eCCA. The image shows a 3D-cholangio MRI of an eCCA. In particular the white arrows indicate the absence of the signal in the right and left common bile ducts, because of the presence of a perihilar CCA, which determine the upstream dilatation of the whole intrahepatic biliary tree

the tumour with contrast material (Figure 3).²⁸ Pooling of contrast on delayed images is indicative of fibrosis and may be suggestive of an iCCA in the appropriate clinical setting. When gadoteric acid is used, the washout should be interpreted in the portal phase instead of in delayed phases to prevent the misclassification between HCC and iCCA in a cirrhotic liver.³⁵ The non-morphological imaging obtained with MRI (radiomics features; apparent diffusion coefficient, ADC; intravoxel incoherent motion, IVIM) showed high accuracy to evaluate patients' prognosis since it can predict recurrences³⁶ and microvascular infiltration.³⁷ MRI is as accurate as CT to estimate resectability of pCCA (sensitivity 94%) since it can evaluate portal vein (sensitivity 79%) and bile ducts (accuracy 71%) involvement^{32,33} (Figure 4).

¹⁸F-FDG-PET is the best imaging modality for distant metastasis surveillance or nodal metastases and to complete the staging in patients with potentially resectable disease at CT or MRI imaging. Moreover, ¹⁸F-FDG-PET is accurate in tumour detection and in differentiation between benign and malignant biliary strictures even if it may result in false-positive (eg in case of biliary inflammation) or false-negative (eg in case of mucinous tumours) results.^{3,38-41}

3.4 | Invasive techniques for confirmatory tissue diagnosis

Biopsy is mandatory for confirmation of CCA diagnosis.² Liver biopsy for iCCA and pCCA is a minimally invasive diagnostic procedure, performed percutaneously with guiding imaging (mainly in the form of ultrasound) (Figure 1C). This method is preferred, especially for iCCA, and also pCCA, because of the widespread use of ultrasound and also because of low cost and time savings. It could also be pursued in the presence of eCCA with liver metastases. Recently,

this procedure is more accurately performed under the guide of CEUS imaging, in order to avoid necrotic areas of the tumour. Another potential imaging modality employed for liver biopsy is CT. The sensitivity of liver biopsy depends on location, size and operator expertise. Core biopsies are required for definitive diagnosis and the size of the needles employed are recommended to be between 19 and 21 gauge, depending on the anatomical position of the lesion and also coagulation factors.

For eCCA, tissue acquisition via endoscopic ultrasound (EUS) may be pursued because of tumour location. EUS may also allow acquisition of cytology samples (via fine-needle aspiration or brushings) which could also confirm presence of malignant cells.

Although a positive biopsy/cytology result demonstrates the presence of the tumour, a negative result does not exclude it because of the potential sampling errors.² In occasions, repeat sampling is required in order to confirm diagnosis.⁴² The false-negative rate can be even higher in patients with pCCA.

The pathological diagnosis of iCCA is based on the WHO classification of biliary tract cancer showing an adenocarcinoma or mucinous carcinoma.⁴³ The most common histological findings of an iCCA are those of an adenocarcinoma showing tubular and/or papillary structures and a variable fibrous stroma.⁴⁴ The histological appearance of CCA is similar to that of metastatic adenocarcinoma arising from extra-biliary primary tumours, in particular the oesophagus, stomach, lung and pancreas; and thus, the differentiation of CCA from metastatic adenocarcinoma cannot be readily ascertained on histological examination, since no specific panel of immunohistochemistry markers is available yet. In addition, CCA needs to be distinguished from benign biliary lesions such as biliary microhamartomas (von Meyenburg complexes), peribiliary glands, reactive ductular proliferation and bile duct adenomas, particularly

TABLE 1 Staging of cholangiocarcinoma (AJCC 8th Edition).

	dCCA	pCCA	iCCA
Primary tumour (T)			
TX	Primary tumour cannot be assessed	Primary tumour cannot be assessed	Primary tumour cannot be assessed
T0	n/a	No evidence of primary tumour	No evidence of primary tumour
Tis	Carcinoma in situ/high-grade dysplasia	Carcinoma in situ/high-grade dysplasia	Carcinoma in situ (intraductal tumour)
T1	Tumour invades the bile duct wall with a depth <5 mm	Tumour confined to the bile duct, with extension up to the muscle layer fibrous tissue	–
T1a	–	–	Solitary tumour ≤5 cm without vascular invasion
T1b	–	–	Solitary tumour >5 cm without vascular invasion
T2	Tumour invades the bile duct wall with a depth of 5-12 mm	Tumour invades beyond the wall of the bile duct to surrounding adipose tissue, tumour invades adjacent hepatic parenchyma	Solitary tumour with intrahepatic vascular invasion or multiple tumours (with or without vascular invasion)
T2a	–	Tumour invades beyond the wall of the bile duct to surrounding adipose tissue	–
T2b	–	Tumour invades adjacent hepatic parenchyma	–
T3	Tumour invades the bile duct wall with a depth >12 mm	Tumour invades unilateral branches of the portal vein hepatic artery	Tumour perforating the visceral peritoneum
T4	Tumour involves the celiac axis, superior mesenteric artery, and/ common hepatic artery	Tumour invades the main portal vein, its branches bilaterally, the common hepatic artery; unilateral second-der biliary radicals with contralateral portal vein hepatic artery involvement	Tumour involving local extrahepatic structures by direct invasion
Regional lymph nodes (N)			
NX	Regional lymph nodes cannot be assessed	Regional lymph nodes cannot be assessed	Regional lymph nodes cannot be assessed
N0	No regional lymph node metastasis	No regional lymph node metastasis	No regional lymph node metastasis
N1	Metastasis in one to three regional lymph nodes	One to three positive lymph nodes typically involving the hilar, cystic duct, common bile duct, hepatic artery, posterior pancreatoduodenal, and portal vein lymph nodes	Regional lymph node metastasis present
N2	Metastasis in four or more regional lymph nodes	Four or more positive lymph nodes from the sites described for N1	–
Distant metastasis (M)			
M0	No distant metastasis	No distant metastasis	No distant metastasis
M1	Distant metastasis	Distant metastasis	Distant metastasis present
Prognostic stage groups			
0	Tis, N0, M0	Tis, N0, M0	Tis, N0, M0
I	T1, N0, M0	T1, N0, M0	–
Ia	–	–	T1a, N0, M0
Ib	–	–	T1b, N0, M0
II	T1, N0, M0	T2a-b, N0, M0	T2, N0, M0
IIa	T1N1/T2N0, M0	–	–
IIb	T2N1/T3N0/T3N1, M0	–	–
IIIa	T1-3, N2 M0	T3, N0, M0	T3, N0, M0
IIIb	T4, Any N, M0	T4, N0, M0	T4, Any N, M0 / Any T, N1, M0

(Continues)

TABLE 1 (Continued)

	dCCA	pCCA	iCCA
IIIc	–	Any T, N1, M0	–
IV	Any T, Any N, M1	–	Any T, any N, M1
IVa	–	Any T, N2, M0	–
IVb	–	Any T, Any N, M1	–

Adjusted from Ref. [45]. dCCA, distal cholangiocarcinoma; pCCA, perihilar cholangiocarcinoma, iCCA, intrahepatic cholangiocarcinoma.

in the presence of inflammation which can result in reactive cellular atypia.

4 | STAGING

Cancer is staged according to the extension of primary tumour (T), regional lymph node infiltration (N) and the presence of distant metastases (M). The TNM classification is broadly used in oncology.⁴⁵ While pathology is the basis for the T and N staging, radiological findings in the form of ce-CT, MRI or ¹⁸FDG-PET are the cornerstone for M staging.^{46,47}

The most commonly used TNM staging for cholangiocarcinoma is the one developed by the American Joint Committee on Cancer (AJCC).⁵³ The AJCC Staging System has been updated regularly, the last version being published in 2016 and made effective in 2018 (8th Edition).⁴⁵ The first edition of the AJCC Staging System was published in 1977 and made effective in 1978.⁵⁴ It is worth highlighting that staging criteria for cholangiocarcinoma were not introduced until the 2nd Edition was published in 1983 and made effective in 1984.⁵⁵ Interestingly, iCCA have been staged using same criteria as for other primary liver tumours such as HCC. A specific staging system for iCCA was not provided until the 7th Edition (published in 2009 and effective between 2010 and 2017).⁵⁶ In addition, the 7th Edition was also the first to separate staging systems for pCCA and dCCA (which had been jointly staged in previous editions).

Table 1 provides a summary of current staging system according to the most recent AJCC 8th Edition⁴⁵ which has shown some major changes compared to the previous version.⁵⁶ Such changes could be summarized as follows:

For dCCA, invasion of the depth of the bile duct wall was incorporated into the T stage to differentiate between pT1, pT2 and pT3. In addition, the pT4 stage includes the invasion of the common hepatic artery into the definition. The N stage now incorporates number of lymph nodes affected rather than just the presence or absence of lymph node metastases only. There was an addition of N2 stage which was not part of the previous staging version. The M stage remained unchanged.

For pCCA, the T and M stage did not undergo significant changes. In contrast, the N stage was adjusted, similar to dCCA, to reflect not only location but also number of regional lymph nodes.

The staging system for iCCA did not vary for the N stage. In contrast, the T staging underwent significant changes. First, the T1 category was subdivided to reflect the prognostic impact of tumour size (using 5 cm as cut-off). Secondly, the T2a and T2b categories were joined into the same T2 category which covers both 'solitary tumour with intrahepatic vascular invasion' (previously categorised as T2a) and 'multiple tumours, with or without vascular invasion' (previously categorised as T2b). Finally, T3 and T4 have been adjusted and T4 now includes not only periductal invasion but also invasion of local extrahepatic structures. Because of the changes in T stage, iCCA stage IV was previously divided into stage IVa and IVb, being patients with distant metastases classified as IVb. In the latest version, the stage IVa group has disappeared and such patients are currently classified as IIIB stage.

The TNM stage aims to provide a clinically meaningful classification for healthcare professionals, since it is known to correlate well with prognosis.⁵⁷ Even though the changes in AJCC Staging Systems aimed to reflect patients' outcomes more accurately, some limitations still apply. The fact that iCCA was the latest to be incorporated into the AJCC Staging System has brought significant attention into this disease group.⁵⁸ For this specific subgroup, significant changes have been made in the latest version (as specified earlier), which have been very much welcomed by the cholangiocarcinoma community.⁵⁹ However, further changes may be required for iCCA. Some studies have highlighted the fact that T2 and T3 iCCA tumours seem to have similar outcomes.^{57,60} It is worth reminding that T2 tumours include iCCA with multiple tumours within the liver (multifocal disease), which has been extrapolated from previous staging systems of HCC. Whether the biological implication of multifocal tumours in HCC and iCCA is equally relevant could be questioned. It could be postulated that the presence of multifocal disease could represent metastatic disease in iCCA, since it is generated in the absence of background liver damage (ie majority of HCC are developed in the background of liver cirrhosis). In a SEER database analysis from 2009, Nathan and colleagues showed that patients with multifocal iCCA had an increased risk of death (Hazard Ratio 1.42 (95% CI 1.01-2.10); $P < 0.005$).⁶¹ Other studies have also confirmed such impact on patients' outcome.⁶² In fact, multifocal disease is considered a contraindication for surgery by many expert consensus groups.⁶³ Additional preliminary data have provided results in favour of this hypothesis and are pending further validation; a series of 162 patients diagnosed with iCCA suggested that patients with multifocal liver disease have similar overall survival to patients with extrahepatic metastatic disease,⁶⁴ thus further adjustments on the iCCA staging criteria may be required for future staging versions.⁵⁹

5 | CONCLUSIONS

Cholangiocarcinoma (CCA) includes a heterogeneous group of tumours. Unfortunately, because of the unspecific symptoms at early stages and lack of screening strategies, diagnosis is usually performed at advanced stages. Imaging modalities for diagnosis and staging of CCA, includes US, CEUS, ce-CT, MRI and ¹⁸F-FDG-PET. Staging classifications have been modified over the latest versions but may require further adjustments once natural behaviour of CCA is better understood.

ACKNOWLEDGEMENTS

The authors of this review article are members of the European Network for the Study of Cholangiocarcinoma (ENS-CCA) and participate in the initiative COST Action EURO-CHOLANGIO-NET granted by the COST Association (CA18122). Angela Lamarca received funding from the American Society of Clinical Oncology (ASCO) Conquer Cancer Foundation Young Investigator Award, The Cholangiocarcinoma Foundation Fellowship and The Christie Charity.

CONFLICT OF INTEREST

Dr Angela Lamarca received travel and educational support from Ipsen, Pfizer, Bayer, AAA, SirtEx, Novartis and Delcath, speaker honoraria from Merck, Pfizer and Ipsen and advisory honoraria from EISAI. Other authors declared no conflict of interest. Dr Alejandro Forner received speaker fees from Bayer, Gilead, and MSD and consultancy fees from Bayer and Guerbert.

ORCID

Alejandro Forner  <https://orcid.org/0000-0002-9014-4950>

Gianpaolo Vidili  <https://orcid.org/0000-0003-0003-1272>

Marco Rengo  <https://orcid.org/0000-0001-9087-5692>

Luis Bujanda  <https://orcid.org/0000-0002-4353-9968>

Mariano Ponz-Sarvisé  <https://orcid.org/0000-0002-3240-729X>

Angela Lamarca  <https://orcid.org/0000-0001-9696-6122>

REFERENCES

- Banales JM, Cardinale V, Carpino G, et al. Expert consensus document: Cholangiocarcinoma: current knowledge and future perspectives consensus statement from the European Network for the Study of Cholangiocarcinoma (ENS-CCA). *Nat Rev Gastroenterol Hepatol*. 2016;13:261-280.
- Bridgewater J, Galle PR, Khan SA, et al. Guidelines for the diagnosis and management of intrahepatic cholangiocarcinoma. *J Hepatol*. 2014;60:1268-1289.
- Lamarca A, Barriuso J, Chander A, et al. 18F-fluorodeoxyglucose positron emission tomography (18FDG-PET) for patients with biliary tract cancer: systematic review and meta-analysis. *J Hepatol*. 2019. pii: S0168-8278(19)30126-6. <https://doi.org/10.1016/j.jhep.2019.01.038>.
- Shimada K, Sano T, Sakamoto Y, Esaki M, Kosuge T, Ojima H. Surgical outcomes of the mass-forming plus periductal infiltrating types of intrahepatic cholangiocarcinoma: a comparative study with the typical mass-forming type of intrahepatic cholangiocarcinoma. *World J Surg*. 2007;31:2016-2022.
- Endo I, Gonen M, Yopp AC, et al. Intrahepatic cholangiocarcinoma: rising frequency, improved survival, and determinants of outcome after resection. *Ann Surg*. 2008;248:84-96.
- Vincenzo Cardinale M, Carpino G, Di Matteo S, et al. Intrahepatic cholangiocarcinoma: review and update. *Hepatoma Res*. 2018;4:1-16.
- Vuppalanchi R, Liangpunsakul S, Chalasani N. Etiology of new-onset jaundice: how often is it caused by idiosyncratic drug-induced liver injury in the United States? *Am J Gastroenterol*. 2007;102:558-562; quiz 693.
- Gondal B, Aronsohn A. A systematic approach to patients with jaundice. *Semin Intervent Radiol*. 2016;33:253-258.
- Sullivan JI, Rockey DC. Diagnosis and evaluation of hyperbilirubinemia. *Curr Opin Gastroenterol*. 2017;33:164-170.
- Fargo MV, Grogan SP, Saguil A. Evaluation of jaundice in adults. *Am Fam Physician*. 2017;95:164-168.
- Beuers U, Kremer AE, Bolier R, Elferink RP. Pruritus in cholestasis: facts and fiction. *Hepatology*. 2014;60:399-407.
- Bassari R, Koea JB. Jaundice associated pruritis: a review of pathophysiology and treatment. *World J Gastroenterol*. 2015;21:1404-1413.
- Kremer AE, Namer B, Bolier R, et al. Pathogenesis and management of pruritus in PBC and PSC. *Dig Dis*. 2015;33(Suppl 2):164-175.
- European Association for the Study of the Liver. Electronic address eee, European Association for the Study of the L. EASL Clinical Practice Guidelines: Management of hepatocellular carcinoma. *J Hepatol*. 2018;69:182-236.
- Hennedige TP, Neo WT, Venkatesh SK. Imaging of malignancies of the biliary tract—an update. *Cancer Imaging*. 2014;14:14.
- Joo I, Lee JM, Yoon JH. Imaging diagnosis of intrahepatic and perihilar cholangiocarcinoma: recent advances and challenges. *Radiology*. 2018;288:7-13.
- Vidili G, De Sio I, D'Onofrio M, et al. SIUMB guidelines and recommendations for the correct use of ultrasound in the management of patients with focal liver disease. *J Ultrasound*. 2018. <https://doi.org/10.1007/s40477-018-0343-0>.
- Vilana R, Forner A, Bianchi L, et al. Intrahepatic peripheral cholangiocarcinoma in cirrhosis patients may display a vascular pattern similar to hepatocellular carcinoma on contrast-enhanced ultrasound. *Hepatology*. 2010;51:2020-2029.
- Galassi M, Iavarone M, Rossi S, et al. Patterns of appearance and risk of misdiagnosis of intrahepatic cholangiocarcinoma in cirrhosis at contrast enhanced ultrasound. *Liver Int*. 2013;33:771-779.
- Wildner D, Bernatik T, Greis C, Seitz K, Neurath M, Strobel D. CEUS in hepatocellular carcinoma and intrahepatic cholangiocellular carcinoma in 320 patients—early or late washout matters: a subanalysis of the DEGUM multicenter trial. *Ultraschall Med*. 2015;36:132-139.
- Wildner D, Pfeifer L, Goertz RS, et al. Dynamic contrast-enhanced ultrasound (DCE-US) for the characterization of hepatocellular carcinoma and cholangiocellular carcinoma. *Ultraschall Med*. 2014;35:522-527.
- Dietrich C, Fetzer D, Jang H-R, et al. v2017 CORE (For CEUS with Pure Blood Pool Agents). <https://www.acr.org/Clinical-Resources/Reporting/./LI-RADS>, American College of Radiology, 2017. Accessed December 21, 2018.
- Mar WA, Shon AM, Lu Y, et al. Imaging spectrum of cholangiocarcinoma: role in diagnosis, staging, and posttreatment evaluation. *Abdom Radiol (NY)*. 2016;41:553-567.
- Chen YK, Pleskow DK. SpyGlass single-operator peroral cholangiopancreatography system for the diagnosis and therapy of bile-duct disorders: a clinical feasibility study (with video). *Gastrointest Endosc*. 2007;65:832-841.

25. Williamson JB, Draganov PV. The usefulness of SpyGlass choledochoscopy in the diagnosis and treatment of biliary disorders. *Curr Gastroenterol Rep.* 2012;14:534-541.
26. Laleman W, Verraes K, Van Steenberghe W, et al. Usefulness of the single-operator cholangioscopy system SpyGlass in biliary disease: a single-center prospective cohort study and aggregated review. *Surg Endosc.* 2017;31:2223-2232.
27. Pereira P, Peixoto A, Andrade P, Macedo G. Peroral cholangiopancreatography with the SpyGlass(R) system: what do we know 10 years later. *J Gastrointest Liver Dis.* 2017;26:165-170.
28. Rimola J, Forner A, Reig M, et al. Cholangiocarcinoma in cirrhosis: absence of contrast washout in delayed phases by magnetic resonance imaging avoids misdiagnosis of hepatocellular carcinoma. *Hepatology.* 2009;50:791-798.
29. Lo EC, N. Rucker A, Federle MP. Carcinoma and intrahepatic cholangiocarcinoma: imaging for diagnosis, tumor response to treatment and liver response to radiation. *Semin Radiat Oncol.* 2018;28:267-276.
30. Türkoğlu MA, Yamamoto Y, Sugiura T, et al. The favorable prognosis after operative resection of hypervascular intrahepatic cholangiocarcinoma: A clinicopathologic and immunohistochemical study. *Surgery.* 2016;160:683-690.
31. Ariizumi S-I, Kotera Y, Takahashi Y, et al. Mass-forming intrahepatic cholangiocarcinoma with marked enhancement on arterial-phase computed tomography reflects favorable surgical outcomes. *J Surg Oncol.* 2011;104:130-139.
32. Zhang H, Zhu J, Ke F, et al. Radiological imaging for assessing the respectability of hilar cholangiocarcinoma: a systematic review and meta-analysis. *Biomed Res Int.* 2015;2015:497942.
33. Ruys At, Van Beem Be, Engelbrecht M, Bipat S, Stoker J, Van Gulik Tm. Radiological staging in patients with hilar cholangiocarcinoma: a systematic review and meta-analysis. *Br J Radiol.* 2012;85:1255-1262.
34. Jhaveri KS, Hosseini-Nik H. MRI of cholangiocarcinoma. *J Magn Reson Imaging.* 2015;42:1165-1179.
35. Choi SH, Lee SS, Kim SY, et al. Intrahepatic cholangiocarcinoma in patients with cirrhosis: differentiation from hepatocellular carcinoma by using gadoxetic acid-enhanced MR imaging and dynamic CT. *Radiology.* 2017;282:771-781.
36. Liang W, Xu L, Yang P, et al. Novel nomogram for preoperative prediction of early recurrence in intrahepatic cholangiocarcinoma. *Front Oncol.* 2018;8:360.
37. Zou X, Luo Y, Li Z, et al. volumetric apparent diffusion coefficient histogram analysis in differentiating intrahepatic mass-forming cholangiocarcinoma from hepatocellular carcinoma. *J Magn Reson Imaging.* 2018.
38. Jiang L, Tan H, Panje CM, Yu H, Xiu Y, Shi H. Role of 18F-FDG PET/CT imaging in intrahepatic cholangiocarcinoma. *Clin Nucl Med.* 2016;41:1-7.
39. Choi EK, Yoo le R, Kim SH, et al. The clinical value of dual-time point 18F-FDG PET/CT for differentiating extrahepatic cholangiocarcinoma from benign disease. *Clin Nucl Med.* 2013;38:e106-111.
40. Kim Y-J, Yun M, Lee WJ, Kim KS, Lee JD. Usefulness of 18F-FDG PET in intrahepatic cholangiocarcinoma. *Eur J Nucl Med Mol Imaging.* 2003;30:1467-1472.
41. Aljiffry M, Abdulelah A, Walsh M, Peltekian K, Alwayn I, Molinari M. Evidence-based approach to cholangiocarcinoma: a systematic review of the current literature. *J Am Coll Surg.* 2009;208:134-147.
42. Weber A, Schmid RM, Prinz C. Diagnostic approaches for cholangiocarcinoma. *World J Gastroenterol.* 2008;14:4131-4136.
43. HamiltonSR, Aaltonen LA. *Pathology and Genetics of Tumours of the Digestive System.* Lyon: International Agency for Research on Cancer (IARC); 2000, reprinted 2006.
44. Goodman ZD. Neoplasms of the liver. *Mod Pathol.* 2007;20(Suppl 1):S49-S60.
45. Amin M. *AJCC Cancer Staging Manual* (8th ed.). American Joint Committee on Cancer; 2017. https://doi.org/10.1007/978-3-319-40618-3_1.
46. Schofl R. Diagnostic endoscopic retrograde cholangiopancreatography. *Endoscopy.* 2001;33:147-157.
47. Yeh BM, Liu PS, Soto JA, Corvera CA, Hussain HK. MR imaging and CT of the biliary tract. *Radiographics.* 2009;29:1669-1688.
48. Mittal PK, Moreno CC, Kalb B, et al. Primary biliary tract malignancies: MRI spectrum and mimics with histopathological correlation. *Abdom Imaging.* 2015;40:1520-1557.
49. Inui K, Yoshino J, Miyoshi H. Differential diagnosis and treatment of biliary strictures. *Clin Gastroenterol Hepatol.* 2009;7:S79-S83.
50. Brugge W, DeWitt J, Klapman JB, et al. Techniques for cytologic sampling of pancreatic and bile duct lesions. *Diagn Cytopathol.* 2014;42(4):333-337.
51. Hammoud GM, Almashhrawi A, Ibdah JA. Usefulness of endoscopic ultrasound-guided fine needle aspiration in the diagnosis of hepatic, gallbladder and biliary tract Lesions. *World J Gastrointest Oncol.* 2014;6:420-429.
52. Annunziata S, Caldarella C, Pizzuto DA, et al. Diagnostic accuracy of fluorine-18-fluorodeoxyglucose positron emission tomography in the evaluation of the primary tumor in patients with cholangiocarcinoma: a meta-analysis. *Biomed Res Int.* 2014;2014:247693.
53. System ATs. AJCC TNM staging system. <http://cancerstaging.org/references-tools/Pages/What-is-Cancer-Staging.aspx>. Accessed October 2018.
54. AJCC. *Manual for Staging of Cancer* (1st ed.). Chicago, IL: AJCC; 1977.
55. Bearhs OM. *MAJCC Manual for Staging of Cancer* (2nd ed.). 1983. ISBN 0-397-50594-9.
56. Edge S, Compton CC, Fritz AG, Greene FL, Trotti A. *AJCC Cancer Staging Manual.* New York: Springer-Verlag; 2015.
57. Spolverato G, Bagante F, Weiss M, et al. Comparative performances of the 7th and the 8th editions of the American Joint Committee on Cancer staging systems for intrahepatic cholangiocarcinoma. *J Surg Oncol.* 2017;115:696-703.
58. Ronneklev-Kelly SM, Pawlik TM. Staging of intrahepatic cholangiocarcinoma. *Hepatobiliary Surg Nutr.* 2017;6:35-43.
59. Lee AJ, Chun YS. Intrahepatic cholangiocarcinoma: the AJCC/UICC 8th edition updates. *Chin Clin Oncol.* 2018;7:52.
60. Kang S-H, Hwang S, Lee Y-J, et al. Prognostic comparison of the 7th and 8th editions of the American Joint Committee on Cancer staging system for intrahepatic cholangiocarcinoma. *J Hepatobiliary Pancreat Sci.* 2018;25:240-248.
61. Nathan H, Aloia TA, Vauthey J-N, et al. A proposed staging system for intrahepatic cholangiocarcinoma. *Ann Surg Oncol.* 2009;16:14-22.
62. Raof M, Dumitra S, Ituarte P, et al. Development and validation of a prognostic score for intrahepatic cholangiocarcinoma. *JAMA Surg.* 2017;152:e170117.
63. Weber SM, Ribero D, O'Reilly EM, Kokudo N, Miyazaki M, Pawlik TM. Intrahepatic cholangiocarcinoma: expert consensus statement. *HPB (Oxford).* 2015;17:669-680.
64. Lamarca A, Pilhak R, McNamara MG, et al. *Liver metastases from intrahepatic cholangiocarcinoma: does the current staging classification reflect patient outcomes?* ENS-CCA Biennial Congress, June 2018, Rome, Italy.

How to cite this article: Forner A, Vidili G, Rengo M, Bujanda L, Ponz-Sarvisé M, Lamarca A. Clinical presentation, diagnosis and staging of cholangiocarcinoma. *Liver Int.* 2019;39(Suppl. 1):98-107. <https://doi.org/10.1111/liv.14086>