

## Monolithic zirconia and digital impression: case report

F. De Angelis<sup>1</sup>, E. Brauner<sup>1</sup>, G. Pignatiello<sup>1</sup>, F. Mencio<sup>1</sup>, D. Rosella<sup>1</sup>, P. Papi<sup>1</sup>, T. Di Carlo<sup>2</sup>, A. Giovannetti<sup>1</sup>, G. Pompa<sup>1</sup>, S. Di Carlo<sup>1</sup>

<sup>1</sup>Department of Oral and Maxillo Facial Sciences, Sapienza University of Rome; <sup>2</sup>Private Practitioner in Rome, Italy

### Abstract

**Aims.** The aim of this study is to present a clinical case of a full arch prosthetic rehabilitation on natural teeth, combining both digital work-flow and monolithic zirconia.

**Patients and methods.** Digital impression was taken with an intraoral optical scanner (CS3500, Carestream Dental, Atlanta, GA, USA). A prosthetic rehabilitation was realized on natural teeth using monolithic zirconia from 1.6 to 1.4 and from 2.7 to 2.4 frameworks, while in the aesthetic area (from 2.3 to 1.3), technicians left on the structure a 0.8 mm vestibular space for ceramic layering.

**Discussion.** The combination of digital impression technology and the use of the monolithic zirconia had demonstrated the delivery of the final prosthetic device in a quick time without the need to re-model functional or aesthetic areas. The digital work-flow combines intraoral optical impression techniques and CAD/CAM technology, in order to achieve a fully digital and successful way to deliver prosthetic restorations to patients, providing aesthetics and function in shorter intervals of time. The clinical outcome of this study was satisfactory but a long-term evaluation is needed. *Clin Ter 2017; 168(4):e229-232. doi: 10.7417/CT.2017.2011*

**Key words:** digital impression, digital work-flow, full arch impressions, monolithic zirconia

Digital impressions allow clinicians to get a quick impression validation: they can check immediately preparation parallelism, undercuts and if there is sufficient occlusal space. In complex full arch restoration cases, it is essential to ensure accuracy and precision of all stages to minimize any inaccuracies at the end of the treatment. Digital impression allows to eliminate most at risk phases ie: distortion of impression and of the plaster model, distortion of occlusion wax, bubbles on the model. Digital work-flow combines optical intraoral impression techniques and CAD/CAM technology, in order to achieve a fully digital and successful way to deliver prosthetic restorations to patients quickly. There are 2 types of zirconia monolithic materials: opaque and translucent zirconia. The opaque zirconia has increased flexural strength and is indicated in the posterior region of the mouth. The translucent zirconia has also important aesthetic properties, it allows the adoption of certain characterizations and thus is used in both posterior both in anterior areas because it still maintains excellent resistance. To day, many articles on monolithic zirconia and digital impression have been published on natural teeth and implants (4-5). The purpose of this article is to present, through the images of the clinical case, the potential that can be achieved by combining the two techniques for a full arch prosthetic rehabilitation.

### Introduction

In a full arch impressions of multiple preparations of the teeth there are several difficulties such as the distortion of the material sometimes created by divergent teeth, humidity control, greater stress for the dentist and discomfort for the patient. Sometimes there are anatomical obstacles that prevent the taking of a good impression: this is the case of maxilla-facial oncological, malformed and traumatized patients (1-3). For these reasons this study has the aim to apply digital impressions in a full arch rehabilitations on natural teeth.

### Materials and methods

A 75-year-old male patient with a diagnosis of severe bruxism, bone reabsorption and decayed teeth in the upper jaw (Fig.1), presented at the Department of Oral and Maxillofacial Sciences of University Sapienza of Rome for a fixed prosthetic restoration. A fixed full-arch rehabilitation on natural teeth divided into two quadrants was programmed. The patient agreed to treatment and signed the informed consent form, according to the World Medical Declaration of Helsinki. Pillars had a chamfer preparation and before

*Correspondence:* Francesca De Angelis, DDS, PhD, Research fellow, Department of Oral and Maxillo Facial Sciences “Sapienza” University of Rome. Via Caserta 6, 00161. Tel.: 0039 338 1819312 E-mail: francesca.deangelis@uniroma1.it

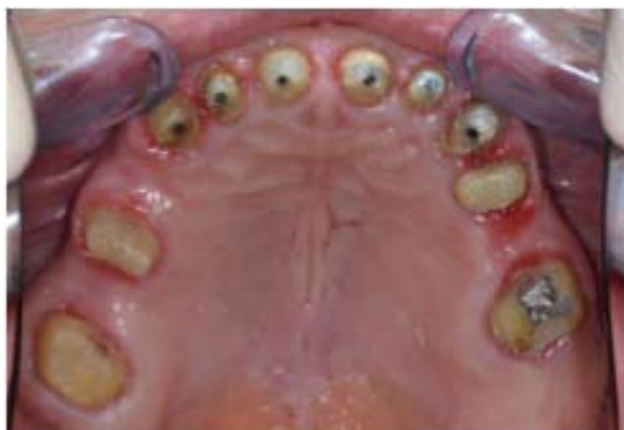

Fig. 1. Occlusal view of clinical situation.

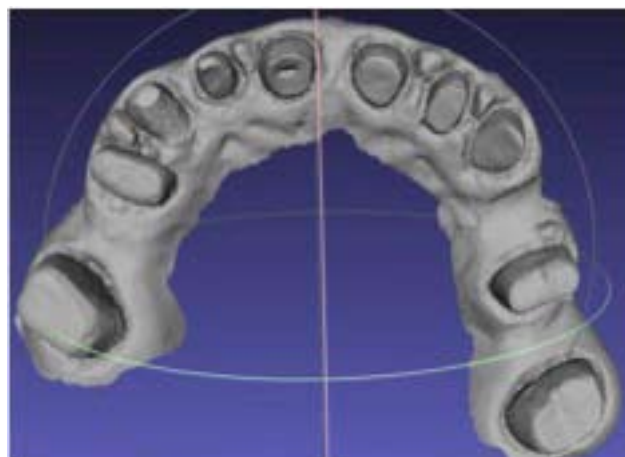


Fig. 2. Occlusal view of the STL model.

impression taking with an intraoral optical scanner (CS3500, Carestream Dental, Atlanta, GA, USA) (Fig.2), dental gingival retraction cord was inserted in the gingival sulcus. The system CareStream CS3500 does not require a matting powder and is characterized by a scan with an inclination up to 45° and with a depth of field from -2 mm to +13 mm. The acquisition software was the CS3500 Acquisition, it requires 50% of images' overlapping taken in sequence to facilitate the matching work. The scans were performed without the use of artificial light sources. At the end of each scan the "cloud of points" has been processed by a software which has generated a polygon mesh representing the digital impression, which has been developed in a virtual STL model. To evaluate the accuracy of the scanner, the STL model was compared to an STL model derived from the scan of the master model obtained using a laboratory extraoral scanner Sinergia Scan, produced by Nobil Metal s.p.a. which uses the Optical RevEng Dental 2.5 as acquisition software that has measured the alignment error between the models with a precision of the order of 0.001mm (1 μm). 10 digital impressions were detected. A mask was realized for each prosthetic pillar and the alignment error between the master model and each STL model was calculated (Tab.1). For the evaluation

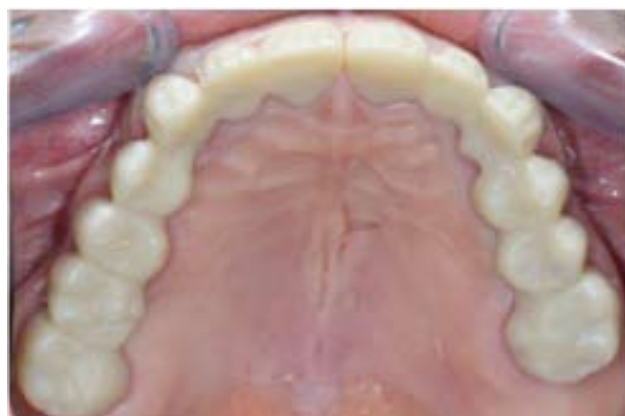

Fig. 3. Occlusal maxillary arch frameworks with monolytic zirconia

of the precision, measurements were performed using the ExoCad software. Posterior elements restorations, from 1.6 to 1.4 and from 2.7 to 2.4 were performed in monolithic zirconia, while in the aesthetic area (2.3 to 1.3), technicians left on the structure a 0.8 mm vestibular space for ceramic layering (Fig. 3). Once the monolithic zirconia frameworks had been fabricated, the internal fit was checked intra-orally, using a silicone based fit checking material (Fit Checker, GC, Tokyo, Japan). At this stage the accuracy of the bite relationship record was also verified. Zirconia frameworks were perfectly fitting both on teeth and on polyurethane model, then structures were sent to dental technicians for ceramic layering of aesthetic area. The porcelain application was then carried out. During the final appointment final restorations were tried in the mouth and the aesthetics, contact points and occlusion were assessed. The final restorations were then cemented (Fig.4). The cement used was a resin cement (RelyX™ Ultimate, 3M Espe).

Table 1. Alignment error values between master model and each scan.

	ALIGNMENT ERROR BETWEEN PROSTHETIC PILLARS (μm)		
	FROM 1.6 TO 2.7	FROM 1.6 TO 1.1	FROM 2.1 TO 2.7
SCAN 1	112	62	65
SCAN 2	101	73	72
SCAN 3	125	84	81
SCAN 4	98	60	69
SCAN 5	115	87	85
SCAN 6	122	73	70
SCAN 7	128	65	73
SCAN 8	99	71	62
SCAN 9	118	83	79
SCAN 10	129	69	80

## Results

In this study patient had not referred any discomfort, no breathing difficulty, no teeth and periodontal sensibility, no smell and taste nuisance. The patient perception was positive.

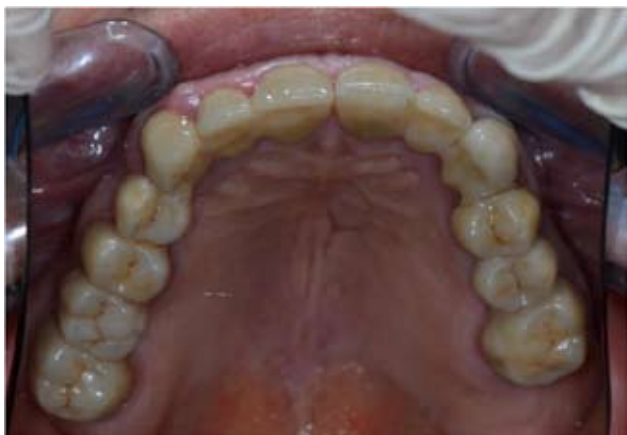

Fig. 4. Clinical situation on the day of final restoration.

The CS 3500 CareStream® system has demonstrated an acceptable level of accuracy and precision for prosthetic rehabilitation on natural teeth. The combination of digital impression technology and the use of the monolithic zirconia has enabled the delivery of the final prosthetic device in a quick time and without the need to remodel neither functional nor aesthetic. The clinical outcome was hopeful and a the long term evaluation is needed.

## Discussion

Several studies have investigated and compared digital and conventional impression techniques in terms of both precision and accuracy (6-7). Digital impressions are dimensionally very stable, while traditional materials may undergo variations which could affect accuracy of the final result (8-9).

Especially in case of full-arch restorations on natural teeth, favouring accumulation of plaque (10), cement dissolution (11) and inflammation of periodontium (12). In some cases, however, it may be necessary to realize the image of three-dimensional physical models (13-14). These models are not made of plaster (15), but of polyurethane and they eliminate the risk of inaccuracies arising from the expansion of the gypsum and the possible movement or displacement of the individual prosthetic abutment when model is sectioned. The precision of frameworks made from optical impression is clinically comparable to those conventionally manufactured. Both methods lead to the realization of fixed rehabilitations with a marginal gap of less than 120 µm as a minimum reliability value to consider satisfactory a prosthetic rehabilitation (16-17).

The majority of current studies report the fit of single crowns on natural teeth (10-11). In these cases, the accuracy and precision of the intraoral scanner is considered greater compared to traditional impression. This may reveal very useful in complex oral rehabilitations (18-20). Few studies were conducted regarding full arch restorations (21-26). Using a dental resin model of a full-arch restoration containing 14 elements, Patzel et al. in 2014 (27) tested the accuracy of 4 intraoral scanners. The averages accuracy varied from 38 to 332.9 µm, while the precision range fluctuated

from 37.9 to 99.1 µm. The development of digital models has several advantages that include reduced storage requirement, rapid access to 3D diagnostic information and easy transfer of digital data for communication with professionals and patients (28). The interest on intraoral scanners has been growing and new devices are continuously launched. The accuracy, reliability, time requirement and patient perception should be demonstrated using several available intraoral scanners and they should be comparable to those of the conventional technique for full-arch impressions (29). There are still several obstacles and failures to detect intraoral impressions. Some systems require a spray layer on the tooth surface and the thickness of the powder may slightly transfiguring the contour of the tooth. Another serious problem is the movement of the scanner during the scanning which can affect the accuracy of scanning, especially in full-arch restorations (30).

Alginates, polyether, vinyl polysiloxane, impression materials, and all kinds of plaster stone can suffer some degree of distortion, crating differences in respect to actual tooth size (31-32).

Procedure duration, patient comfort, and associated costs should also be accounted when analyzing the efficacy of clinical procedures (33). Digital models produced by intraoral scan eliminate the need of impressions materials; however, the size of the tip of the intraoral scans makes it difficult to access some intraoral areas, potentially interfering with the image quality. The relatively scarcity of studies performed in vivo or intraorally is another limitation. Clinically, there are some restrictions as individual tolerance of patients, little work space in mouth, or interferences by tongue movement or orthodontic appliances. Flügge et al. (34) even suggest that the intraoral conditions can influence the inaccuracy of a scan. In order to overcome the accuracy reduction in full-arch restorations we decided to divide the monolithic zirconium structure into two hemiarches because accuracy values in the hemiarch remain very high (Tab.1).

It was a remarkable observation that only few studies have evaluated complete-arch scans acquired directly in the patient's mouth. The assessment of time requirements for full-arch scanning is relevant to determine whether digital technology is practical for routine impression taking in prosthodontics. The scanning times measured in the published studies varied largely (35-36). The methodological inconsistency of the available studies prevented the collection of a conclusive evidence regarding time efficiency of full-arch scanning. Therefore, in future studies, for comparative purposes among scanners and with the conventional method, it would be advisable to precisely define what procedural steps should be included in the computation of the scanning time.

The authors declare they have no conflict of interest regarding the publication of this paper.

## References

1. Brauner E, Valentini V, Jamshir S, et al. Retrospective review of 78 rehabilitated head and neck postoncological patients: a new classification method. *Minerva Stomatol.* 2016 Feb; 65(1):17-32

2. Brauner E, Pompa G, Quarato A, et al. Maxillofacial Prosthesis in Dentofacial Traumas: A Retrospective Clinical Study and Introduction of New Classification Method. *Biomed Res Int* 2017; 2017:8136878
3. Pagnoni M, Amodeo G, Fadda MT, et al. Juvenile idiopathic/rheumatoid arthritis and orthognatic surgery without mandibular osteotomies in the remittent phase. *J Craniofac Surg* 2013 Nov; 24(6):1940-5
4. De Angelis F, Papi P, Mencio F, et al. Implant survival and success rates in patients with risk factors: Results from a long-term retrospective study with a 10 to 18 years follow-up. *Eur Rev Med Pharmacol Sci* 2017; 21 (3):433-7
5. Mencio F, De Angelis F, Papi P, et al. A randomized clinical trial about presence of pathogenic microflora and risk of peri-implantitis: comparison of two different types of implant-abutment connections. *Eur Rev Med Pharmacol Sci* 2017; 21 (7):1443-51
6. Baroudi K, Ibraheem SN. Assessment of Chair-side Computer-Aided Design and Computer-Aided Manufacturing Restorations: A Review of the Literature. *J Int Oral Health*. Apr 2015; 7(4):96-104
7. Lee SJ, Macarthur RX IV, Gallucci GO. An evaluation of student and clinician perception of digital and conventional implant impressions. *J Prosthet Dent*. Nov 2013; 110(5):420-3
8. Ng J, Ruse D, Wyatt C. A comparison of the marginal fit of crowns fabricated with digital and conventional methods. *J Prosthet Dent*. Sep 2014; 112(3):555-60
9. Syrek A, Reich G, Ranftl D, et al. Clinical evaluation of all-ceramic crowns fabricated from intraoral digital impressions based on the principle of active wavefront sampling. *J Dent Jul* 2010; 38(7):553-9
10. Grasso JE, Nalbandian J, Sanford C, et al. Effect of restoration quality on periodontal health. *J Prosthet Dent* 1985; 53:14-9
11. Jacobs MS, Windeler AS. An investigation of dental luting cement solubility as a function of the marginal gap. *J Prosthet Dent* 1991; 65:436-42
12. Janenko C, Smales RJ. Anterior crowns and gingival health. *Aust Dent J* 1979; 24:225-30
13. Valentini V, Terenzi V, Cassoni A, et al. Giant cell lesion or langherans' cell histiocytosis of the mandible: a case report. *International journal of inflammation* 2012; 10(1):159-64
14. Pompa G, Saccucci M, Di Carlo G, et al. Survival of dental implants in patients with oral cancer treated by surgery and radiotherapy: a retrospective study. *BMC Oral Health* 2015; 20;15:5
15. Hack GD, Barns D, Depaola L. In vitro evaluation of the iTero digital impression system. *ADA Professional Product Review*. 2011; 6(2):6-10
16. Pompa G, Di Carlo S, De Angelis F et al. Comparison of Conventional Methods and Laser-Assisted Rapid Prototyping for Manufacturing Fixed Dental Prosthesis: An In Vitro Study. *Biomed Res Int*. Oct 2105; 2015:318097
17. Kim JH, Jeong JH, Lee JH et al. Fit of lithium disilicate crowns fabricated from conventional and digital impressions assessed with micro-CT. *J Prosthet Dent*. Oct. 2016; 116(4):551-7
18. Brauner E, Valentini V, Jamshir S, et al. Two clinical cases of prosthetical rehabilitation after a tumor of the upper maxilla. *European journal of medical and pharmacological sciences*. 2012; 16 (13): 1882-90
19. Brauner E, Jamshir S, Guarino G, et al. Pleomorphic adenoma rehabilitative treatment in growing up patient: a 20-years follow-up. *European Review for Medical and Pharmacological Sciences* 2016; 20:3523-7
20. Pompa G, Brauner E, Jamshir S, et al. Quality of life in patients rehabilitated with palatal obturator without reconstruction of maxillectomy defects. *Journal of international dental and Medical Research* 2017; 10(1):1-8
21. De Angelis F, Pignatiello G, Brauner E, et al. Accuracy and precision of an intraoral scanner in complex prosthetic rehabilitations: an in vitro study. *Journal of International Dental and Medical Research* 2017; 10 (1):1-7
22. Boeddinghaus M, Breloer ES, Rehmann P, et al. Accuracy of single-tooth restorations based on intraoral digital and conventional impressions in patients. *Clin Oral Investig* 2005; 19(8):2027-34
23. Abdel-Azim T, Rogers K, Elathamna E, et al. Comparison of the marginal fit of lithium disilicate crowns fabricated with CAD/CAM technology by using conventional impressions and two intraoral digital scanners. *J Prosthet Dent Oct*. 2015; 114(4):554-9
24. Lee JJ, Jeong ID, Park JY, et al. Accuracy of single-abutment digital cast obtained using intraoral and cast scanners. *J Prosthet Dent*. Sep. 2016; S0022-3913(16)30358-4
25. Rudolph H, Salmen H, Moldan M, et al. Accuracy of intraoral and extraoral digital data acquisition for dental restorations. *J Appl Oral Sci*. Jan-Feb 2016; 24(1):85-94
26. Güth JF, Runkel C, Beuer F, et al. Accuracy of five intraoral scanners compared to indirect digitalization. *Clin Oral Investig*. Jul. 2016; DOI: 10.1007/s00784-016-1902-4
27. Patzelt SB, Emmanouilidi A, Stampf S et al. Accuracy of full-arch scans using intraoral scanners. *Jul* 2014; 18(6):1687-94
28. Fasbinder DJ. Computerized technology for restorative dentistry. *Am J Dent*. 2013; 26(3):115-20
29. Zimmermann M, Mehl A, Mörmann W.H. and Reich S Intraoral scanning systems—a current overview. *International Journal of Computerized Dentistry* 2015; 18:101-29
30. Ting-Shu S. and Jian S. Intraoral digital impression technique: a review. *Journal of Prosthodontics* 2015; 24: 313-21
31. Todd JA, Oesterle LJ, Newman SM. et al. Dimensional changes of extended-pour alginate impression materials. *American Journal of Orthodontics and Dentofacial Orthopedics* 2013; 143 (suppl 4): S55-S63
32. Nassar U, Oko A, Adeeb S, et al. An in vitro study on the dimensional stability of a vinyl polyether silicone impression material over a prolonged storage period. *The Journal of Prosthetic Dentistry* 2013; 109:172-8
33. Grünheid T, McCarthy SD, Larson BE. Clinical use of a direct chairside oral scanner: an assessment of accuracy, time, and patient acceptance. *American Journal of Orthodontics and Dentofacial Orthopedics* 2014; 146:673-82
34. Flüge TV, Schlager S, Nelson K, et al. Precision of intraoral digital impressions with iTero and extraoral digitization with the iTero and a modelscanner. *American Journal of Orthodontics and Dentofacial Orthopedics* 2013; 144: 471-8
35. Naidu D, Freer TJ. Validity, reliability, and reproducibility of the iOC intraoral scanner: a comparison of tooth widths and Bolton ratios. *American Journal of Orthodontics and Dentofacial Orthopedics* 2013; 144:304-10
36. Wiranto MG, Engelbrecht WP, Tutein Nolthenius HE, et al. Validity, reliability, and reproducibility of linear measurements on digital models obtained from intraoral and cone-beam computed tomography scans of alginate impressions. *American Journal of Orthodontics and Dentofacial Orthopedics* 2013; 143:140-7