

# Hypophosphatasia: clinical manifestation and burden of disease in adult patients

Francesco Conti  
Lorenzo Ciullini  
Giuseppe Pugliese

Department of Clinical and Molecular Medicine, "Sapienza" University of Rome, "S. Andrea" Hospital, Diabetes Units, Rome, Italy

Address for correspondence:

Lorenzo Ciullini  
Department of Clinical and Molecular Medicine, "Sapienza" University of Rome, "S. Andrea" Hospital, Diabetes Unit, Rome, Italy  
E-mail: ciullini.lorenzo@gmail.com

## Summary

**Hypophosphatasia (HPP) is a rare inherited disease with a heterogeneous clinical expression. The adult form of HPP is often difficult to be recognized with a delayed diagnosis and inappropriate treatments. Though severity of HPP decreases with age at onset, important complications could occur at any age and the burden of HPP among adult patients is found to be significant. Adult patients with HPP suffer of chronic pain, recurrent fractures and other orthopedics problems, with severe disability that have a serious negative impact on all aspects of their life. The aim of this paper is to summarize the main aspects of HPP in adult patients reviewing the literature and focusing on its burden for patients suffering from this condition.**

*KEY WORDS:* hypophosphatasia; diagnosis; adult form; fractures; bone; alkaline phosphatase.

## Introduction

Hypophosphatasia (HPP) is a rare polymorphic disease that causes several debilitating effects primarily impacting bone. HPP results from loss-of-function mutations in the gene of the tissue-nonspecific isoenzyme of alkaline phosphatase (TNSALP). Clinical manifestations of HPP are extremely variable as a result of genetic features and age of appearance, ranging from life threatening to asymptomatic clinical presentations. Although the major severity of infants and childhood forms of HPP is a consolidated notion, it is currently widely established that the separation among different

forms of HPP is not well defined with clinical manifestations overlapping and that severe complications can occur at any age. Pointing out the burden of the disease for adult patients with HPP allows to underline the real impact of this condition in affected patients, the socio-economical consequence of HPP and might define future studies to better address the disease.

## Epidemiology of HPP

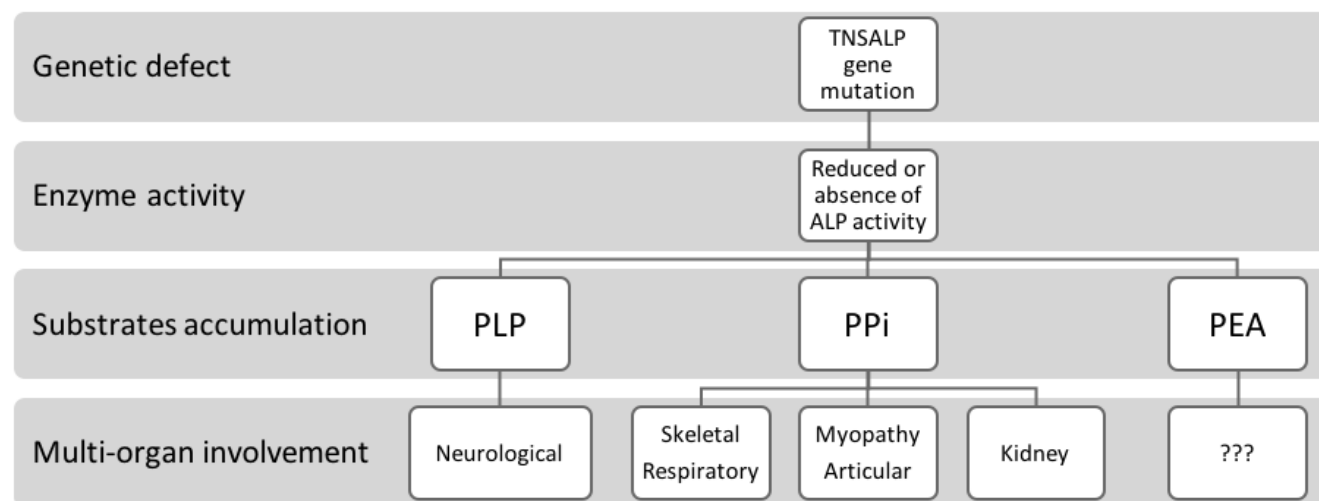
The exact prevalence of HPP is unknown and it depends from the form of HPP, population studied and the different methods used to determine it in the epidemiology studies. HPP prevalence in severe forms, perinatal and infantile, ranges from 1/100,000 (1) to 1/900,000 (2) and up to 1/2,500 in population with a founder effect identified (3). The prevalence of severe HPP in European population was estimated to be 1/300,000 (4). On the other hand, the prevalence estimate of milder forms of HPP, including adult form, is highly difficult to be determined due to the heterogeneity of clinical manifestations and the lower rate of diagnosis (5). There is few literature data on the prevalence of HPP mild forms, which are found to be more frequent than severe ones, with an estimated prevalence among European populations of about 1/6,370, according to the genetic model proposed by Mornet et al. (4).

## Etiology and pathogenesis

Alkaline phosphatase (ALP) is essential for skeletal mineralization: its main role is the liberation of inorganic phosphate (Pi) for hydroxyapatite (HA) crystal propagation (6). This enzyme is found to be abundant also in non-calcifying tissues (e.g., liver, intestine, placenta).

There are four ALP isoenzymes, encoded by four separate genes: three isoenzymes are tissue specific (intestinal, placental, and germ cell ALP) and the fourth is the tissue non-specific ALP (TNSALP), present in all cell types (7). Liver, bone, and kidney are especially rich in TNSALP, present in "secondary" isoenzymes (isoforms). The TNSALP gene is localized on the short arm of chromosome 1 (1p36.1–p34); up to date more than 300 mutations of TNSALP have been identified ([http://www.sesep.uvsq.fr/03\\_hypo\\_mutations.php](http://www.sesep.uvsq.fr/03_hypo_mutations.php)) leading to variable levels reduction of TNSALP activity. Loss or reduced function of ALP causes the increase of three phosphoric compounds: inorganic pyrophosphate (PPi), pyridoxal 5'-phosphate (PLP) and phosphoethanolamine (PEA). The extracellular accumulation of these phosphoric compounds, especially PPi, leads to the impairment of HA crystal formation and growth, thereby producing rickets and osteomalacia, respectively in children and adults, and a wide range of other symptoms (Tables 1, 2).

Table 1- Pathogenesis and multi-organ involvement of hypophosphatasia.



PLP: pyridoxal-5'-phosphate, PPI: inorganic pyrophosphate, PEA: phosphoethanolamine.

Table 2 - Clinical manifestations of hypophosphatasia.

Clinical manifestations	
<b>Neurological</b>	Seizures (Vit. B6 responsive) – craniosynostosis related symptoms
<b>Skeletal</b>	Defective mineralization, rickets, osteomalacia, bone deformity, multiple fractures, delayed bone healing
<b>Respiratory</b>	Severe respiratory insufficiency (related to chest deformities), respiratory complications
<b>Muscular</b>	Chronic muscle pain, reduced muscular strength and performance
<b>Articular</b>	Chondrocalcinosis, ectopic calcification of ligaments (enthesopathy), pseudogout attacks
<b>Renal</b>	Hyperphosphatemia, hypercalciuria, nephrocalcinosis
<b>Dental</b>	Premature loss of decidual and permanent teeth, with tooth root intact, caused by deficiency of mineralized cementum

### Nosology and classification

HPP has an extraordinarily wide-ranging expressivity: prognosis is determined by age at diagnosis, inversely related to the disease outcome, and by severity of skeletal complications (8-12). Six clinical forms are identified, though this classification does not unambiguously identify all clinical forms of HPP and there is not a large consensus on the nosology of HPP (13): perinatal, prenatal benign (with spontaneous improvement of skeletal defects despite prenatal signs of disease), infantile, juvenile, adult form and odontohypophosphatasia (Table 3). The perinatal one is the most severe form of HPP with marked skeletal hypomineralization already evident *in utero* and death occurring at birth or soon after. HPP forms affecting infants and children are generally criti-

cal forms: the main clinical features are consequences of defective bone and teeth mineralization and include rickets, osteomalacia, fractures, teeth loss, systemic manifestations (i.e. respiratory complications, seizures, nephrocalcinosis, muscle weakness, chronic pain) (14). Odontohypophosphatasia is a particular form of HPP diagnosed among patients of any age with only dental manifestations and no evidence of skeletal abnormalities (5).

### Clinical presentation of HPP adult form

The symptoms of adult form of HPP present great variability as underlined by a retrospective study of Berkseth et al. (15). This form is typically diagnosed after middle age (5). The

Table 3 - Clinical manifestations in principal forms of hypophosphatasia according to age of onset.

Clinical form (age at onset)	Perinatal (birth – 4 weeks)	Infantile (before 6 months)	Juvenile (before 18 yrs)	Adult (after 18 yrs)
Clinical signs and symptoms	✓ defective skeletal mineralization	✓ craniosynostosis	✓ chronic muscle pain	✓ chronic bone / muscle pain
	✓ chest deformities	✓ delayed growth	✓ myopathy	✓ recurrent fractures / pseudofractures
	✓ severe respiratory insufficiency	✓ fractures	✓ defective skeletal mineralization	✓ delayed bone healing
	✓ respiratory complications	✓ hypercalcemia	✓ recurrent fractures	✓ osteomalacia
	✓ seizures (Vit. B6 responsive)	✓ hypercalciuria	✓ rickets	✓ arthropathy w/wo chondrocalcinosis
	✓ fractures	✓ nephrocalcinosis	✓ low stature	✓ enthesopathy
	✓ deformities of long bones	✓ rickets	✓ bone deformities	✓ altered gait
	✓ death	✓ respiratory insufficiency	✓ delayed bone healing	✓ early loss of teeth
		✓ fractures	✓ early loss of teeth	
		✓ seizures (Vit. B6 responsive)		
	✓ death	✓ early loss of decidual teeth		

typical presenting symptoms at onset are pain caused by recurrent metatarsal stress fractures, due to the osteomalacia, with delayed or incomplete healing. With more advanced disease, femoral pseudofractures might occur (typically bilateral, in the lateral or medial subtrochanteric diaphysis) with poor healing that causes severe aching and tenderness in the thighs. Patients may also complain of chronic muscle pain, reduced muscular strength and performance related to myopathy, bone pain without fractures. Refractory pain of the extremities can also be a presenting sign. Some individuals suffer from chondrocalcinosis, ectopic calcification of ligaments and pseudo-gout attacks due to calcium PPI dihydrate deposition (16). Hyperphosphatemia, hypercalciuria may be present as well. Adult HPP causes recurrent, persistent and disabling orthopedic problems. Kidney disorders including nephrocalcinosis and premature loss of permanent teeth are other possible features of this HPP form (5, 9, 14, 15).

### Diagnosis

HPP is diagnosed starting from the medical history, physical examination, laboratory findings and imaging, with the use of genetic analysis for the TNSALP gene mutations in the controversial cases (8-10, 17). It is not rare that adult patients are asymptomatic: in this cases the diagnosis of HPP is made by chance, following distinctive laboratory findings as low plasma level of ALP and elevated levels of substrates (PLP, PPI, PEA). Since the clinical features of mild HPP forms have a less evident and sometimes nonspecific clinical presentation, the diagnosis of these subtypes of HPP is very difficult.

### Adult patients with HPP

HPP presents a wide spectrum of clinical manifestation in adults. The female sex is prevalent (15, 18). Adult patients affected by HPP can both report pediatric or adult onset of the disease. According to the results of a recent patient-reported survey conducted by Weber et al., the majority of

adult patients with HPP reported a pediatric onset of the symptoms; moreover, half of the patients with adult onset reported symptoms suspicious for or surgeries suggestive of pediatric onset of HPP (Table 4) (18). Other studies reported that between 9 and 50% (15, 19) of adult patients with HPP recall earlier symptoms of the disease (as the history of mild rickets and/or early deciduous teeth loss) (10, 15). Based on these considerations the overall proportion of patients with putative adult form of HPP, reports pediatric symptoms. These findings underline the importance of a greater physicians and patients' awareness to promote early and accurate diagnosis of HPP. The early and correct identification of HPP is crucial in order to avoid misdiagnosis and inappropriate treatments (like high doses of vitamin D and calcium supplementation or bisphosphonates) that may exacerbate symptoms and complication of HPP and delay the initiation of the proper treatment. Since a substantial proportion of HPP adult forms could be pediatric/juvenile forms that are diagnosed later, it is possible to state that HPP subtypes might be considered as a continuous and wide spectrum of a single disease which symptoms and complications can occur at any age.

### Management and treatment of adult patients with HPP

Until recently, no specific medical treatment for any form of HPP has been available, medical and surgical interventions were aimed to alleviate symptoms and reduce complications. Different therapeutic approaches have been attempted in the past, with transient and inconsistent results (20). Teriparatide (parathyroid hormone amino acid 1-34) administration has been successfully used to improve fracture healing and resolve stress fractures in some HPP affected adults. This PTH analog stimulates the synthesis of ALP in osteoblast, bringing in some cases to normalize the circulating ALP levels (21-23). However, concerns about the bone effects of long term use of this peptide, has limited its use (21). Enzyme replacement therapy with a recombinant, bone targeted, human enzyme (asfotase alfa) is a novel, specific and promising treatment in patients affected by HPP. It has al-

Table 4 - Burden of disease in adult patients with hypophosphatasia (% of total patients, n=125) (18).

Patients characteristics	Clinical manifestations	Fractures sustained over lifetime	Quality of life (QoL) and disability
✓ Female prevalence	✓ 96% chronic pain <ul style="list-style-type: none"> <li>• 82% bone</li> <li>• 73% joints</li> <li>• 53% muscles</li> </ul>	✓ 90%: at least one fracture	✓ health-related QoL lower than general population on all components and domains
✓ Majority of pediatric (<18yrs) onset		✓ 22%: 6-10 fractures	✓ 1/3 of the patients require a device to ambulate
✓ 50% of patients with adult onset report symptoms or surgery suggestive of pediatric onset of HPP	✓ 62% daily use of analgesic drugs	✓ 26%: more than 10 fractures	✓ 1/4 of the patients use a wheelchair ✓ 3/4 of the patients had required surgery in the past

ready been shown safe and effective in the perinatal and infantile forms of HPP (24-27) and it is now in the clinical developing phase in adult patients affected by HPP (14, 28). Though the full beneficial impact of enzyme replacement treatment might be limited by delayed diagnosis, often seen in the adult form of HPP, and the consequent late treatment's initiation, this new therapy might represent an effective option to be considered for severe adult forms of HPP.

#### The burden of disease in adult patients with HPP

The patient-reported survey conducted by Weber et al. among adult patients with HPP (18), revealed the perception of a high burden of symptoms related to HPP and a diminished quality of life (QoL) (Table 4). The overall fracture prevalence was found to be very high in this survey: almost half of the study population sustained between 6 and more than 10 fractures over lifetime. The high frequency of fractures among adult patients with HPP was also reported in other studies (15). HPP had a great negative impact in the life of the interviewed patients: almost the totality of adult patients reported chronic pain (at bone, joints and muscles) and a large majority needed daily use of analgesic drugs; this finding was confirmed in other studies (15). The QoL evaluated at different domains and grade of disability, assessed by several instruments, resulted significantly lower than general population mean, reflecting a great deterioration of almost all everyday activities. The rate of mobility impairment resulted higher than normal population with a very high frequency of assistive devices for mobility or home assistance required. The surgical burden was also found to be very high in adult patients affected by HPP, with almost three-quarters of patients requiring surgeries, a very important aspect to be considered, taking into account the high rate of failure and complications of implant surgeries in adult patients with HPP due to impaired ossification process. The course of HPP in adults and its high burden was not dependent on the age of symptoms onset (pediatric or adult), although an overall trend to develop most severe consequences and higher burden (greater duration of symptomatic disease, increased number of fractures and disability) has been observed among adult patients with pediatric onset of HPP. Further studies should better address this issue to de-

termine differences of real and perceived burden of HPP in adults depending from the duration of disease, distinguishing adult and pediatric onset. Though it was well recognized that the greatest burden of HPP is physical, several studies underline that psychiatric sphere was also affected by this disease: mental and emotional health domains resulted impacted in adult patients with HPP (18) and a psychiatric involvement with symptoms of depression and anxiety more severe than in a normal reaction to disease has also been reported (9), as a probable consequence of low levels of ALP in central nervous system. Based on the reported considerations, the social costs of HPP in adults, though not deeply studied and assessed up to date, could be estimated as very high. The high disability rate, diminished QoL, needs of assistive mobility devices, restrictions in daily living and working activities as well as continuous healthcare assistance of adult population affected by HPP, requires high economic and logistic resources. Further researches are needed to better assess the personal and social costs of HPP in adult population.

#### Conclusions

In conclusion, HPP is a multi-systemic disease with deleterious effects which can appear at different ages and progress over time. In adults, the symptoms of HPP are often misdiagnosed and confused for other more common bone or rheumatologic diseases leading to delayed diagnosis and inappropriate treatment, like high-dose vitamin D, excessive calcium supplementation and bisphosphonates that could be ineffective or even worsen the symptoms. A crescent awareness on the complexity and clinical features variability of HPP presentation in adult patients should be encouraged. Adult patients affected by this disease can suffer severe conditions and the high burden of HPP is widely recognized both from patients' side and society costs. A better comprehension of adult forms of HPP is very important to reduce the delay of diagnosis and to recognize all the affected subjects. In order to reduce the burden of the disease in HPP patients, it is mostly important to increase the understanding of possible therapeutic strategies, pointing out indications, dosing, efficacy and limits of different treatments like enzyme replacement therapy and bone anabolic agents.

## References

- Fraser D. Hypophosphatasia. *Am J Med.* 1957;22(5):730-746.
- Watanabe A, Karasugi T, Sawai H, Naing BT, Ikegawa S, Orimo H, Shimada T. Prevalence of c.1559delT in ALPL, a common mutation resulting in the perinatal (lethal) form of hypophosphatasia in Japanese and effects of the mutation on heterozygous carriers. *J Hum Genet.* 2011;56(2):166-168. doi: 10.1038/jhg.2010.2161.
- Rockman-Greenberg C. Hypophosphatasia. *Pediatr Endocrinol Rev.* 2013;10 Suppl 2:380-388.
- Mornet E, Yvard A, Taillandier A, Fauvert D, Simon-Bouy B. A Molecular-Based Estimation of the Prevalence of Hypophosphatasia in the European Population. *Ann Hum Genet.* 2011;75(3):439-445. doi: 10.1111/j.1469-1809.2011.00642.x.
- Bianchi ML. Hypophosphatasia: an overview of the disease and its treatment. Vol. 26, *Osteoporosis International.* 2015;26(12):2743-2757. doi: 10.1007/s00198-015-3272-1.
- Robison R. The significance of phosphoric esters in metabolism. *J Soc Chem Ind.* 1932.
- Millan JL. *Mammalian Alkaline Phosphatases: From Biology to Applications in Medicine and Biotechnology.* Wiley-VCH, 2006.
- Cole DE. Hypophosphatasia update: recent advances in diagnosis and treatment. *Clin Genet.* 2008;73(3):232-235. doi: 10.1111/j.1399-0004.2007.00958.x.
- Hofmann C, Girschick HJ, Mentrup B, Graser S, Seefried L, Liese J, et al. Clinical aspects of hypophosphatasia: An update. *Clin Rev Bone Miner Metab.* 2013;11(2):60-70.
- Mornet E. Hypophosphatasia. *Best Pract Res Clin Rheumatol.* 2008;22(1):113-127. doi: 10.1016/j.berh.2007.11.003.
- Whyte MP, Zhang F, Wenkert D, McAlister WH, Mack KE, Benigno MC, Coburn SP, Wagay S, Griffin DM, Ericson KL, Mumm S. Hypophosphatasia: validation and expansion of the clinical nosology for children from 25 years experience with 173 pediatric patients. *Bone.* 2015; 75:229-239. doi: 10.1016/j.bone.2015.02.022.
- Fallon MD, Teitelbaum SL, Weinstein RS, Goldfischer S, Brown DM, Whyte MP. Hypophosphatasia: clinicopathologic comparison of the infantile, childhood, and adult forms. *Medicine (Baltimore).* 1984;63(1):12-24.
- Whyte MP. Hypophosphatasia. *Nature's Window on Alkaline Phosphatase Function in Humans. Principles of Bone Biology.* 2008:1573-98.
- Whyte MP. Hypophosphatasia - aetiology, nosology, pathogenesis, diagnosis and treatment. *Nat Rev Endocrinol.* 2016;12(4):233-246. doi: 10.1038/nrendo.2016.14.
- Berkseth KE, Tebben PJ, Drake MT, Hefferan TE, Jewison DE, Wermers RA. Clinical spectrum of hypophosphatasia diagnosed in adults. *Bone.* 2013;54(1):21-27. doi: 10.1016/j.bone.2013.01.024.
- Beck C, Morbach H, Stenzel M, Schneider P, Collmann H, Girschick G, Girschick HJ. Hypophosphatasia. *Klin Padiatr.* 2009;221(4):219-226. doi: 10.1055/s-0029-1220718.
- Whyte MP. Physiological role of alkaline phosphatase explored in hypophosphatasia. *Ann N Y Acad Sci.* 2010;1192:190-200. doi: 10.1111/j.1749-6632.2010.05387.x.
- Weber TJ, Sawyer EK, Moseley S, Odrijin T, Kishnani PS. Burden of disease in adult patients with hypophosphatasia: Results from two patient-reported surveys. *Metabolism.* 2016;65(10):1522-1530. doi: 10.1016/j.metabol.2016.07.006.
- Caswell AM, Whyte MP, Russell RG. Hypophosphatasia and the extracellular metabolism of inorganic pyrophosphate: clinical and laboratory aspects. *Crit Rev Clin Lab Sci.* 1991;28(3):175-232.
- Orimo H. Pathophysiology of hypophosphatasia and the potential role of asfotase alfa. *Ther Clin Risk Manag.* 2016;12:7777-7786. doi: 10.2147/TCRM.S87956.
- Whyte MP, Mumm S, Deal C. Adult hypophosphatasia treated with teriparatide. *J Clin Endocrinol Metab.* 2007;92(4):1203-1208.
- Camacho PM, Painter S, Kadanoff R. Treatment of adult hypophosphatasia with teriparatide. *Endocr Pract.* 2008;14(2):204-208.
- Schalin-Jääntti C, Mornet E, Lamminen A, Välimäki MJ. Parathyroid hormone treatment improves pain and fracture healing in adult hypophosphatasia. *J Clin Endocrinol Metab.* 2010;95(12):5174-5179. doi: 10.1210/jc.2010-1168.
- Millán JL, Whyte MP. Alkaline Phosphatase and Hypophosphatasia. *Calcif Tissue Int.* 2016;98(4):398-416. doi: 10.1007/s00223-015-0079-1.
- Whyte MP, Greenberg CR, Salman NJ, Bober MB, McAlister WH, Wenkert D, Van Sickle BJ, Simmons JH, Edgar TS, Bauer ML, Hamdan MA, Bishop N, Lutz RE, McGinn M, Craig S, Moore JN, Taylor JW, Cleveland RH, Cranley WR, Lim R, Thacher TD, Mayhew JE, Downs M, Millán JL, Skrinar AM, Crine P, Landy H. Enzyme-replacement therapy in life-threatening hypophosphatasia. *N Engl J Med.* 2012;366(10):904-913. doi:10.1056/NEJMoa1106173.
- Whyte MP, Rockman-Greenberg C, Ozono K, Riese R, Moseley S, Melian A, Thompson DD, Bishop N, Hofmann C. Asfotase Alfa Treatment Improves Survival for Perinatal and Infantile Hypophosphatasia. *J Clin Endocrinol Metab.* 2016;101(1):334-42. doi: 10.1210/jc.2015-3462.
- McKee MD, Nakano Y, Masica DL, Gray JJ, Lemire I, Heft R, Whyte MP, Crine P, Millán JL. Enzyme replacement therapy prevents dental defects in a model of hypophosphatasia. *J Dent Res.* 2011;90(4):470-476. doi: 10.1177/0022034510393517.
- Whyte MP, Kishnani PS, Greenberg CR, Madson K, Mack K, Weber T, Mhanni A, Plotkin H, Kreher N, Landy H. Hypophosphatasia: enzyme replacement therapy (asfotase alfa) decreases TNSALP substrate accumulation and improves functional outcomes in affected adolescents and adults. *Bull Group Int Rech Sci Stomatol Odontol.* 2012;51:35.